

## Support and Information



### Rare Chromosome Disorder Support Group,

The Stables, Station Road West, Oxted, Surrey RH8 9EE, United Kingdom  
Tel +44(0)1883 723356  
info@rarechromo.org | www.rarechromo.org

Unique is a charity without government funding, existing entirely on donations and grants. If you are able to support our work in any way, however small, please make a donation via our website at [www.rarechromo.org/html/MakingADonation.asp](http://www.rarechromo.org/html/MakingADonation.asp)  
Please help us to help you!

### The Chromosome 18 Research & Registry Society

7155 Oakridge Drive, San Antonio, Texas 78229, USA  
[www.chromosome18.org](http://www.chromosome18.org)

This guide was made possible by contributions from: Fonds NutsOhra, Erfocentrum, VGnetwerken and VKGN in the Netherlands.



Unique mentions other organisations' message boards and websites to help families looking for information. This does not imply that we endorse their content or have any responsibility for it. This guide is not a substitute for personal medical advice. Families should consult a medically qualified clinician in all matters relating to genetic diagnosis, management and health. The information is believed to be the best available at the time of publication. The information was compiled by Dr Laura van Dussen, MD, Erfocentrum, Netherlands and reviewed by Prof Dr C. van Ravenswaaij-Arts (UMC Groningen) and Mieke van Leeuwen (VGnetwerken). With special thanks to Annet van Betuw (VanBetuwAdvies), Marja de Kinderen (PROK Project management and training) Joyce Schaper (Chromosome Foundation) and Sarah Wynn, BSc(Hons) PhD DIC (Unique).

Version 1 (LD) 2015

Copyright © Unique 2016

Rare Chromosome Disorder Support Group  
Registered in England and Wales

Charity Number 1110661 Reg-  
Company Number 5460413



# Isochromosome 18p



rarechromo.org

## Isochromosome 18p

Isochromosome 18p is a rare genetic condition. People with this condition usually have a small extra chromosome made up of two copies of part of chromosome 18.

For healthy development, chromosomes should contain just the right amount of genetic material – not too much and not too little. Isochromosome 18p causes developmental delay/intellectual disability and can result in several other health issues.

## What are chromosomes?

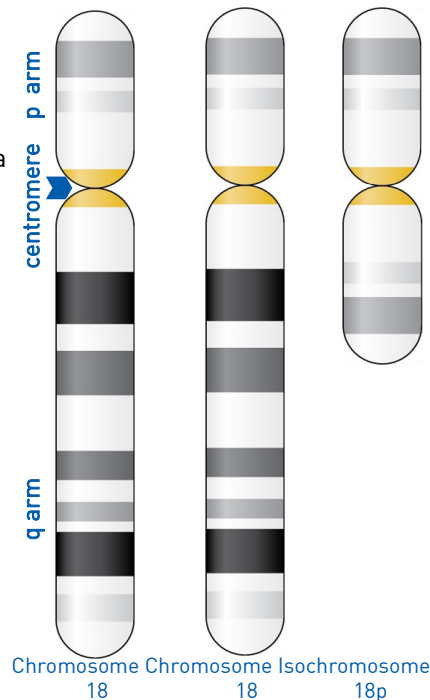
Chromosomes are made up mostly of DNA and are the structures in each of the body's cells that carry the genetic information (in the form of genes) that tells the body how to develop, grow and function. Chromosomes usually come in pairs, with one chromosome from each pair coming from the father and one from the mother.

Of the 46 chromosomes, two are a pair of sex chromosomes, XX (two X chromosomes) in females and XY (one X and one Y chromosome) in males. The remaining 44 chromosomes are grouped in 22 pairs, numbered 1 to 22 from largest to smallest.

Chromosomes have a short arm, named p (shown at the top in the figure), and a long arm, named q (shown at the bottom in the figure). The two arms of a chromosome meet at a point called the centromere.

## Looking at isochromosome 18p

You can't see chromosomes with the naked eye, but if you stain them and magnify them many hundreds of times under a microscope, you can see that each one has a distinctive pattern of light and dark bands. If we look at the chromosomes of someone with isochromosome 18p, we can see that there is a small, extra chromosome present as well as the regular 46 chromosomes. If we study this extra chromosome in detail, we can observe that it contains the material of the short arm (p) of chromosome 18, twice. People with isochromosome 18p therefore have four copies of the genetic material of the short arm of chromosome 18: twice as part of their regular chromosome 18 and twice on the isochromosome. Isochromosome 18p is sometimes referred to as tetrasomy 18p (tetra means 4) because of this.



## Appendix

### Results of the chromosome test

In case of isochromosome 18p, the result is likely to read something like this:

**47, XY, i(18)(p10)**

This means:

- 47** 47 chromosomes are present, instead of the normal number of 46
- XY** The two sex chromosomes, XY in men, XX in women
- i(18)** The extra chromosome is an isochromosome. An isochromosome is a chromosome that consists of two copies of the same arm of the chromosome. The isochromosome in this case consists of material from chromosome 18.
- (p10)** The isochromosome consists of material from the short arm (p) of chromosome 18. The number 10 indicates the band after which the material is present twice. In this case it means the entire short arm.

Two mothers of a child with isochromosome 18p were found to carry a chromosomal rearrangement that involved chromosome 18 (a translocation). The mothers had no symptoms or features of the rearrangement. One of the mothers was short (Taylor 1975; Takeda 1989).

Another article describes a mother who had an isochromosome 18p in some of the cells of her body. This is called mosaicism. The mother had some characteristics in her appearance, but had no other signs or symptoms of isochromosome 18p (Abeliovich 1993).

Rarely, chromosome results in both parents are normal, but an isochromosome 18p is present in some of the egg cells or sperm cells. This is called germline mosaicism.

It means that parents who are not found to carry the change still have a very small chance of having another affected child. This has been described once in the medical literature in isochromosome 18p. Two half-sisters from the same mother had an isochromosome 18p. Their mother had normal chromosomes. Most likely, the isochromosome 18p is present in some of the egg cells of the mother, but not (or hardly) in any other cells making it impossible to detect by testing (Boyle 2001).

It is important that both parents of a child with the isochromosome have their own chromosomes tested. Whether or not the change occurred de novo or was the result of a translocation there is nothing you can do to have stopped this. No one is to blame and nobody is at fault.

### Can it happen again?

The risk of having another child affected by a rare chromosome disorder depends on the genetic code of the parent. If the chromosomes in both parents are normal, the chance of having another child affected is very low.

Nonetheless, because of the risk of germline mosaicism (as explained above) there is a very small chance of having another affected child.

The chance of recurrence is much higher if one of the parents is found to carry the isochromosome or a chromosomal rearrangement that involves chromosome 18. Each family situation is different and a clinical geneticist can give you specific advice on the chance of recurrence in your family and options for prenatal diagnosis and, if wanted, preimplantation genetic diagnosis. PGD requires the use of in vitro fertilisation and embryo biopsy, and only healthy embryos are transferred to the mother's uterus. If the parents choose to conceive naturally, prenatal diagnosis options include chorionic villus sampling (CVS) and amniocentesis to test the baby's chromosomes.

### Learning about isochromosome 18p

The first child with isochromosome 18p was reported in the medical literature in 1963 (Froling 1963). A comparison of features in 11 children with an isochromosome 18p in 1983 showed that they shared several characteristics. As of 2015 more than 130 individuals with an isochromosome 18p have been reported in the medical literature.

This does not mean that there are no more children with isochromosome 18p. There are children registered in international databases, but often with more limited information reported. There are also children with isochromosome 18p who have never been included in medical articles.

### Main features in children with isochromosome 18p

The features mentioned in this guide have been described in the medical literature in children with isochromosome 18p. It is not known if all the features are indeed caused by the isochromosome or if their occurrence in children with the isochromosome is coincidental. Some of the features can also occur in children without the isochromosome.

Because only a few people with isochromosome 18p have been described, not all the effects of the extra material from chromosome 18 are known. The features can vary between children, but one or more of the following features can be present:

- Developmental delay and/or intellectual disability
- Feeding difficulties, delay in growth and a small head circumference (microcephaly)
- Low or high muscle tone (hypotonia or hypertonia/spasticity)
- Abnormal curvature of the spine (scoliosis or kyphosis)
- Strabismus (a squint)

### Sources

The information in this guide is drawn from the published medical literature: Froling 1963; Balicek 1976; Cote 1979; Rivera 1984; Kuleshov 1985; Borrego 1988; Yoshihara 1988; Takeda 1989; Callen 1990; Fryns 1990; Singer 1990; Park 1991; Blennow 1991; Mewar 1993; Yu 1993; Abeliovich 1993; Back 1994; Esmer 1994; Nakashima 1995; Bugge 1996; Darnaude 1996; Esmer 1996; Kotzot 1996; Eggerman 1996; Engelen 1996; Bugge 1996; Eggerman 1997; Eggerman 2000; Boyle 2001; Williams 2001; Irwin 2003; DeBerardinis 2005; Kolialexi 2006; Ramegowda 2006; Swingle 2006; Bakshii 2006; Balkan 2009; Brambila 2010; Dundat 2010; Nucaro 2010; Sebold 2010; White 2010; Plaiasu 2011; Schwemmler 2012; Jung 2013; Wei 2014; O'Donnell 2015; Soileau 2015. With the first-named author and publication date you can look for abstracts or original articles on the internet in PubMed ([www.ncbi.nlm.nih.gov/pubmed](http://www.ncbi.nlm.nih.gov/pubmed)). Most articles are available through Unique. When this guide was written the full text of the articles was used as far as possible, but sometimes only the abstracts were available. Also in this guide are included quotations from some Dutch parents who have a child with isochromosome 18p and filled out a questionnaire.

## How common is isochromosome 18p?

Isochromosome 18p is estimated to occur in 1 in 140,000 to 180,000 newborn babies (Ramegowda 2006; chromosome18.org; www.orpha.net).

## Outlook

People with the isochromosome without major physical malformations or problems are likely to have a normal life expectancy. A number of adults with isochromosome 18p have been described in the medical literature. Three children with isochromosome 18p have been described in the medical literature who died at a young age (DeBerardinis 2006; Sebold 2010). One article described a girl who was stillborn (Takeda 1989).

## Pregnancy

Most mothers of a child with isochromosome 18p had a normal, uneventful pregnancy. Delivery was normal and they only discovered their baby was affected after birth.

In a few babies, the diagnosis was made before birth (Yu 1993; Darnaude 1996; Irwin 2003; Jung 2013). In one mother the diagnosis was made after an amniocentesis because of advanced maternal age (Irwin 2003). In one boy the diagnosis was made after several abnormalities were seen on ultrasound examinations. He had a possible heart condition, an imperforate anus and growth retardation (Jung 2013). After birth he was shown to have a slightly enlarged heart muscle. He was anaemic and received a transfusion after which the thickness of the heart muscle returned to normal.

## Newborns

Overall birth weight appears to be somewhat reduced in children with isochromosome 18p. A study in 2010 of 42 children reported an average birth weight of 2.842 kilos. Birth weights reported in the medical literature range from 2.000 kilos (Ramegowda 2006) to 4.140 kilos (Schwemmler 2006).

A substantial number of children with isochromosome 18p had feeding difficulties (see below). More than half of the children had jaundice which required phototherapy and close to a third of the children had breathing difficulties (Sebold 2010).

## Growth and feeding

One study reported feeding difficulties in 83% (83 out of 100) children with isochromosome 18p. Hypotonia, a high palate and gastro-esophageal reflux (GERD) were causes for the feeding problems (Sebold 2010). In GERD the contents from the stomach travel back up into the oesophagus (food passage).

“ When he was 3 months old, he refused expressed milk in a bottle. He was breastfed until he was 18 months old. When he was 5 months old he was fed by tube feeding. At the age of 9 months he got a gastrostomy tube. Nowadays he is still fed by tube. ”

Three children had conductive hearing loss while 3 had sensorineural hearing loss. Four children had a mix of types of hearing loss, and in one child the type of hearing loss was unclear (Boyle 2001; Schwemmler 2006; Sebold 2010; Jung 2013).

One article described a boy in whom hearing aids were helpful in the treatment of his hearing loss (Schwemmler 2006).

In addition to these problems, more than 50% of the children have frequent ear infections that can require ear tube surgery (Sebold 2010).

## Other

Some children have anomalies of the kidneys and/or urinary tract. Three out of 31 children in one study had horseshoe kidneys on an abdominal ultrasound. One child had diverticula of the bladder (in which pouches form in the wall of the bladder) (Sebold 2010). In another child the kidney was abnormally placed (malrotation). Yet another had a double duct between the kidney and bladder (Batista 1983). One child had small kidneys (Boyle 2001).

Several people have been described as having low IgA antibody levels (important in our immune system) (Batista 1983). Another study described 2 children with growth hormone deficiency (Sebold 2010). A boy with isochromosome 18p was born without a thymus gland (an organ involved in our immune system) (DeBerardinis 2006). One child had a pilonidal cyst (a cyst near the cleft of the buttocks) (Schwingle 2006).

## If one person in a family with isochromosome 18p is mildly affected, will others in the same family also be mildly affected?

It is difficult to answer this question as there are only a few families in which multiple family members carry the isochromosome (Takeda 1989; Boyle 2001).

## Why did it happen?

When children are conceived the genetic material is copied in the egg and sperm that makes a new child. The biological copying method is not perfect and occasionally random rare changes occur in the genetic code of children that are not seen in the DNA of their parents. The term doctors use for this is de novo. This happens naturally and is not due to your lifestyle or anything you did to cause a change. Most parents of children with an isochromosome 18p have normal chromosomes. Studies have shown that the de novo mutation most often occurs in the egg and sometimes the sperm (Bugge 1996; Eggerman 1996; Eggerman 1997). There are studies that suggest that advanced maternal age increases the risk of a child with isochromosome 18p, but further studies are necessary to confirm this finding (Connor 1990; Sebold 2010).

“ He has had surgery on his ears to insert ear tubes, to remove his adenoids and several times to have his auditory canal cleaned (one time because of a cholesteatoma). ” – 11 years

Four children reported in the medical literature had pyloric stenosis in which the passage from the stomach to the intestines is narrowed (Sebold 2010). One child had an umbilical hernia (Sebold 2010). Another child had an imperforate anus (Jung 2013) and in another child the anus was abnormally placed (DeBernardinis 2006).

### ■ Genitals

Minor anomalies of the genitals are common in babies with chromosome disorders, most often affecting boys. In approximately half of the boys with isochromosome 18p the testes have not descended (cryptorchidism). One study reported undescended testes in 12 out of 19 boys. Six of these boys had surgery (Sebold 2010).

The following anomalies have also been reported: shawl scrotum (in which the testes surround the penis), small testis, a small penis (micropenis) and hypospadias (Nucaro 2010; Sebold 2010). Some children reported in the literature had an inguinal hernia (Schwingle 2006; Sebold 2010).

No genital abnormalities have been reported in girls with an isochromosome 18p.

### ■ Vision

Approximately 35-45% (35 to 45 in 100) of the children with isochromosome 18p have strabismus (a squint) (Sebold 2010; White 2010). A follow-up study of the previously mentioned American study focused primarily on eye problems in children with isochromosome 18p. This study shows that 18 out of 25 children who had extensive eye examinations had strabismus. This percentage is higher than in the literature. The group studied in this article may therefore not be entirely representative of children with isochromosome 18p. Two children had amblyopia (a lazy eye). Most children had refractive errors. Long sight was more common than short sight. Three children had severe refractive errors (>-5 /+5 dioptres). Ten children had an astigmatism. One child had a blockage of the tear ducts. Another child had an underdeveloped iris (Sebold 2010; White 2010). In the remaining medical literature one other person is reported with a retinal coloboma (Schwingle 2006).

### ■ Hearing

Some children with isochromosome 18p have narrow ear canals (Schwemmle 2006; Sebold 2010). Twelve children reported in the medical literature have hearing problems. Both conductive and sensorineural hearing loss have been described. In conductive hearing loss, sound is not conducted properly from the middle ear to the inner ear. In sensorineural hearing loss the inner ear or hearing nerves do not function properly. Sensorineural hearing loss is permanent and is usually treated with hearing aids or cochlear implants. Conductive hearing loss is usually the result of fluid in the middle ear and is mostly temporary. Sometimes ear tube surgery is recommended.

Hypotonia can lead to difficulties in sucking and swallowing, but can also contribute to GERD. A high palate can also contribute to feeding difficulties. Fewer than 5% (5 in 100) children with isochromosome 18p have a cleft lip and/or palate (split) (Sebold 2010).

In approximately one fifth to one third of children with isochromosome 18p growth is delayed (Sebold 2010).

### Appearance

A number of facial features have been reported to occur more frequently in children with isochromosome 18p (Batista 1983; Callen 1990; Sebold 2010). Nonetheless children also look like their parents and siblings.

Many children with isochromosome 18p have a small head circumference (microcephaly). Low set ears that are posteriorly rotated are also common and ears may be abnormally shaped. Some children have a small mouth.

Other features that are reported in some of the articles are: a prominent, pointy chin, prognathism (a lower jaw that juts forward), a small lower jaw, short palpebral fissures (eye slits), epicanthal folds, an asymmetrical face, a low hairline, a prominent forehead, a pointed, small nose with a long or short nasal septum (division between nostrils), a long or smooth philtrum (groove from nose to upper lip) and high arched eyebrows.

### Sitting, moving and walking

Children with isochromosome 18p usually show delay in reaching their motor milestones. The delay can be mild to severe. The mean age at which 31 babies reported in the medical literature learned to roll over was 8 months.

Thirty-four children who learned to sit independently could do this at a mean age of 16 months. Twenty-nine children learned to crawl. They did this at a mean age of 22 months. Thirty-three children who were able to walk independently could do this at a mean age of 33 months (Sebold 2010). A number of reasons are given for the delay in motor development. Children often have abnormal muscle tone. Some children show hypotonia, while others suffer from a high muscle tone (spasticity). In some children muscle tone differs over time while in others it differs for different parts of the body (Sebold 2010).

### Speech and communication

Children with isochromosome 18p often show delay in the development of speech and language.

Twenty-eight out of 42 children with isochromosome 18p could speak single words at a mean age of 28 months. Nineteen children could speak short sentences of 2-3 words. They were able to do so at a mean age of 5½ years (Sebold 2010).

“ The biggest issues are throwing up, reflux and feeding problems. Also our child often has constipation.”  
11 years



## Learning

All children with isochromosome 18p reported in the medical literature have a degree of intellectual disability. Their intellectual disability can be mild to severe.

A study among 46 people revealed the following findings concerning intellectual development. Thirty of the 46 were extensively tested. Twelve out of 30 children (40%) show mild intellectual disability. Eleven children (37%) had moderate intellectual disability and 7 (23%) had severe intellectual disability. Mean IQ in 30 children was 48 (moderate intellectual disability)(O'Donnell 2015). Children often had difficulties organising and planning tasks. These difficulties can provide an extra challenge for children with mild intellectual disability. Occupational therapy can be helpful.

## Behaviour

Children with isochromosome 18p can be prone to frustration, like other children with difficulties in speech and communication. They may have difficulties concerning their social skills. Some children have behavioural problems such as hyperactive behaviour or sometimes aggressive behaviour. Ten out of 30 children took medication mainly for hyperactive behaviour and difficulties concentrating. One person received medication for a mood disorder and another for obsessive compulsive behaviour. Parents reported that medication was effective. Autistic behaviour is reported in some children with isochromosome 18p (O'Donnell 2015).

“ We cannot predict his behaviour. For example, he is hugging but suddenly he starts punching. He does not understand the feelings of others.”

“ When angry or happy our child reacts emotionally. Everything is very intense and pure. ”

“ He has many autistic features. ”  
11 years

## Medical concerns

### ■ Head and brain

Approximately 20-25% of children with isochromosome 18p have seizures and/or epilepsy. One study reports that 7 out of 42 children had seizures when they had a fever (O'Donnell 2015).

Six children reported in the medical literature had a myelomeningocele (Takeda 1989; Boyle 2001; Sebold 2010). In a myelomeningocele the backbone and spinal cord have not closed properly before birth. There is a small fluid filled sac on the lower back that contains cerebrospinal fluid, tissues that protect the spinal cord and sometimes portions of the spinal cord and nerves. Symptoms vary, but can include paralysis, spasticity and loss of sensation.

Twelve out of 42 children had an MRI of the brain done. In 7 children the MRI showed abnormalities. Three children had enlarged ventricles, in 3 the corpus

callosum (a brain structure that connects the left and right sides of the brain) was unusually small or thin. One child had a lipoma (a benign tumor composed of fat tissue) (O'Donnell 2015).

In another child reported in the medical literature the cerebellum (part of the brain that is important in the coordination of movement) was underdeveloped (Schwingle 2006).

### ■ Heart

One study reports that in 15 out of 32 people who had an ultrasound of the heart performed, the ultrasound showed abnormalities. The most common defects were holes between the left and right upper and lower chambers of the heart (atrial septal defect and ventricular septal defect or patent foramen ovale). Seven people had a patent (open) ductus arteriosus (PDA). The ductus arteriosus is a short vascular structure between the pulmonary artery and the aorta. The structure normally closes after birth. Most defects did not require surgery. One child had to be operated on. Other abnormalities that have been reported are prolapse or leakage of one of the heart valves, an abnormally shaped heart valve, an underdeveloped aortic root, thickening of the heart muscle and narrowing of one of the heart valves (Sebold 2010).

Other articles describe pulmonary hypertension, leakage over the pulmonary valve, a disruption of the aortic root and a thickening of the heart muscle as a result of anaemia (DeBerardinis 2006; Ramegowda 2006; Jung 2013).

### ■ Hands and feet

People with isochromosome 18p may have somewhat unusually shaped hands and feet (Batista 1983; Callen 1990; Sebold 2010). Fingers may be abnormally bent (camptodactyly or clinodactyly). In some children the thumb can be placed slightly inward or may be bent. Fingers may show some tapering and some children show webbing of some toes (syndactyly). In addition, some children may show abnormal creases of their hands (e.g. a single palm crease) (Batista 1983). One person had underdeveloped nails (Boyle 2001).

### ■ Skeleton and bones

Approximately one third to half of children have abnormalities of their spinal column, including an abnormal curvature (scoliosis or kyphosis) (Sebold 2010). Seventeen per cent of the children had hip dysplasia (Sebold 2010). Other abnormalities include differences in leg length, an abnormal 12th rib, club feet, abnormalities of the bones in the feet and rocker bottom feet (Takeda 1989; Sebold 2010; Jung 2013). A stillborn girl had abnormalities of the bones of her skull and abnormally bent legs (Takeda 1989).

### ■ Gastrointestinal tract

Feeding difficulties are common in children with isochromosome 18p as reported above (page 4-5). In addition, 75% of the children suffered from constipation. Approximately one third of children had gastroesophageal reflux (Sebold 2010).