



Understanding Chromosome & Gene Disorders

**Rare Chromosome Disorder Support Group,**  
The Stables, Station Rd West, Oxted, Surrey. RH8 9EE, UK.  
Tel: +44(0)1883 723356  
info@rarechromo.org | www.rarechromo.org

**Join Unique for family links, information and support.**

Unique is a charity without government funding, existing entirely on donations and grants. If you can please make a donation via our website at:  
[www.rarechromo.org/donate](http://www.rarechromo.org/donate) Please help us to help you!

This leaflet is not a substitute for personal medical advice. Families should consult a medically qualified clinician in all matters relating to genetic diagnosis, management and health. The information is believed to be the best available at the time of publication. It was compiled by Unique and reviewed by Professor Margaret Nowaczyk at McMaster University, Hamilton, Canada.

2013 Version 1 (JH/SW)

Copyright © Unique 2018



Understanding Chromosome & Gene Disorders

## Microdeletions of 17p13.1 and 17p13.2



## Sources

The information in this guide is based on 16 individuals and is drawn partly from the published medical literature and partly from a survey of members of Unique conducted in summer 2012, referenced Unique.

At time of writing [December 2012] there were 10 relevant cases in the medical literature, all with a 17p13.1 microdeletion. There is currently no literature concentrating specifically on 17p13.2 microdeletions. Two of the cases in the literature are also Unique members.

When this guide was written, Unique had eight members with a 17p13.1 and/or 17p13.2 microdeletion ranging in age from one and a half years old to 11 years old. Five of these members had a 17p13.1 microdeletion, one member had a 17p13.2 microdeletion and two members had both a 17p13.1 and 17p13.2 microdeletion.

The oldest person reported in the literature was 33 years old [Shlien 2010]. The first-named author and publication date are given to allow you to look for the abstracts or original articles on the internet in PubMed (<http://www.ncbi.nlm.nih.gov/pubmed>). If you would prefer, you can obtain most articles from Unique.

## Microdeletions of 17p13 : 17p13.1 and 17p13.2

A 17p13 microdeletion is a rare disorder in which a small part of the genetic material that makes up one of the body's 46 chromosomes is missing. Although the other chromosomes are intact, this small missing piece does increase the possibility of developmental delay and learning difficulties. However the problems can vary and depend very much on what genetic material is missing. Chromosomes are made up mostly of DNA and are the structures in the nucleus of the body's cells that carry genetic information (known as genes), telling the body how to develop and function. Chromosomes usually come in pairs, one from each parent, and are numbered 1 to 22 approximately from the largest to the smallest. In addition to these 44 chromosomes, each person has another pair of chromosomes, called the sex chromosomes. Girls have two Xs (XX), whereas boys have an X and a Y chromosome (XY). Each chromosome has a short (p) arm (shown at the top in the diagram below) and a long (q) arm (the bottom part of the chromosome).

For healthy development, chromosomes should contain just the right amount of material – not too much and not too little. People with 17p13 microdeletions have one intact chromosome 17, but the other is missing a tiny piece from the short arm which can affect their learning and physical development. Most of the clinical difficulties are probably caused by the presence of only one copy (instead of the usual two) of a number of genes. However, a child's other genes and personality also helps to determine future development, needs and achievements.

## Looking at Chromosome 17p13

People who have missing material on a chromosome are said to have a deletion but when the amount is so small that it can't be seen even under a high-powered microscope, it is called a **microdeletion**. The 17p13 microdeletion can be found using molecular techniques such as multiplex ligation-dependent probe amplification (MLPA) and array comparative genomic hybridisation (array-CGH) or by cytogenic fluorescence *in situ* hybridisation (FISH) techniques. These techniques show whether particular genes are present or not.

Base pairs are the chemicals in DNA that form the end of the 'rungs' of its ladder-like structure. The size of the microdeletion is variable and in different people the base pairs where the chromosome has broken (the

## The *TP53* gene and Li-Fraumeni Syndrome

Li-Fraumeni syndrome can cause predisposition to acquiring some cancers. The gene that holds Li-Fraumeni syndrome in check is called the *TP53* gene. Some (not all) individuals with a 17p13.1 and/or 17p13.2 microdeletion only have one copy of this gene, instead of the usual two, and may have an increased risk of developing the syndrome. Although no one with a 17p13.1 and/or a 17p13.2 microdeletion has yet been reported to have Li-Fraumeni syndrome, most researchers recommend sensible precautionary monitoring measures, such as regular medical appointments and a referral to Oncological (Cancer) Services [Krepischi-Santos 2009; Schluth Bolard 2009; Schwarzbraun 2009].

If you have concerns, or would like more information, then it would be helpful to discuss your child's personal circumstances with your geneticist or genetic counsellor. They would be able to tell you if one copy of the *TP53* gene has been lost as part of your child's microdeletion, and if so, whether they would recommend screening, especially in later life.

## How did the 17p13.1 and/or 17p13.2 microdeletion occur?

A blood test to check both parents' chromosomes is needed to find out why the 17p13 microdeletion occurred. In all cases where we have the information, the microdeletion occurred when both parents have normal chromosomes. The term that geneticists use for this is *de novo* (dn) which means 'new'. *De novo* 17p13 microdeletions are caused by a change that occurred when the parents' sperm or egg cells formed, or possibly during the formation and copying of the early cells after the egg and sperm joined. As a parent there is nothing you did to cause the 17p13 microdeletion and nothing you could have done would have prevented it from occurring in your baby. No environmental, dietary or lifestyle factors are known to cause these chromosome changes. No one is to blame when this occurs and nobody is at fault.

## Can it happen again?

The possibility of having another pregnancy with 17p13 microdeletion depends on the parents' chromosomes. If both parents have usual chromosomes (as in all the known cases so far), the deletion is very unlikely to happen again. However, there is a very small possibility that the deletion occurred during the formation of the egg or sperm cells in a parent (known as **gonadal mosaicism**). When this occurs there is a tiny chance that parents with apparently usual chromosomes could have another affected pregnancy. However, if either parent has a chromosome rearrangement or deletion involving 17p13, the possibility of having other affected pregnancies is greatly increased.

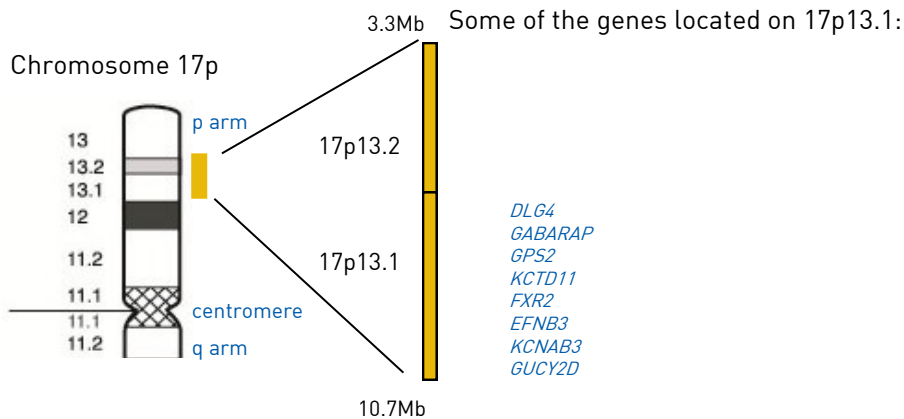
Parents should have the opportunity to meet a genetic counsellor or clinical geneticist to discuss their specific recurrence risks.

microdeletions. As the molecular techniques which are needed to detect this microdeletion become more commonplace, further people are likely to be diagnosed.

## Ongoing research

A 17p13.1 and/or 17p13.2 microdeletion is tiny, so it can only be found using molecular techniques such as MLPA or microarrays (array-CGH) or targeted cytogenetic testing using FISH. These techniques show whether particular genes are present or not. The features of 17p13.1 and/or 17p13.2 microdeletions are likely to be the result of the loss of a number of different genes found in this region.

The size of the microdeletions that have been documented in this guide range from approximately 219kb to 1.6 Mb. Most deletions at least partially overlap.



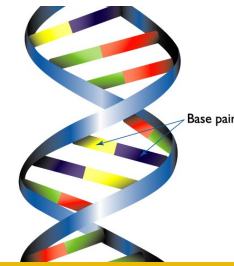
Researchers have been trying to identify genes which might potentially cause features of individuals with 17p13.1 and/or 17p13.2 micro deletions and some of these are outlined below.

Loss of the *KCNAB3* potassium channel gene has been linked to seizure activity [Schwarzbraun 2009].

Disruption of the *GUCY2D* gene has been found to cause impaired vision (cone-rod dystrophy) [Schwarzbraun 2009].

Missing a copy of the *EFNB3* gene or the *FXR2* gene means there will be problems producing certain proteins that are involved in brain development. Therefore affected individuals may have learning difficulties [Schluth-Bolard 2009]. Other genes that may be candidates for causing learning difficulties include *KCTD11/REN*, *GPS2*, *GABARAP* and *DLG4/PSD95* [Krepisch-Santos 2009, Zeesman 2012].

It is important to remember that while identifying gene(s) responsible for certain features of the 17p13.1 and/or 17p13.2 microdeletions is valuable and may guide future studies, it does not lead directly to immediate improved treatment. Additionally, even if the supposedly responsible gene is missing it does not always mean that the associated feature(s) will be present. Other genetic and environmental factors often have a role in determining the presence or absence of a particular feature.

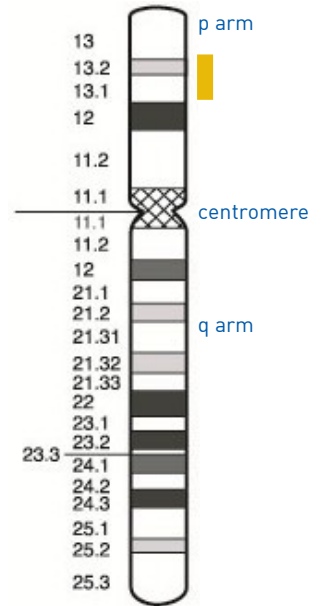


1 base pair = bp  
1,000 base pairs = 1kb  
1,000,000 base pairs = 1Mb

breakpoints') are different.

The 17p13.1 and 17p13.2 region is denoted by the red bar on the diagram on the right. Band 17p13.1 contains about 4 million base pairs or 4Mb. One Mb is one million base pairs of DNA whilst one Kb is one thousand base pairs of DNA. 4 Mb is equivalent to approximately five per cent of the DNA in chromosome 17. Band 17p13.2 contains about 3 Mb and makes up about 3.75 per cent of the DNA in chromosome 17.

Chromosome 17 spans about 80 Mb and represents between two and a half to three per cent of the total DNA in each cell.



## Is there a 17p13.1 and/or 17p13.2 microdeletion syndrome?

When a particular set of developmental features occurs in a recognisable and consistent pattern in enough people, as a result of a single cause, the condition is called a syndrome. The medical literature concentrates on 17p13.1 microdeletions; there is little to no information on 17p13.2 microdeletions. '17p13.1 microdeletion syndrome' has been mentioned in one study [Shlien 2010] and 'distal (nearer to the end of the chromosome) 17p13.1 microdeletions' were described as a new syndrome in a second article [Zeesman 2012].

## Results of the genetic test

You are likely to be given the results of molecular analysis such as FISH or array-CGH for your child. In this case the results are likely to read something like the following example:

**arr[hg19] 17p13.2p13.1 (5611341-7186379)x1**

arr  
hg 19

The analysis was by array-CGH

Human Genome Build 19. This is the reference DNA sequence that the base pair numbers refers to. As more information about the human genome is found, new 'builds' of the genome are made and the base pairs numbers may be adjusted.

**17p13.2p13.1** Chromosome 17 has two breakpoints, one in band 17p13.2 and one in band 17p13.1

**(5611341-7186379)x1**

The base pairs between 5611341 (around 56) and 7186379 (around 72) have been shown to be deleted. Take the first long number from the second and you get 1575038 (1.5Mb). This is the number of base pairs that are deleted. x1 means there is one copy of these base pairs, not two - one on each chromosome 17 - as you would normally expect.

## Remapping to Genome Reference Consortium human genome Build 37 (hg19)

There are several 'genome builds' currently used by genetic laboratories. A genome build is a reference DNA sequence with which your child's DNA can be compared. If your child has had a microarray, the genetic report should state the Human Genome Build that has been used. This is most likely to be NCBI Build 35 (also known as hg 17), NCBI Build 36 (hg18) or Genome Reference Consortium [human genome](#) (build 37) (GRCh37 or hg19). To ensure Unique's results are as consistent as possible, whenever possible, we have mapped base pair microarray coordinates to hg19 / GRCh37. This is because it is the most recent Human Genome Build at time of writing (December 2012), and is also the build that is used for case reports in the Decipher database (<http://decipher.sanger.ac.uk>) and the ISCA database. To re-map base pair coordinates from another genome build to hg19/B37, please contact Unique or your genetic specialist. It is likely that a new Human Genome Build will also be introduced in the future, although the exact date of this is unknown at present.

## First Signs and Age at diagnosis

We have information on age of diagnosis for four Unique children. The age at which 17p13.1 and/or 17p13.2 microdeletion has been diagnosed ranges from eight months old to five years old.

One child was given a genetic test at around six months of age as he was not meeting his milestones – he could not hold his head up and was not using his arms at all. Another child initially had genetic testing at the age of 12 months after she had an MRI of the brain which showed some changes. (Magnetic resonance imaging or MRI is a non-invasive medical imaging technique which uses radio and magnetic waves to provide a very detailed image of organs, bones and tissues inside the body). She had a karyotype and testing for metabolic problems, neither of which showed any issues, and it was not until she had a microarray aged five that her microdeletion was found [Unique].

## Emerging phenotype: what to expect

When only very small numbers of individuals have been identified with a 17p13.1 and/or 17p13.2 microdeletion, we can't yet be certain what the full range of possible effects of the disorder will be. The features that are most striking and most common are:

- Learning (intellectual) disability requiring extra learning or educational support
- Speech and language delay
- Developmental delay especially motor delay
- Eye problems such as squint and possible problems with sight
- Slim stature
- Low muscle tone (hypotonia)
- Feeding problems, both as a newborn and/or in later life

Less common features are:

- Heart problems
- Seizures
- Behavioural problems including features of autism spectrum disorder

(moving) or on a swing...she loves toys that make funny noises and bounce about or rainmakers/drums...she remembers songs in the car and becomes very excited. She loves watching my mum's dog move about or my mum's ceiling fan." 9 years.

"Her personality is very sweet and she's always happy. For the most part her behaviour is fine, but when frustrated she acts up a bit. She interacts well with adults but shuts down around kids... She likes music, tv, horseback riding." 9.5 years.

## Sleep

Some children with 17p13.1 and/or 17p13.2 microdeletions can have problems with sleep. We have information on seven individuals in respect to their sleeping patterns. One child aged three previously had difficulty sleeping but has recently started sleeping well and through the night. Four children have difficulty with going to sleep and/or with waking during the night. One child oversleeps and is hard to wake in the morning [Unique]. From the parents Unique surveyed, some have found techniques such as rocking, holding or playing with their child useful. Playing soothing music or milky drinks can be helpful. Medication, such as melatonin, has also been found to be beneficial for some individuals, as has the use of sleep systems [Shlien 2010; Unique].

"Alfie does not sleep! He goes to sleep ok then wakes every one to two hours or will wake and stay awake for up to four hours. He is being referred for sleep studies." 18 months.

"She still tires easily and naps for long periods...she actually oversleeps still." 33 months

"For the first three years, she had problems sleeping; we simply got up and played with her or rocked her until asleep...she has recently started sleeping through the night." 3 years.

"He sleeps in a high-sided cot with the sides up as he can get out and would fall...he loves his dummy and needs it to sleep but it must always be on a cord otherwise he'll put it in his mouth and could choke." 5.5 years

"Sometimes Penny will remain awake during the night – probably a whole night every fortnight, clapping her hand, wringing her hands, grinding her teeth and even squeezing her arms...I sometimes find trying to swaddle her with a blanket tucked in...and getting her to cuddle a warm microwavable teddy helps. With some Calpol (paracetamol) and a warm milky drink!" 9 years.

## Puberty and fertility

Due to the small numbers of people so far reported with 17p13.1 and/or 17p13.2 microdeletions, there is very little information on puberty. One Unique girl aged nine was reported to have a small amount of pubic hair but had not started periods [Unique]. There is no information in the medical literature on puberty at present. There is no information in the literature on any individuals with the microdeletion having given birth to a child.

## Adults with 17p13.1 and/or 17p13.2 microdeletion

There is just one adult, aged 33, who has been described in the medical literature. This lady is non verbal and has global developmental delay and learning difficulties [Shlien 2010].

There will certainly be more people, including adults, with 17p13.1 and/or 17p13.2

## Behaviour

Children with 17p13.1 and/or 17p13.2 micro deletions have happy friendly personalities but may also have behavioural problems

Children with 17p13.1 and/or 17p13.2 microdeletions often interact well with others, especially with adults. However, they are as vulnerable to frustration as other children with a communication difficulty and some children can succumb to temper tantrums and aggression.

Three children are described as having autism spectrum disorder (ASD). This is a developmental disorder that is usually diagnosed in childhood. Autistic traits can include hand flapping; self stimulating behaviours including spinning, hitting objects or looking at their hands; repetitive behaviours; difficulty adjusting to new routine or environment; poor social awareness and a lack of eye contact. Two children had exhibited self-harming behaviour; one boy bites his own hand and can bite other people. One woman aged 33, described in the medical literature, has severe behavioural problems including aggressive behaviour, ASD, self harming behaviour and bipolar disorder [Shlien 2010]. Occasionally children seem to have sensory processing issues, especially to loud noise or touch (2/13). This occurs when the brain is unable to integrate information received from the body's five senses – sight, sound, smell, taste and touch [Krepischi-Santos 2009; Shlien 2010; Zeesman 2012; Unique].

Children with 17p13.1 and/or 17p13.2 microdeletions often share a love of music and music therapy has been reported as beneficial and enjoyable by several families [Unique].

“She is a very happy child.” 15 months

“Alfie is very friendly and happy but with a stubborn streak. He has episodes of screaming which sometimes last an hour and at least twenty minutes. It is being investigated (to try to find out) what is causing this – pain (sensory), digestion etc??... He likes books, cars, buses, people and eating.” 18 months

“She is usually very happy, and likes to show off and be cute in a crowd...she is compassionate, and has such a cute sense of humour...she fights with her sister and has the two year old tantrums which is typical. She does get frustrated when we can't understand her... She has taught that every day is special, and to be thankful everyday for who you are and what you have.” 33 months

“She enjoys music, dancing, playing on trampoline, swimming and playing with her big brother. She loves everyone but has trouble in large crowds if for extended times...Lady Katie has a joyous laugh and is happy 95% of the time. She is my heart.” 3 years

“He has autistic traits - must always follow the same daily routine whenever possible, without too much input which he finds very difficult to cope with; overreacts to the smallest changes; cannot tolerate a busy atmosphere; not too loud or hectic... He loves music including children's songs, preferably sung to him. He also loves bathing, showering, other children, likes to look on, moving around...being where it's all happening, even if he can't walk.” 5.5 years

“Penny has a serene personality which calms myself, and (which) others have mentioned. She loves holding hands and rubbing your arm...On good days, Penny is alert and giggling. On bad days she doesn't want to do anything... Penny loves being around other people, she used to get very upset on her own...She loves going out in the car

## Pregnancy

Most mothers carrying babies with a 17p13.1 and/or 17p13.2 microdeletion experienced no major problems in pregnancy, had an uncomplicated delivery and only discovered their baby was affected with the microdeletion after the birth.

There is information on 11 pregnancies of mothers carrying a baby with a 17p13.1 and/or 17p13.2 microdeletion. Six mothers had no pregnancy problems and no unusual findings on ultrasound scans. There were reduced foetal movements in three pregnancies; one of these pregnancies also resulted in a slightly early birth at 35 weeks and another of these pregnancies revealed a cyst on the baby's kidney during an ultrasound scan. The cyst resolved after birth. One mother experienced severe health problems herself during pregnancy [high blood pressure and a pulmonary embolism (clot on the lung)], meaning her child became oxygen deprived and had two brain haemorrhages. We do not have any further information about the newborn period in this child. One mother gave birth slightly early at 35 weeks but experienced no other problems [Krepischi-Santos 2009; Schluth-Bolard 2009; Schwarzbraun 2009; Zeesman 2012; Unique].

## Newborn

Some babies with 17p13.1 and/or 17p13.2 micro deletions experienced problems in the newborn period.

There is information on 10 newborn babies with 17p13.1 and/or 17p13.2 microdeletions. Five newborns experienced no problems after birth. Three babies experienced breathing difficulties (including grunting in two) after birth and of these, one baby required oxygen, and another had a subdural haematoma (a collection of blood between the skull and the brain which can occur after birth. The baby needs to be monitored to ensure further symptoms, such as jaundice, do not occur as a result). One baby born at term was cyanosed (was blue in colour) and had reduced muscle tone and a weak cry. Two babies became jaundiced after birth. Jaundice is caused by a build-up of a substance called bilirubin in the blood and tissues of the body and can cause yellowing of the skin and the whites of the eyes. Jaundiced babies can sometimes require treatment such as phototherapy. This is a treatment where babies have a special blue light shone on their bare skin. This is absorbed by the skin and helps break down the bilirubin in the body.

Several of the babies born were quiet and/or sleepy and did not react as much as was expected. One baby was found to have hip dysplasia in both hips (hip instability due to a problem with the hip socket or the upper leg bone) in the days following the birth. She had a Pavlik harness (harness that holds the hips in the proper position so they will form normally) for six months to correct this. This baby was also found to have brachycephaly (where the back of the head is flattened and wide compared to its depth) possibly because of lying on her back more often due to wearing the harness [Krepischi-Santos 2009; Schluth-Bolard 2009; Schwarzbraun 2009; Zeesman 2012; Unique].

## Feeding and growth

Feeding and growth is often affected in children with 17p13.1 and/or 17p13.2 micro deletions.

Most babies with 17p13.1 and/or 17p13.2 microdeletions were born at term, or near to term, and had a birth weight within normal range. [Krepischi-Santos 2009; Schluth-Bolard 2009; Schwarzbraun 2009; Zeesman 2012; Unique].

Feeding difficulties appear to be common, and often feeding problems commence at birth. Feeding difficulties have been reported in three cases in the literature [Shlien 2010]

and in six out of eight members of Unique. The hypotonia (low muscle tone) and high palate that is common in babies with 17p13.1 and/or 17p13.2 microdeletions can lead to difficulties with sucking and swallowing, and/or latching onto the breast.

Several babies struggled with breast feeding, with difficulties such as latching on to the breast, or the baby falling asleep during feeds. Occasionally switching to bottle-feeding (with expressed breast milk or formula milk) helped. One baby had a cleft lip and palate. This can make sucking and swallowing very difficult. A second baby benefited from having a temporary nasogastric tube (NG tube, a tube that is passed up the nose and down the throat to the stomach) until the age of six months [Unique].

One Unique child had a PEG (Percutaneous Endoscopic Gastrostomy) button fitted which allows feeding directly into the stomach. This child has a swallowing disorder and only takes small amounts of pureed food like soft cheese and soft bread orally, with other nutrition and fluids given via the PEG. Another Unique child was waiting for a gastrostomy procedure at the age of six and a half years old, due to feeding difficulties, and only being able to take a little pureed food orally.

Hypotonia can also affect the passage of food in 17p13.1 and/or 17p13.2 microdeletion children and contribute to gastro-oesophageal (GO) reflux (in which feeds return readily up the food passage). Three out of eight children surveyed by Unique had GO reflux; one separate case in the medical literature was also described as having GO reflux [Shlien 2010]. GO reflux can generally be well controlled by giving feeds slowly, positioning a baby semi-upright for feeds and where necessary raising the head of the end of the bed for sleeping. Feed thickeners and prescribed medications to inhibit gastric acid may control reflux. If these measures are not enough, some babies benefit from a fundoplication, a surgical operation to improve the valve action between the stomach and food passage. One child with a 17p13.1 microdeletion has had such a procedure [Unique]. Some older babies, toddlers and children have difficulty chewing and can choke or gag on lumps in food. As a result children may continue to eat pureed food or soft foods for much longer than their peers and each meal may take some time to complete [Unique].

“Can self-feed at 15 months old. Doctors tested her for Prader Willi as she doesn't know when to stop eating (she did not have it).” 15 months

“It takes ages for him to drink from a bottle as he couldn't suck very easily” 18 months

“He has a PEG gastrostomy (button at present) on account of feeding difficulties...has gastrostomy tube chiefly for fluids as he doesn't drink enough.” 5.5 years

“She has very poor feeding and eats only a little pureed food. She is waiting for a gastrostomy placement as soon as possible.” 6.5 years

“Her food is now slightly more chopped –not pureed...she still needs to be fed and needs help with drinking from a Doidy Cup (thickened milk or juice). She has a bottle at night time – I need to hold this...have to keep a good rhythm going when feeding, continue, do not stop or go away and come back. She will not start again.” 9 years

“Her meals are still pureed as she can't form a bolus, or move her tongue around to swallow solid meals.” 9.5 years

From the information available to us, the height of children with 17p13.1 and/or 17p13.2 microdeletions seems to vary. Four children are described as having small stature. However two other individuals are reported as having tall stature. One child had failure to

A brain MRI scan is often performed on children with 17p13.1 and/or 17p13.2 microdeletions and there is information on 11 individuals. Of these, three children had a normal MRI and eight children had an MRI which showed changes to the normal structure of the brain. Three children had a diagnosis of hydrocephalus (abnormal expansion of cavities within the brain caused by the accumulation of excess spinal fluid) [Schluth-Bolard 2009; Schwarzbraun 2009; Shlien 2010; Zeeman 2012; Unique].

“She suffers with full Tonic Clonic (seizures) that last about one minute, she has been having these regularly – every week; more when she has another illness...She gets very tired during the school week, which might be due to her epilepsy and medications, and sometimes she sleeps all day at school” 9 years

#### ■ Digestion

Children with 17p13.1 and/or 17p13.2 microdeletions can have digestive problems, such as constipation.

Out of six Unique children that we have information on, two-thirds (4/6) suffered from constipation. All affected children were on laxatives or suppositories. One other child had a megacolon (distended large intestine). We do not know if treatment was required for this [Unique].

#### ■ Limbs and Joints

Children with 17p13.1 and/or 17p13.2 microdeletions can have limb or joint problems.

Ligamentous laxity (loose ligaments) seems to be more common in children with 17p13.1 and/or 17p13.2 microdeletions (occurs in two of ten individuals). Joint laxity has also been reported (3/10).

Two children had brisk reflexes (muscle contraction in response to a stimulus, such as a knee jerk) but conversely one child had reflexes that were difficult to elicit. Several children (4/13) had contractures (tightening of tissues such as muscle, tendons or ligaments meaning it is much more difficult to passively stretch that tissue) of the elbows, knees, hamstrings and/or legs. Therapy included leg splints but one child had had injections of Botox as treatment for her tight hamstrings [Unique]. In the literature, it was reported that one five year old had outward turning (valgus) and deformity of both ankles [Shlien 2010]. [Schluth-Bolard 2009; Shlien 2010; Zeeman 2012; Unique].

“He has leg contractures. He must wear leg splints daily as his tendons are already severely shortened.” 5.5 years

#### ■ Other Medical Concerns

A 33-year-old woman described in the literature had haemolytic anaemia of infancy (a condition where red blood cells are destroyed too early and removed from the bloodstream) which self-resolved. She also had pure red cell aplasia (where the bone marrow does not make red blood cells) which started when she was 15 years old. She also has hypothyroidism and iron overload secondary to needing blood transfusions every three to four weeks [Schlien 2010].

Of the Unique families, a child aged nine has hypogammaglobulinaemia (an immune problem where the body does not make enough antibodies) and has to take injections to replace these. Another child is described by her family as being 'vulnerable to infection' and her parents therefore ensure her immunisations are always up to date.

It is important to remember that when only one person has been described with a medical concern, that it may be coincidental, and not related to the microdeletion.

through the hole into the other pumping chamber from where it is pumped around the body. The majority of babies with Tetralogy of Fallot successfully undergo surgery in the first year of life.

Two children are known to have needed heart surgery. One child had surgery for a complex atrial septal defect (ASD). This is a hole in the wall between the two smaller chambers of the heart that receive blood from the pumping chambers (atria). Her energy levels greatly improved after the operation. Another child had multiple heart problems including a severe PDA, VSD, ASD and pulmonary hypertension (increase in blood pressure in the vessels that supply the lungs) and required a surgical repair [Schluth-Bolard 2009; Shlien 2010; Zeesman 2012; Unique].

“An EKG (ECG)[test which measures the electrical activity of the heart] showed an enlarged right heart... She was very low in energy and would often only be up for five hours a day... an ECHO found one large hole (in the heart) but during open heart surgery she was found to have two large holes and multiple smaller holes. Since surgery her energy levels have greatly improved.” 15 months

### ■ Genitourinary Anomalies

Some children with 17p13.1 and/or 17p13.2 microdeletions experience genitourinary problems.

One child aged nine has ovarian cysts. She also had a kidney cyst, diagnosed on antenatal ultrasound, which resolved after birth [Unique].

Another girl has kidney stones and still passes stones on occasion. Her kidneys are described as being shaped like footballs but they function normally. One child aged nearly three urinates infrequently. She used to take medication to help with this but no longer does so. Her kidneys and bladder are normal [Unique].

In the medical literature, there is little information available about genital anomalies. However one boy was described as having a shawl scrotum (where the scrotum surrounds the penis, resembling a shawl). Two other children are described as having a normal genitourinary system [Shlien 2010, Unique].

### ■ Seizures

Children with 17p13.1 and/or 17p13.2 microdeletions may have an increased risk of seizures.

Seizures, or fits, are caused by a change in electrical activity in the brain. There are a number of different types, including epilepsy. There is information on 10 individuals from the Unique members and from the medical literature. Three of these individuals had never had a seizure.

An electroencephalogram (EEG) is a medical test which measures and records electrical activity in the brain and can sometimes detect certain conditions, such as seizures. In the medical literature one 10 year old boy had an abnormal EEG and another child had short episodes of myoclonic seizures (involuntary twitching of muscles) within the first year of life. These may be prevented by administration of medication.

From the Unique children, there are five reports of seizures, which vary in type. These include one child who has possible absence seizures (brief seizures where the individual appears 'absent' or can seem to stare into space) and another child who has had febrile seizures (a seizure occurring when the child has a fever). Two children have epilepsy requiring medication and an 11 year old has epilepsy but there are no other details [Unique]. [Schwarzbraun 2009; Zeesman 2012; Unique].

thrive (when a child's weight or rate of weight gain is significantly below that of other children of similar age and gender) and is now tall and thin [Unique].

Four out of 12 individuals would be defined as underweight and three are described as being slim. There is also variation in head size with three individuals having macrocephaly (large head) and four having microcephaly (small head) [Krepischi-Santos 2009; Schluth-Bolard 2009; Shlien 2010; Zeesman 2012; Unique].

“He is tall and slim – very tall for his age but so are both parents!” 18 months

“She is very tiny for her age. She is broader on top (3 yrs old Toddler shirt size) and tiny on bottom (18 months pants).” 33 months

“She has tall thin swimmer's build.” 3 years

“Penny is long and slim. She is about average height for her age, she has small feet and long fingers.” 9 years.

## Appearance

Children with 17p13.1 and/or 17p13.2 microdeletions can vary widely in appearance and often resemble family members. However features which can appear more commonly in these individuals include high or narrow forehead, prominent and/or low set ears, prominent or wide-based nose, high arched palate (roof of mouth), eye ptosis (drooping eyelid) and micrognathia (small chin/jaw). Another is described as having no unusual features [Krepischi-Santos 2009; Schluth-Bolard 2009; Schwarzbraun 2009; Shlien 2010; Zeesman 2012; Unique].

“She has a cherubic appearance.” 3 years

## Development : sitting, moving, walking (gross motor skills)

Children with 17p13.1 and/or 17p13.2 micro deletions are often delayed in learning to sit and walk.

Often gross motor skills are affected and this means that it may take longer for children to roll over, sit, crawl and walk. From the limited information available (seven individuals), children sat unaided between the ages of 10 months and 18 months (average 16 months). Babies started to crawl between eight months and three years (average 22 months). Independent walking was mastered by some children between 23 months and seven years (average 3.3 years). One child is still unable to sit independently, crawl or walk at nine years of age. Other children can walk but need help with balance and some children have great difficulty climbing stairs.

One seven year old could walk without support but with ataxic (uncoordinated) movements [Schwarzbraun 2009]. Two individuals in the medical literature were described as having a wide based stand and gait; one of these children had poor balance with a tendency to fall [Zeesman 2012]. Two children are wheelchair dependent [Unique]. Some Unique families have found devices such as ankle/calf braces, supportive shoes, standing frames or



walkers useful [Krepischi-Santos 2009; Schluth-Bolard 2009; Schwarzbraun 2009; Shlien 2010; Zeesman 2012; Unique].

These delays in walking may be attributed to hypotonia, which is common in children with 17p13.1 and/or 17p13.2 microdeletions (found in 14/16 children). One child had a combination of hypotonia and hypertonia (increased muscle tone). Contractures (tightening of tissues such as muscle, tendons or ligaments meaning it is much more difficult to passively stretch that tissue) have also been reported and may make motor function more difficult. Physiotherapy has proved beneficial to many children [Unique]. Difficulties with hand-eye coordination, planning, organisation and poor balance can also contribute to these delays. The continuing difficulties with balance means that some children are unsteady on their feet and fall easily [Krepischi-Santos 2009; Schluth-Bolard 2009; Schwarzbraun 2009; Shlien 2010; Zeesman 2012; Unique].



“ She gets around by army crawling, using her right side mainly because as time goes her left side seems much weaker. She can use her hands but cannot apply pressure with them.” 15 months.

“ Alfie is reliant on us to move him, although he can now get from lying to sitting & starting to commando crawl small distances.” 18 months

“ Profound and multiple delay. He is wheelchair-dependent – he can only sit alone for a very short time – he cannot stand or walk.” 5.5 years

“ Penny is at the very beginning of all the developmental stages. She still does not sit unaided and is still very floppy, not able to weight bear...she still casts objects away on her tray, picks them up, holds them for a while and then drops them, like a baby.” 9 years

“ Olivia walks but has no protective reflexes. She cannot climb stairs.” 9.5 years

## Development: hand-eye co-ordination and dexterity (fine motor skills) and self care

Hypotonia can affect fine motor skills in children with 17p13.1 and/or 17p13.2 microdeletions.

Joint laxity (loose or unstable joints, also known as hypermobility) and contractures (tightening of tissues such as muscle, tendons or ligaments meaning it is much more difficult to passively stretch that tissue) have also been reported in these children and so they may take longer, for example, to reach for and grab toys and hold a bottle or cup. This can lead to delays in children being able to self-feed, dress themselves (zips and buttons can be especially problematic) and hold a pen to write or draw. Special bottles, cups with handles and cutting up food have helped some children [Unique].

Toilet training may also be affected. From the limited information that is available, children are significantly delayed in learning toilet training. Of the five children we have information on, none were toilet trained; the oldest two of these children were both nine years old and the youngest was two years 10 months. One nine year old still wore nappies but had learned to sit on the toilet. Another nine year old still wears nappies because of a neurogenic bladder (dysfunction of the bladder due to a problem with the nervous

(temporary pauses in breathing which can occur during sleep). He was being referred for sleep studies (a test which monitors what happens to your body during sleep). He had an inhaler which he used when wheezy, usually when he had a cold. However he did not suffer from recurrent chest infections [Unique].

### ■ Body

Some children with a 17p13.1 and/or 17p13.2 microdeletions can have unusual features on the body.

Two children had extra or inverted nipples. One of these children also had extra creases on her calves and arms, and a mild chest (pectus) deformity. A nine year old girl has a weaker right side. She has required surgery to have her appendix out. Another child, described in the medical literature, has benign paroxysmal torticollis (twisting or tilting of head and neck which resolves spontaneously; usually going away after the first few years of life) [Shlien 2012; Unique]. [Krepischi-Santos 2009; Schluth Bolard 2009; Shlien 2010; Unique].

### ■ Skin

Children with 17p13.1 and/or 17p13.2 microdeletions can have changes to the skin.

One child has no pigment (achromic) patches on the right part of his chest suggesting a diagnosis of hypomelanosis of Ito (where there are whirls or streaks of lighter patches on the skin; it can occur with other symptoms like learning difficulties or medical problems) [Schluth Bolard 2009]. Two children had birthmarks, one of these was a Mongolian spot (blue birth mark) on the lower back. One child had a dermoid cyst (non cancerous growth) above her eye which was surgically removed [Shlien 2010; Unique].

### ■ Allergies

Allergies are common in children with 17p13.1 and/or 17p13.2 microdeletions.

Of the five Unique children we have information on, all five had allergies. One child has an allergy to latex and dairy so drinks hemp milk. Another child is allergic to pears. A third child is allergic to plasters which cause a red inflamed area on the skin. A child aged two years and ten months has an allergy to milk protein which she seems to be out-growing. Another child has allergies which include some fruits, peanuts and some medications for pain management. He also has neurodermatitis (an itchy skin condition) and cannot tolerate any perfumes [Unique].

### ■ Heart

Some children with 17p13.1 and/or 17p13.2 microdeletions can have heart problems.

Of 11 children with 17p13.1 and/or 17p13.2 microdeletions, five are currently reported to have no heart problems. Heart problems in other children varied and included one child who had a heart murmur which was present from birth (congenital murmur). Another child had a patent ductus arteriosus (PDA), a heart defect that occurs when one of the foetal blood vessels, the ductus arteriosus, does not close at birth. In this case, the PDA resolved at about 24 months with no treatment required.

One child had a ventricular septal defect (VSD). This is a hole in the wall between the two pumping chambers of the heart (ventricles). This allows blood to flow from the left to the right chamber, increasing the blood flow to the lungs. Treatment is determined individually. Small VSDs may close spontaneously; a larger VSD usually needs surgical repair to prevent lung problems that would develop from extra blood flow.

Another child had Tetralogy of Fallot. This is a complex heart condition involving both a VSD and an obstruction just below the valve in the artery that leads to the lungs. Blue (deoxygenated) blood cannot easily get to the lungs to pick up oxygen and some of it flows



## ■ Hands and Feet

Individuals with 17p13.1 and/or 17p13.2 microdeletions may have hands or feet that look different.

Four children are described as having small or shortened feet. Three children have long or large big toes and three have flat feet. Other features noted include short, curved fingernails (hyperconvex nails), inwardly bowing ankles and short fourth toes. One Unique child recently had surgery to loosen tight tendons, adjust the position of some bones in her feet and correct talipes (club foot or inward curving feet). Another required reconstruction (pollicisation) of the big toes. One child was described as having normal feet [Unique].

Two children had unusually positioned thumbs. These do not usually cause medical problems but in some cases do have an impact on functionality. Two children had unusual skin creases on the palms of their hands (palmar creases) and two children are described as having short hands. Two children tended to hold their hands raised and together in the midline. Other features reported include broad thumbs, webbed digits, long fingers, clinodactyly (curved finger), finger joint contracture (tightening of finger joint) and finger joint hyperlaxity (finger joint that stretches further than usual). One child had normal hands. [Krepischi-Santos 2009; Schluth-Bolard 2009; Shlien 2010; Zeesman 2012; Unique]

## ■ Spine

Spinal problems are noted in several children with 17p13.1 and/or 17p13.2 microdeletions.

Of the limited information available, three children were found to have sacral dimples (indentations in the skin of the lower back which usually do not cause issues but can occasionally be a sign of spinal problems). Two of these three children also had spinal problems. Two children suffered from sideways curvature of the spine (scoliosis). One Unique child with scoliosis has required a spinal brace. This child also has four extra distal sacral vertebrae or spinal bones in the lower back. Another child has mild spine curvature and an extra pair of ribs (13 instead of the usual 12) as well as partial fusion (sacralisation) of the lower lumbar spine. One child had a tethered cord (when the spinal cord is abnormally attached to the tissues around the spine) and needed corrective surgery at the age of three [Shlien 2010; Unique].

## ■ Breathing

Some children with 17p13.1 and/or 17p13.2 microdeletions can have problems with breathing and/or chest infections.

There is no information in the medical literature on breathing problems. However, from the information from Unique, three babies with 17p13.1 and/or 17p13.2 microdeletions experienced breathing difficulties after birth and of these, one baby required oxygen. In later life, there is information on six Unique children. Of these, half of the children (3/6) had had no breathing problems. Two children, however, were prone to chest infections. One of these, a seven year old child, had had recurrent chest infections, and was vulnerable to infection. He found it difficult to cough up mucus during infections due to muscle weakness. He took three or four nebulisers daily with saline [Unique].

The third child was prone to recurrent chest infections and had had pneumonia numerous times. She had also been diagnosed with asthma and needed hospitalisation and treatment, including nebulisers, for asthma-related symptoms [Unique].

Another Unique child had shallow breathing at night and also possibly had sleep apnoea

system). She is catheterised during the day [Zeesman 2012; Unique].

“Alfie cannot hold cutlery or a bottle – he can hold a cup with handles but does not have strength to hold to mouth.” 18 months

“She can use forks and spoons with little help. I put her snacks or favourite toys in various containers so she has to work on getting them out...She is in diapers. She tries to brush her teeth, brush her hair etc but we really need to do it for her. She can take off her shoes, pants and diaper but not her shirt or put anything on. Pretty much she mimics us and tries, but we need to redo everything.” 33 months.

“Lady Katie has poor coordination; at 36 months she is just now holding a half full bottle. She has a good grasp but weak muscles. She is still in diapers and cannot brush, dress or bathe. She used to fight getting dressed but at 28 months started helping.” 3 years.

“Penny still finds it hard to hold onto objects...she does struggle with coordination of her arms and hands...she is in nappies 24 hours a day and she cannot do any personal care for herself, she needs complete help.” 9 years

“Fine motor skills still delayed but getting stronger. She does not feed herself. She still wears diapers due to her neurogenic bladder” 9.5 years.

## Speech and communication

Almost all those with 17p13.1 and/or 17p13.2 microdeletions have a significant delay in language skills.

Two of the Unique children have acquired speech to varying extents: one child at two years and 10 months could say a few words, and also used gesturing and was beginning to link two or more signs together. Another child aged three could say a couple of words, and also used other sounds like grunting, as well as signing to a certain degree.

There are three Unique children who cannot yet form words. One child has some vocal sounds at 18 months old, and also uses some Makaton (a sign and symbol system to help people communicate). One child aged nine is non verbal, and uses signs and an electronic communication device. Another child aged nine communicates by vocal noises, as well as eye pointing, crying and becoming cross! In the published medical literature, six cases include details on speech. The oldest individual reported in the literature (aged 33 years) was non verbal, as was an eight and a half year old. There was also a two year old reported who had started to babble and a five year old with ‘limited speech development’. A seven year old could speak a few words and a 10 year old was described as having delayed receptive and expressive speech [Unique].

Of the Unique children, sign language and/or a picture exchange communication system (PECS) were useful tools for most, allowing them to communicate their needs.

Computer/phone-based Augmentative and Alternative Communication (AAC) devices were also used successfully by two children. One child was using the PEIC-D (Promoting Early Interactive Conversations-Dorset) intensive interaction therapy technique at school as well as some eye recognition/ eye following packages. Another parent bought a ‘baby signing’ DVD set which was found to be useful. Speech and language therapy (SALT) was found to be very helpful and was used by most families [Krepischi-Santos 2009; Schluth-Bolard 2009; Schwarzbrown 2009; Shlien 2010; Zeesman 2012; Unique].

There are many reasons for the speech delay, including the link between the ability to learn and the ability to speak. Those with a cleft or high palate may also have specific difficulty with producing certain sounds.

“ She uses sign language. She has been diagnosed with apraxia of speech [a speech disorder in which a person has difficulty saying what he or she wants to say correctly and consistently]. She uses gestures and a few words also...she is hard to understand if you don't spend time with her. 'Ommy' is Mommy, 'Ine' is mine etc...” 33 months

“ She can sign 'more' and 'enough' and says 'my momma' and 'dat-dat.’” 3 years.

“ Penny makes lots of single sounds, mainly 'd'. I have heard the word 'mum' about three or four times over the years. I bought Penny a Dora Explorer™ balloon and she said 'Dora:.’” 9 years

“ She is non verbal and uses signs and a communication device (Prentke Romich Springboard Lite).” 9.5 years.

## Learning

Learning difficulties are a common finding in children with 17p13.1 and/or 17p13.2 microdeletions.

One child has mild to moderate learning (intellectual) disabilities (with an IQ of 50-70), whereas five others are described as having moderate to severe learning difficulties (IQs below 50). Two children are described as having global developmental delay, and one as having mild developmental delay; these delays would include learning difficulties. A child with a learning difficulty is likely to need learning support. Many children benefit from attending a special educational school, sometimes from pre-school age or from primary or secondary level. Four Unique children are described as having good memories. Repetition, 1:1 assistance and music therapy are reported by parents to help children learn. Some areas of learning may be easier than others; reading and writing have proved very difficult in many children. Of the Unique children, one girl could scribble by two and a half years old. A nine and a half year old could write her name with help [Krepischi-Santos 2009; Schluth-Bolard 2009; Schwarzbraun 2009; Shlien 2010; Unique].

“ She has an excellent memory. As far as ABCs or 123s or shapes she really doesn't know any yet.” 33 months.

“ She has moderate to severe learning difficulties. Lady Katie's memory is excellent.” 3 years

“ School like the fact that if Penny doesn't want to do something she will let you know – become cross! She senses physiotherapists!” 9 years

“ Much stronger receptively than expressively, good memory, loves music...likes numbers...She is home schooled due to her weak immune system and receives twenty hours (per week) of special education.” 9.5 years

## Medical Concerns

### ■ Hearing

Some children with 17p13.1 and/or 17p13.2 microdeletions can have hearing or ear problems.

Of twelve children with 17p13.1 and/or 17p13.2 microdeletions, seven had no hearing or ear problems. One eleven year old child has had a perforated ear drum and wears a hearing aid. Another child was reported to have decreased hearing. Hearing impairment is of two types: sensorineural hearing loss and conductive hearing loss. Sensorineural

hearing loss occurs when there is damage to the inner ear or to the nerve pathways from the inner ear to the brain, resulting in permanent hearing loss. Conductive hearing loss occurs when sound is not conducted efficiently through the outer ear canal to the eardrum and the tiny bones of the middle ear. This type of hearing loss has a number of causes, including fluid in the middle ear (glue ear) or infections (otitis media). Glue ear usually resolves as children get older. Therefore, any hearing loss caused by glue ear is usually temporary. However, persistent fluid in the middle ear can reduce a child's hearing at a time that is critical for speech and language development. If glue ear persists, children may need a grommet, a small ventilation tube, inserted into the eardrum.

Three of the 17p13.1 and/or 17p13.2 microdeletion children have a tendency to have glue ear and/or middle ear infections. One child has conductive hearing loss secondary to chronic otitis media [Schluth-Bolard 2009; Shlien 2010; Zeesman 2012; Unique].

“ He has a strong tendency to middle ear infections (narrowed ear canals). We always give children's nose drops even for trivial infections. He also shouldn't get water in his ears.” 5.5 years

“ She used to get red ear/infections/glue ear regularly. Especially after swimming so she wore protective ear plugs and band. She has only had red ear once in about three years now.” 9 years.

### ■ Vision

Eye findings in individuals with 17p13.1 and/or 17p13.2 microdeletions are common.

The most frequently found eye finding (4/13) is strabismus (a squint) where one or both eyes can turn inwards, outwards or upwards. Several Unique children wore eye patches to treat their squints. Two children had astigmatism (an irregularity in the curvature of the front surface, or cornea, of the eye, which can cause blurred vision).

Other problems include hamartoma in the eye (a non-cancerous growth), iris hypoplasia (under-development of the coloured part of the eye), decreased lacrimation (reduced tear production), ptosis (drooping of eyelid), nystagmus (rapid uncontrolled eye movements), coloboma (a developmental defect in the structure of the eye), difference in the sizes of each eye, photophobia (intolerance to light) and exotropia (outward deviation of the eyes). Many children (7/13) had more than one eye finding

Some children experienced visual impairment. One three year old had cortical vision impairment (a visual problem caused by part of the brain, rather than the eyes, not working properly). A nine year old was legally blind and a six year old wears glasses. At 18 months, one child had severe visual impairment in both eyes.

Two children had hypermetropia (long sight) and two others had myopia (short sight). Two other children had lateral or peripheral visual difficulties. One child had no visual problems at two years 10 months of age. [Schluth-Bolard 2009; Schwarzbraun 2009; Shlien 2010; Zeesman 2012; Unique]

“ Alfie has a squint in his right eye and has to wear a patch for two hours a day.” 18 months

“ She is prone to blood shot eyes, especially in her left eye (she does sleep with her eyes open).” 9 years

