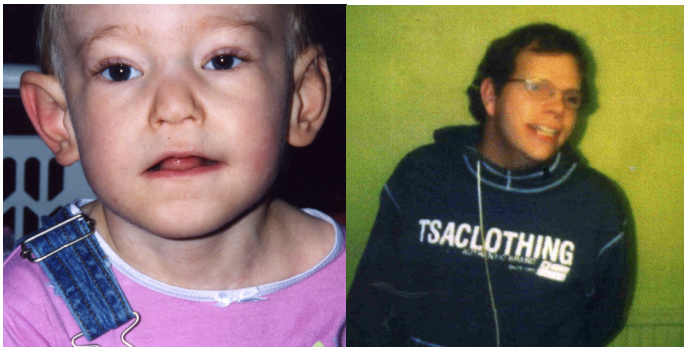

# Duplications of 16p



## Sources and references

The information in this leaflet is drawn partly from the published medical literature. The first-named author and publication date are given to allow you to look for the abstracts or original articles on the internet in PubMed. If you wish, you can obtain abstracts and articles from *Unique*.

The leaflet also draws on *Unique*'s database which contains regularly updated information that reveals how children and adults develop. When this leaflet was written, *Unique* had 16 members with a 16p duplication, of whom eight had a pure 16p duplication, without involvement of another chromosome.

(Brooks 2006; Sommer 2006; de Ravel 2005; Engelen 2002; Tschernigg 2002; Kokalj-Vokac 2000; Movahhedian 1998; Carrasco Juan 1997; Hebebrand 1994; Leonard 1992; Jalal 1989; Cohen 1983; Gabarron Llamas 1981; Dallapiccola 1979; Yunis 1977; *Unique*)

## Duplications of 16p

A chromosome 16 duplication is a rare condition in which there is an extra copy of part of the material that makes up one of the body's 46 chromosomes.

Like most other chromosome disorders, this can increase the risk of developmental delay and learning difficulties as well as birth defects. However, the problems that can develop depend very much on what genetic material has been duplicated.

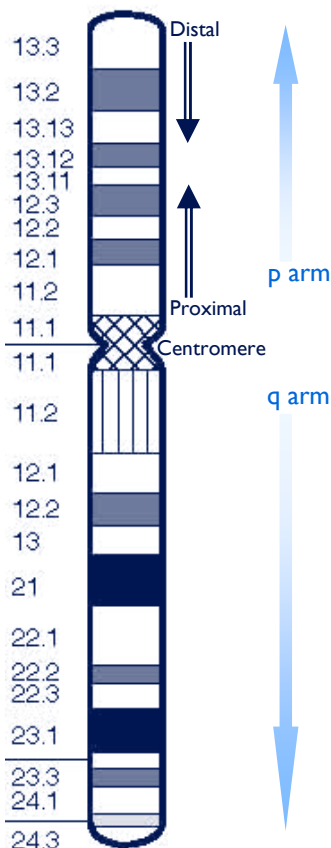
### What is a chromosome?

Chromosomes are the structures in the nucleus of the body's cells that carry genetic information, telling the body how to develop and function. They come in pairs, one from each parent, and are numbered 1 to 22 approximately from largest to smallest. Each chromosome has a short arm, called p, and a long arm, called q. A 16p duplication means that some material from the short arm of chromosome 16 has been duplicated.

You can't see chromosomes with the naked eye, but if you stain them and magnify them under a microscope, you can see that each one has a distinctive pattern of light and dark bands. You can see these bands in the diagram on the facing page. The bands are numbered outwards from the point where the short and long arms meet (the **centromere**).

A low number such as p11 is close to the centromere and the part of the arm that is fairly close to the centromere is called the **proximal** part. A higher number such as p13 is closer to the end of the chromosome, in the part referred to as **distal**.

Your geneticist or genetic counsellor will tell you more about how much chromosome material has been duplicated and where the duplication has occurred. You will almost certainly be given a **karyotype**, a shorthand notation for the image of your child's chromosomes, which will show any points where the chromosome has broken and rejoined. Comparing your child's karyotype with others, both in the medical literature and within *Unique*, will help to build up a general picture of what to expect from the duplication. But there will still be differences, sometimes quite marked, between your child and others with apparently similar karyotypes. It is very important to see your child as an individual and not to make direct comparisons with others with the same karyotype. After all, each one of us is unique.



**Chromosome 16**

## Some common features of a distal 16p duplication

- Very small head (microcephaly)
- Typical facial features that may change over time. These can include a round face that elongates; a small chin and lower jaw that becomes more prominent; low set ears; and widely spaced eyes
- Growth delay, sometimes starting before birth
- A degree of developmental delay
- A degree of learning disability
- Cleft palate and sometimes lip
- Heart condition at birth

## Features seen in duplications of 16p13.3pter

There appear to be great differences between individuals and these may relate to the precise breakpoints in the chromosome. Within *Unique* and in published cases, at one end of the spectrum there are no clinical problems, borderline learning difficulties and problems with social integration and behaviour. At the other end of the spectrum, the degree of learning disability is very much more severe, and neither walking nor talking have been achieved. In addition, there have been clinical problems including holes between the upper and lower chambers of the heart requiring surgical repair, a cleft palate, an umbilical hernia, clubbed feet, small genitalia, kidneys with cyst formation, seizures and blocked tear ducts (de Ravel 2005; *Unique*).

*“A hungry baby, he breastfed with no problems and although slightly short, is stocky and well-muscled. He has no particular clinical problems. Early development was on track and he walked at 11 months and toilet trained on time. However, his speech was delayed in comprehension which led to social difficulties, and in expression, although semantic therapy (working on the meaning of words) at 11 improved his understanding from a severe to a mild difficulty. He had problems with concentration at junior school and some learning delay but overall was of borderline ability”* - age 12, with a 16p13.3 duplication and a small deletion from the end of chromosome 18

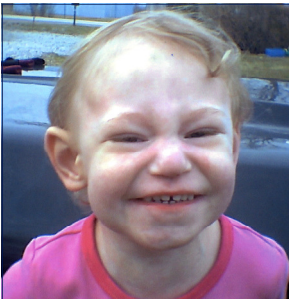*“She was initially tube-fed but had severe reflux (the stomach contents returned up the food passage), and since the age of one has been fed direct to the stomach through a gastrostomy tube. She is small, her growth always below the lowest line on the growth chart, and extremely thin except for the abdomen. In terms of development, she can sit up and shuffle a short distance but usually uses a wheelchair. Her learning disabilities are profound and complex but her strength is her personality. She loves interacting with faces and has a favourite toy, a reflecting mirror chime with bells. She has no behaviour problems at all”* - age 13

## Features seen in duplication of 16p13.1pter

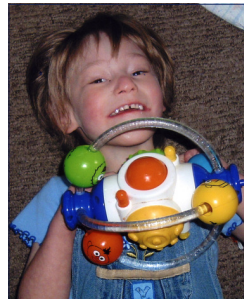There appear to be considerable differences between individuals that may relate to the precise breakpoints in the chromosome. Premature birth may be a common, though not universal feature.

At one end of the spectrum, there are mild to borderline learning difficulties, behaviour and social integration problems with autistic features and features of Tourette's syndrome, marked delay in mobility (walking from four years) and comparatively minor clinical problems including febrile convulsions, repeated infections, hernias of the umbilicus (navel, belly button) and groin (inguinal) as well as small genitalia and a tendency for the fingers and toes to turn blue.

At the other end of the spectrum heart defects have occurred including holes between the upper and lower chambers, and a persistent ductus arteriosus (a persisting feature of the fetal circulation); tracheomalacia (where the structural framework of the windpipe is abnormally soft and liable to collapse) needing a tracheostomy (trach tube, inserted into the windpipe to allow air and oxygen to reach the lungs); a cleft lip and palate and clubbed feet and hands. Kidneys with multiple cysts have been observed. Seizures have also been observed that may be hard to control and the level of learning disability can be severe to profound (Tschernigg 2002; Hebebrand 1994; Unique).



At 2.5 years



At 4.5 years

*“After a completely normal pregnancy, she had breathing difficulties at birth and was taken to the neonatal intensive care unit. The breathing difficulties were partly caused by her receding lower jaw which with her weak sucking also meant that she couldn't breastfeed. But she took expressed breast milk from a bottle and then soy formula. By the age of 4, she was drinking on her own from a cup and although very petite, was growing well. Clinically, she has a seizure disorder that is only reasonably controlled on medication. At birth a small hole was found between the lower chambers of the heart, but this closed spontaneously. She also wears hearing aids as she has a hearing loss in both ears. In terms of development, she started to walk when she was three and at four years old, walks short distances before choosing to crawl instead. Her gait is more unsteady when she is unwell; for distances, she uses a wheelchair. She can feed herself with her fingers and is learning to use a spoon. She has a wide repertoire of means of communication, including gestures, facial expressions and vocalisations and understands her own name. In terms of behaviour, she enjoys social interaction and likes to laugh and be with people she knows ” - age 4*

## Features seen in duplication of 16p13.3p13.1

Three children are known, with quite different concerns. In one, there were multiple heart defects that needed surgical repair. There were large holes between both upper and lower chambers of the heart and a persistent ductus arteriosus (PDA) that was closed surgically shortly after birth. Another child had no heart problems but did have developmental delay and learning difficulties. In addition to unusual facial features considered to be typical of 16p duplications, he had seizures and was small for his age. The third child also had seizures and developmental delay (Kokalj-Vokac 2000; *Unique*).

## Features seen in duplication of 16p13p11

*“ She is never unhappy unless she is unwell ”*

A baby and a child from the same extended family have been described with a large duplication of 16p13 to 16p11. One was born prematurely, the other at full term; both needed help to establish breathing at birth. As babies, the two had a number of minor anomalies in common. They had long, tapering fingers, unusually set thumbs and incurving fifth fingers. One of them also had partial webbing between two toes and slightly contracted elbows and hips. Other unusual features included an extra nipple, testicles that were undescended at birth and somewhat unusual facial features. Both children experienced a degree of developmental delay that was known to be severe in the child; by the age of seven, he had not yet developed speech or personal care skills. The child had seizures. He had a short attention span and was hyperactive.

A third baby was born small for dates after a premature birth at 36 weeks. He had heart defects (holes between the chambers of the heart) and raised blood pressure in the arteries that supply the lungs (pulmonary hypertension). He also had a diaphragmatic eventration (the contents of the abdomen are sited higher than normal within the chest cavity due to a thin, underdeveloped muscular wall) (Movahhedian 1998; Cohen 1983).

*Unique* has experience from three youngsters with a duplication of 16p13 p11, aged from one to 14 years, with a reasonable amount of detail on two. Both had a marked degree of reflux as young babies. This condition, where the stomach contents return up the food passage, is fairly common in babies with a chromosome disorder. Reflux raises a baby's risk of inhaling food contents and setting up an infection in the lungs known as aspiration pneumonia. Reflux can be eased by careful semi-upright positioning during and after feeds, sleeping in a prescribed sleep chair rather than a bed, raising the head end of the baby's cot and if necessary by prescribed medication that helps to keep the feed within the stomach and counteract any acidity. Babies who have continuing problems can have a surgical procedure called a fundoplication to improve the action of the valve at the junction of the food pipe and stomach. In this procedure, the top of the stomach is wrapped around the bottom of the oesophagus and stitched in place. At the same time the hole in the diaphragm through which the oesophagus passes is tightened. Where feeding and reflux problems are persistent, a gastrostomy tube (PEG, button) can be inserted to allow direct feeding into the stomach until the baby is sufficiently mature to tolerate feeding by mouth.

Both children have also developed a seizure disorder. In one baby, sorting out the reflux appeared to lead to control of the seizures and in the other the seizures, which

had first appeared in the neonatal period, were outgrown at the age of 10.

In other respects, the children appeared to be quite differently affected. One had no further clinical problems apart from a tongue tie that was cut at the age of four weeks. In terms of medical problems, the other baby had to be repeatedly resuscitated at birth and was ventilated for three days. She had a cleft palate (surgically repaired at one year) and talipes (club foot), also corrected surgically. She was born with a dislocated hip and developed a spinal curvature requiring a brace for correction and insertion of rods to straighten the spine at the age of eight. Because of the cleft palate, feeding as a baby was difficult, but she took expressed breast milk for five months from a Habermann feeder. At the age of 10, she still had feeding issues, taking only pureed food and needing to be fed by nasogastric tube when seriously ill. She was small for her age, both short and light and this was evident from the start.

In terms of development, she had very marked delay, needing a wheelchair to move around, and could only hold something like a xylophone beater for a short while. She could not hold cutlery, although she could pick up small objects. As a baby her hands were held in fists and as splints distressed her, these were abandoned. These difficulties meant that she was dependent on others for her personal care. At 10 years, she was not yet toilet trained.

She communicated using vocal noises, facial expressions, laughter and crying as well as a few single words and needed extensive help with her learning, although she had a good long term memory for people and games. She had no behaviour problems, enjoyed being 1:1 with adults and banging noisy instruments.

### Features seen in duplication of the complete arm

Where all or almost all of the short arm of chromosome 16 is duplicated, features tend to be obvious and severe. The common features have been considered to be a low birth weight; a remarkably small head (microcephaly); sparse growth of hair, eyebrows and lashes, a tiny nose, an overhanging upper lip, abnormalities of the arms and legs, heart defects and neurological deficits. Where babies have not survived, most have died of respiratory distress. Developmental delay and learning difficulties have tended to be severe. Seizures have occurred in at least half of all babies.

One baby has been described with a cluster of birth anomalies, including a cleft palate, abnormal lungs and ovaries and abnormalities of the drainage system from the kidneys. In addition, the baby had numerous minor anomalies including loose skin on her neck and back, clubbed hands with unusually sited thumbs and clubbed feet. Another baby with no major physical anomalies had repeated seizures as a newborn. Her unusual foot angle (pronate valgus) was surgically repaired. She was small for her age and showed a marked degree of developmental delay (Leonard 1992; Jalal 1989; Gabarron Llamas 1981; Dallapiccola 1979; Yunis 1977).

### Features seen in proximal duplication of 16p12p11.2

It is believed that proximal duplications do not typically cause severe medical problems, but they do imply a level of developmental delay and learning difficulty and may be associated with particular facial features including widely spaced, narrow eyes, a low nasal bridge and a long groove between the nose and the mouth.

A 40-year-old mother and her 6-year-old daughter who each have a small proximal duplication of 16p have been described. While the mother experienced some learning, social and behaviour difficulties and had a patchy employment record, her difficulties were not severe. She did have emotional difficulties, being 'emotionally flat', as well as problems with attention and concentration and developed an anxiety disorder. She had no particular medical problems. She was not able to care for her daughter, who was of borderline ability and showed some behaviour and developmental difficulties from the age of 2. When the child had a structured programme for her day, her behaviour improved.

A boy of 23 months has also been described with moderate developmental delay, low muscle tone in the abdomen with normal tone in the limbs, repeated episodes of bronchitis, feeding difficulties and episodes of tremor when his eyes revolved but he did not lose consciousness. Epilepsy was not confirmed but some behaviour difficulties were noted resembling an autistic disorder. He also had a cleft palate (Engelen 2002; Carrasco Juan 1997).

## Duplications of 16p with no apparent effect

### Natural (euchromatic) variants

Some people who appear to have extra 16p material close to the centromere are healthy, develop normally and have healthy children. In these families, what looks at first sight like a duplication has turned out on closer molecular genetic analysis to be harmless copy number variation of a short stretch of DNA within band 16p11.2. The stretch of DNA that is duplicated only contains pseudogenes, fossilised and now non-functional relics of evolution. People with high copy numbers are healthy and develop normally and the unusual chromosome findings usually come to light by chance.

### How did this happen?

Chromosome conditions are usually passed down in the sperm and egg cells. This is part of a natural process and as a parent there is nothing you can do to control it. Children from all parts of the world and from all types of background have chromosome 16p duplications. No environmental, dietary or lifestyle factors are known to cause them. So there is nothing you did before you were pregnant or during pregnancy that caused this to occur and there is nothing you could have done to prevent it.

A chromosome 16p duplication can occur as a result of rearrangements in one of the parents' chromosomes or it can happen out of the blue. It is then called a *de novo* (dn) rearrangement. A blood test to check the parents' chromosomes will show this.

If the check reveals a structural rearrangement of one of the parents' own chromosomes, this is usually balanced so that all the chromosome material is present, and the parent is then almost always healthy.

### Can it happen again?

Where both parents have normal chromosomes, it is unlikely that another child will be born with a 16p duplication. Where a parent has a rearrangement of their chromosomes, the risk of having another affected child is higher. Your geneticist or genetic counsellor will be able to advise on the particular situation in your family.



## Support and Information



### **Rare Chromosome Disorder Support Group,**

G1, The Stables, Station Road West, Oxted, Surrey RH8 9EE, United Kingdom

Tel/Fax: +44(0)1883 723356

[info@rarechromo.org](mailto:info@rarechromo.org) | [www.rarechromo.org](http://www.rarechromo.org)

Join Unique for family links, information and support.

Unique is a charity without government funding, existing entirely on donations and grants. If you can, please make a donation via our website at [www.rarechromo.org](http://www.rarechromo.org) Please help us to help you!

This information guide is not a substitute for personal medical advice. Families should consult a medically qualified clinician in all matters relating to genetic diagnosis, management and health. Information on genetic changes is a very fast-moving field and while the information in this guide is believed to be the best available at the time of publication, some facts may later change. Unique does its best to keep abreast of changing information and to review its published guides as needed. The guide was compiled by Unique and reviewed by Professor Anne-Marie Sommer, emeritus professor of paediatrics, Ohio State University College of Medicine, USA, and by Professor Maj Hultén BSc PhD MD FRCPath, Professor of Reproductive Genetics, University of Warwick, UK 2006. (PM)

Copyright © Unique 2007

Rare Chromosome Disorder Support Group Charity Number 1110661

Registered in England and Wales Company Number 5460413