

Trisomy 14 mosaicism



Mosaic trisomy 14

Mosaic trisomy 14 (T14M) is a very rare chromosome disorder in which some cells in the body have too many chromosomes or too much chromosome material. There are usually 46 chromosomes in a cell. In a person with mosaic trisomy 14, some cells have one extra chromosome (47 in all) or one extra part of a chromosome. Chromosomes are numbered from 1 to 22, and the extra material is from chromosome number 14.

Chromosomes contain the genes that direct health and development. For normal development, there should be just the right amount of chromosome material: not too much and not too little. The extra chromosome material (**trisomy**) means that there is too much genetic material - but the **mosaicism** (the presence of cells with 46 chromosomes as well) lessens the impact.

The effects of any chromosome disorder can vary a lot and mosaicism makes the effects even more variable, so it can be hard to predict the effects and their obviousness or severity on an individual baby, child or adult. Nonetheless, certain features are common in people with mosaic trisomy 14 and this leaflet describes them.

Sources & references

This leaflet describes what is known from published medical research and from the experience of *Unique*. The first named author and date of publication of medical research are given to allow you to look for articles in PubMed. Twenty-seven babies and children have been described in the medical literature by 2008, the oldest 13 years old. In 2008, *Unique* had 14 affected member families, the oldest 22 years old.

Finding out

Chromosome disorders are usually detected by examining cells prepared from a blood sample under a powerful microscope. In T14M, cells from a skin sample may also be taken. A number of cells are analysed and a report prepared, giving the **karyotype**, a chromosome description. Recently microarray technology has been used to detect low levels of mosaic trisomy 14 (Shinawi 2008). The wider application of this technology is predicted to increase significantly the detection of low level mosaicism (mosaicism with only a small proportion of T14M cells) and the ability to diagnose more people.

Karyotypes for the three most likely types of T14M might look like this:

1: A boy or man with an entire extra chromosome 14 (mosaic)
47,XY,+14[26]/46,XY[24]

2: A girl or woman with an extra part of chromosome 14 (mosaic)
46,XX,t(13q;14q)[73]/47,XX,t(13q;14q),+14[27]

Here the long arm of chromosome 14 has joined with the long arm of chromosome 13.

3: A boy or man with idic 14 (mosaic)
46,XY[23]/46,XY,-14,+i(14q)[7]

For an explanation of how each of these types of T14M can arise, see pages 13-14

The karyotype usually shows the proportion of cells with 46 and 47 chromosomes in square brackets. However, there is no obvious link between the proportion of cells with the extra chromosome in a blood sample and the severity of the disorder.

One explanation for this can be that the degree of mosaicism detected in blood does not reflect the level of mosaicism in other tissues.

Most likely features of T14M

- Short stature and failure to thrive
- Some degree of developmental delay. This can affect mobility, learning and speech and communication or just one of these areas
- Slightly asymmetrical growth
- Abnormal skin pigmentation
- A heart condition at birth
- Minor anomalies of the genitals in boys, such as undescended testicles.
Girls generally do not have genital or urinary abnormalities
- Unusual facial appearance

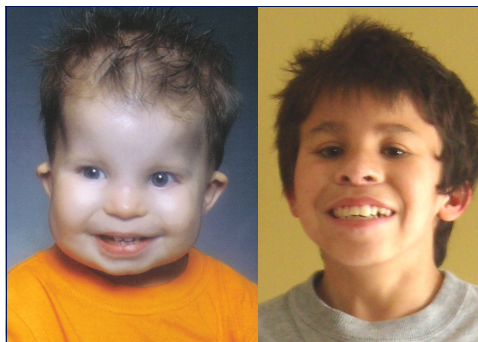
Will my baby or child look different?

You and the doctors may notice that your baby has a slightly unusual facial appearance. He or she may look more like the other babies and children with trisomy 14 mosaicism in this leaflet than like your family. Young babies often have a high or rounded forehead, eyes that are set wide apart, unusually formed ears that may be set low on the side of the head, a broad, upturned nose, a small chin and lower jaw that may be set back from the upper jaw and a short neck. Some children with T14M have a cleft (split) or other unusual formation of the palate (the roof of the mouth). Some children have skinfolds across the inner corner of one or both eyes (epicanthic folds), narrow openings for the eyes and a large mouth. Everyone's face is slightly asymmetrical but this may be more obvious in a child with trisomy 14 mosaicism.

Looking at the body, you may notice that your baby's chest is unusually narrow. In many cases, this is not obvious to parents but may be noticed by doctors.

“As he has grown, he is starting to look more and more like the rest of the family - 14 years

A few babies are born with a film over their eyes which resolves naturally in time. Some have everted lower eyelids or eyelids that do not close when asleep; the lower eyelids are also affected in other babies with small amounts of extra material from chromosome 14. A surgical operation can be carried out to ensure the eyes do close fully (Shinawi 2008; Witters 2004; Dallapiccola 1984; Martin 1977; *Unique*).



13 months

14 years

Will my baby be healthy?

Some babies with mosaic trisomy 14 are healthy and overcome the typical infections of early childhood to grow into healthy, if small, children. Other babies have feeding difficulties and have difficulty thriving despite feeding adequately. Others have repeated episodes of ill health with respiratory tract infections and breathing difficulties. Many babies have a heart condition and while the baby usually either outgrows this or it is successfully corrected by surgery, a small number of babies have in the past not survived. As surgical techniques are refined, the outlook for babies with a heart condition is improving (Sepulveda 1998; Cheung 1988; Turleau 1980; *Unique*).

What about food and eating?

Feeding and eating problems occur in some babies and children, but not all. Some babies milk feed successfully and move on to solids without difficulties, although underlying facial hypotonia may make babies reluctant to chew and prefer puréed food. Moving on to solid and more complex foods often occurs later than in typically developing children but by school age some children are feeding themselves. In other babies, initial feeding problems occur and babies may suck weakly or have difficulty coordinating sucking with swallowing and breathing.

Babies with additional clinical problems such as a cleft palate or a heart condition need specific support with feeding and may need to be fed by nasogastric or gastrostomy (direct-to-stomach) tube for some time; babies recently reported in the medical literature are very much more likely to have needed a gastrostomy than *Unique* babies. The small weight gain and slow growth that are typical of trisomy 14 mosaicism make failure to thrive more likely and tube feeding will probably be started to ensure that the baby is taking in enough nutrients for adequate growth.

Gastro-oesophageal reflux and vomiting are common, with a risk of aspiration pneumonia. Careful feeding, using feed thickeners and medications prescribed to inhibit gastric acid have controlled reflux in most *Unique* babies. If not, an operation called a fundoplication can improve the function of the valve from the stomach to the food passage. Constipation is common in children with chromosome disorders and occurs in this group but has been successfully treated with stool softeners and stimulants.

A feeding or speech therapist will help in finding ways to feed babies with unusual tongue activity and those with a high or cleft palate. One advantage is that the oral stimulation phase lasts longer than in other children (Shinawi 2008; Lynch 2004; *Unique*).

“ He is eating fairly well as long as his food is well mashed and in little pieces. He eats more and in greater variety since his tonsils were taken out – 4 years

“ Her partial cleft soft palate has made her a very picky eater bothered by different textures of food like mashed potatoes or pasta or anything that could get stuck to the roof of her mouth – 5 years

“ Feeding my infant was brutal for both of us. He cried because he was hungry every hour on the hour. When he could drink it took him half an hour to drink a few ounces. Sometimes he could not drink from the bottle because his little nose was so clogged. On at least two occasions, I rushed him to the hospital because he was turning blue. We were finally given albuterol (a bronchodilator) and a nebuliser to help his breathing. To this day, he's still a mouth breather but no longer needs the nebuliser – 14 years

“ He does not eat food. His diet consists of Ovaltine with milk twice daily; two wheat biscuits and mashed potato with melted cheese once daily and a nutritional supplement four times daily. He vomits or gags if offered other foods or liquids but the reason is considered likely to be behavioural rather than medical – 22 years

Is there a typical growth pattern?

Many babies are small at birth, with a range of birth weights at term in the medical literature from 2.025 to 3.6 kg (4lb 7oz to 7lb 15oz) and a very similar range within *Unique*, at 2.154-3.32 kg (4lb 12oz to 7lb 5oz). Growth in babies and children is then consistently slow, with average heights near the lowest curve on growth charts.

In early childhood, the difference will not be too obvious but by secondary school age, it will be more marked. A four-year-old boy was as tall as an average three-year-old; a girl of six as tall as a typical girl of 4½; and a boy of 14 was the height of an eight-year-old.

So far there is no evidence that children with T14M are short of growth hormone, but some children receive growth hormone treatment. We do not yet know what difference this makes to their adult height but it is an option to discuss with your child's paediatrician or endocrinologist.

Data from *Unique* show that children are usually slim, although their weight is typically slightly higher on the growth chart than their height.



Almost 15 years old (right) with 15-year-old friend

Some children show uneven growth on each side of the body, although this is not often obvious in the first weeks of life and may not be noticed until the early school years. It is presumed that the smaller side of the body has more trisomic cells (with 47 chromosomes), while the larger side has more cells with 46 chromosomes. If this could potentially affect functioning (walking, for instance, or the development of a spinal curvature), your child will be very carefully monitored and if necessary the options for limb lengthening or stopping the growth in one limb to achieve similar leg lengths will be discussed with you (Shinawi 2008; Lynch 2004; Sepulveda 1998; *Unique*).

How will a child's ability to learn be affected?

It is very hard to predict the effect of T14M on a child's learning. It seems that most children will need learning support, although the amount of help they need varies. Generally children benefit from early intervention programmes and from attending special pre-schools and schools where their individual needs can be met properly.

All the same, there are some children attending mainstream (regular) pre-schools and elementary schools without support. In common with others with a similar level of learning ability, children with T14M may well be late to show interest or curiosity in their surroundings, have a very short attention span and require longer than normal to process information and project a response.

The information available at present suggests a range of learning disability, with some children not reading or writing and communicating most of their needs non-verbally, while others progress faster and further. Although published developmental and intelligence quotients (IQ) have been around 40–50, some children seem to be more mildly affected (Shinawi 2008; *Unique*).

“ He is easily distracted and although he is not yet reading, he is starting to write his own name and draws like any 5-year-old. He attends a special school for the deaf where he receives amazing support – 5 years

“ He has been diagnosed as learning disabled and I would say the disability is moderate. His reading and writing levels are way below his age level; he more recognises words by the position of letters in relation to each other than actually reading. He also recognises the names of baseball players and racing drivers he sees in print but cannot read phonetically. He has memorised our phone number and address and is currently working on money and time. He gets distracted very easily in and out of school. For example, in the grocery store, he'll be choosing his favourite cereal and suddenly hear a baby crying in the next aisle. He will drop everything and go and find the crying baby. At his baseball games, he often misses the pitch because he is more interested in making sure Mom, Dad and Sis are watching him and that they see him hit and cheer him on. And heaven forbid someone move their seat. In addition to reading his own name and information, he can also read sight words like Mom, Dad, exit, girls, boys, yes, no etc. He can also read the names of his favorite sports figures and makes of cars. He writes his name and can copy letters and numbers. He attends a special education program in a classroom with eight kids, one teacher and one aide – 14 years

How can communication be affected?

Communication skills are typically delayed, so first smiles arrive late. Babies communicate their needs by crying, facial expression and, as they mature, by gestures, intonation, vocal noises and approximations. Recognisable sounds or words may emerge in some children in the second year, but they may come much later and in some children may possibly not emerge at all. By two or three years, children may be babbling and communicating with a variety of vocal noises as well as by gestures and words.

Children may well understand more than they can express, especially when they are given maximum help using focused attention, few words in a phrase, body language and physical manipulation. This means that even in children who do not talk, receptive language allows communication using speech.

Where needed, children can learn a useful word signing vocabulary and may develop the ability to link signed words. In *Unique's* experience, children can then make the transition to speech and some children become fluent communicators in speech. Generally, language development is in line with learning ability, except where a child

also has a hearing loss. *Unique's* experience is that in two children speech development was in line with actual (chronological) age, while in the others there was language delay (*Unique*).

“ She expresses herself by talking and signing, using phrases from three to six or seven words. Her grammar is like a slightly younger child's, so she will say *Mum get me* instead of *Mum will come to pick me up later*. Her speech is still a little hard to understand and she is used to working hard to be understood, so it doesn't bother her to ask for something many hundreds of times – 3 years

“ He picked up sign language very well but the family encourages him to speak as much as possible. He babbles a lot and can say two words together (now working on 3-4 words but with a lot of prompting as his memory span is very short). His vocabulary is about 50-70 words – 4 years

“ He could speak at a very young age and now uses full sentences and speaks well using 'normal' grammar, although his speech is sometimes hard to understand – 14 years

“ He talks and uses normal grammar but has difficulty saying some words – 22 years

Sitting, moving: gross motor skills

Time will tell whether your child's mobility skills will be delayed. Most children do have some delay but others reach their baby milestones of rolling, sitting and walking at the same age as other typically developing children. How much an individual child will be delayed is hard to predict but is affected by hypotonia (low muscle tone, evident as unusual floppiness in a baby) and in some cases by any discrepancy in leg length. Some children need persistence, practice, physiotherapy and specialised stimulation and exercise programmes to achieve their goals but the medical literature and *Unique* reports show that all children are walking by school age and many start walking alone without support in their second year (Shinawi 2008; *Unique*).

Babies learn to roll over at any age from six months and soon become able to sit alone. *Unique* reports show that this is generally achieved in the second half of the first year although slower-developing children may not sit until much later. Some children become mobile by conventional crawling, others by commando crawling (creeping) or bottom shuffling (scooting) and others by rolling over and over; *Unique* children generally became mobile soon after their first birthday, but this can be delayed by a year or so. First supported or unsupported steps may be possible from as early as 18 months or shortly before or else emerge later and may follow persistent practice. Generally speaking, early rolling and sitting is followed by early mobility and walking, and while a slower-developing child will eventually become fully mobile, he will take longer to do so.

Problems with balance can persist, particularly for those children with a leg length discrepancy that becomes more evident with time. All the same, skills such as climbing stairs are possible and some children achieve running and even sporting activity. In general, problems with hypotonia lessen once children are mobile, but continued physiotherapy is helpful.

“ Asymmetric growth means that he now stumbles about due to the unevenness of his legs. Apart from this, he moves around like any other child but probably in slower mode – 4 years

“ At 14 years old, he sits, walks, and climbs stairs with caution. He has not mastered the two-wheeler as yet though. The physical therapist at his school has said that the reason he walks almost flatfooted instead of heel-toe, heel-toe is because one leg is slightly longer than the other

“ He is unable to walk for long and has to stop often because he has restricted movement and gets pains in his hips and legs. He also gets a rumbling sensation in his thighs and the pain can last a long time. He wears a shoe raise to compensate for the one centimetre difference in his leg lengths – 22 years

Medical concerns

■ A heart condition at birth

Many babies are born with a structural problem with their heart, so all babies and children can expect to be evaluated. In general, babies with a heart condition will have significantly more ill health until their problem has been corrected than those born with a healthy heart. In some cases, the problem will resolve in time or it can be corrected using minimally invasive surgery. More complex problems call for open heart surgery.

The most common problems are holes between the upper or lower chambers of the heart (atrial septal defects or ASDs between the upper chambers and ventricular septal defects or VSDs between the lower chambers) and sometimes between both. Another common problem is narrowing of the blood vessels leading away from the heart (known as pulmonary stenosis when the pulmonary artery taking blood to the lungs is affected). Persistent ductus arteriosus (PDA), where a channel between the aorta and the pulmonary artery stays open instead of closing after birth has been seen. More complex conditions include Fallot's tetralogy which involves both a hole between the two lower heart chambers and a narrow entrance to the vessel that takes blood to the lungs (pulmonary stenosis). Blood is diverted through the VSD to the aorta, reducing circulation to the lungs so the child appears blue. Another complex condition seen more rarely is atrioventricular canal, which consists of a hole at the centre of the heart where the walls between the lower chambers meet the walls between the upper chambers. Both conditions can be corrected by surgery (Shinawi 2008; *Unique*).

■ Minor genital anomalies in boys

It is common for boys with chromosome disorders to have minor genital anomalies at birth. These are usually easily correctable and then should have no long-term consequences. Genital anomalies in girls are much less common. Almost all boys with mosaic trisomy 14 have undescended testicles (cryptorchidism) where one or both testes have not completed their natural descent from the abdomen into the scrotum before birth. If the testes do not come down spontaneously, they are brought down and anchored in the scrotum in a surgical operation. Other male genital anomalies have not been seen in *Unique* cases but have been described in the medical literature. They include hypospadias, where the hole is on the underside of the penis rather than at the end. Some boys do not need corrective surgery but an operation may be needed if the hole is a long way from the end of the penis. The opposite and much rarer condition - epispadias, where the hole is

on the upper side, has also been seen, as has a very small penis (micropenis) and in one case a very small scrotum (Shinawi 2008; Vachvanichsanong 1991; *Unique*).

■ Urinary tract and kidneys

Most children have a healthy urinary tract and kidneys that work well, although imaging may reveal that one kidney is larger than the other. In a small minority of children a concern has arisen, but this does not occur frequently enough for children to have their renal and urinary tracts routinely imaged. Conditions reported include hydronephrosis (enlarged kidneys) for which there are many causes, including a blockage in urine drainage, renal insufficiency (not defined), renal cysts, and a missing kidney (Shinawi 2008; Lynch 2004; Cheung 1988; Turleau 1980).

■ Breathing and respiratory infections

While many babies with trisomy 14 mosaicism have normal breathing and no more respiratory infections than any other young child, others have distinct respiratory difficulties as babies and young children. Many babies with T14M will need mechanical support to breathe after delivery (Shinawi 2008). There are many reasons for this and some interplay between the causes. From birth, some babies have an unusually soft, flexible structure to the windpipe (tracheomalacia) that makes it liable to collapse. Unco-ordinated sucking and swallowing may lead young babies to inhale part of their feeds, putting them at risk of aspiration pneumonia. Additionally, babies with a heart condition may become breathless and their lungs may need to work abnormally hard. At least one baby with trisomy 14 mosaicism had an abnormal lung structure with more lobes than usual and in another the epiglottis was found to be blocking the airway and was remodelled with laser surgery. When a baby or child catches an infection, these factors acting together may make it harder for him to get over it.

Three babies have needed long-term oxygen and the insertion of a tube direct into the trachea (windpipe) to support their breathing, and a fourth was unable to maintain his oxygen levels at six months and died.

There is no evidence that babies and children with trisomy 14 mosaicism have any less defence against infection than other children. But viral infections such as bronchiolitis can cause greater breathing difficulties than in children with normal chromosomes and leave a child prone to wheezing, which can be treated with asthma medications. With modern medical care, the great majority of children recover fully from the respiratory infections of early childhood and outgrow their respiratory problems (Shinawi 2008; Lynch 2004; Lambert 1994; *Unique*).

■ Brain

Some babies have a disproportionately small head (microcephaly). Recently a small number of babies and children with trisomy 14 mosaicism have had CT or MRI imaging to investigate any structural abnormalities of the brain. In three children the olfactory bulbs, which transmit smell information from the nose to the brain, were missing, and in one of the band of nerve fibres through which the two sides of the brain communicate with each other was thought to be missing. One baby had a failure of the forebrain to separate into two distinct halves (holoprosencephaly) and another had a Dandy-Walker anomaly, an anomaly affecting the cerebellum, the area at the back and

base of the brain. This child experienced seizures as did another with an unusual mottling pattern of brain matter and a further child with normal brain imaging. Among the *Unique* group, no children experienced seizures and among those who had brain imaging, the outcome was normal (Shinawi 2008; Lynch 2004; Tunca 2000; Sepulveda 1998; Lipson 1987; Dallapiccola 1984; *Unique*).

■ Cysts

Cysts have been found in three *Unique* children. In one, there was a hair-filled cyst in the nasal cavity that was removed; a second child had a thyroglossal duct cyst, a mass or lump in the neck that remains after the thyroid gland has formed during embryonic development; a third had a ganglion cyst (a mass that develops around a joint when tissues become inflamed and swell up) on one ankle. One patient underwent a surgical removal of a mass under the columella (the central lower portion of the nose which divides the nostrils) that was found to be a fibrotic mass surrounded by inflammation (Shinawi, personal communication).

■ Other concerns

Other conditions have been found in the *Unique* series or in children described in the medical literature but may not be typical of children with mosaic trisomy 14: congenital diaphragmatic hernia (hole in the muscular wall separating the heart and lungs from the contents of the abdomen. Part of the bowel, stomach or liver take up space in the chest, potentially depriving the lungs and heart of room to develop properly, usually reparable by surgery); allergies; umbilical hernia (an abnormal bulge that can be seen or felt at the umbilicus (navel or belly button). The hernia develops when a small opening in the abdominal muscles that allows the umbilical cord to pass through does not close after birth); hypothyroidism; and cholestasis (flow of bile from the liver is reduced or stopped) as a newborn (Shinawi 2008; Johnson 1979; Réthoré 1975; *Unique*).

■ Skin

Some children with mosaic chromosome disorders have patches of light or dark skin. Among those with trisomy 14 mosaicism, the areas are of slightly darker skin and tend to appear after babyhood either in a lacy pattern over part of the body or in a zebra stripe pattern known as Blaschko's lines. These areas of darker skin are harmless; if a child has significant areas of lighter skin, it is sensible to use a higher factor sunscreen to protect these areas carefully from bright sunlight in the summer (Shinawi 2008; *Unique*).

■ Hands and feet

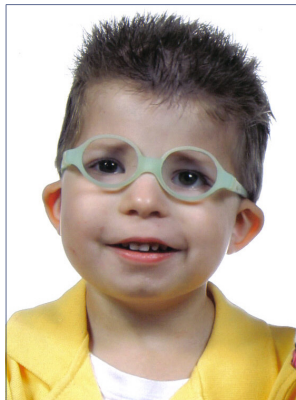Slightly unusual features of the hands and feet are common in children with chromosome disorders. In children with trisomy 14 mosaicism, the most serious problem that is seen occasionally is talipes (club foot), where the baby is born with one or both feet held at an unusual angle. Treatment with regular stretching and repositioning may be sufficient but if not, splinting, casting and sometimes surgery may be needed to achieve the best possible position for walking. Long term outcomes of treatment for talipes in this group of children are not known but one *Unique* child whose talipes was severe enough to need surgery was walking by 18 months.

Unusual features of the hands do not normally affect function, so treatment would not be needed. The most common observations are incurved fifth fingers, a single crease

across the palm and hands that stay clenched for longer than usual in a baby. Overlapping fingers and toes have been seen occasionally; these may correct themselves in time but if they do not, a soft splint is usually enough for the toes or fingers to assume a more normal position.

A wide range of other anomalies has been observed, including short or long fingers, small hands, small nails, short bones in the hand, slight toe webbing and small toes.

■ Eyesight



Most children appear to have normal vision. Three babies were born with a clouding of the cornea, the usually transparent front of the eyeball, but the clouding resolved naturally within or soon after the baby's first year. Some babies were born with everted lower eyelids or with eyes that do not close during sleep (see [Will my baby or child look different?](#)).

Some children have a degree of visual impairment despite having structurally normal eyes. This is known as cortical visual impairment, a condition in which the visual systems in the brain do not understand or interpret what the eyes see. As a parent you may notice that your baby is not visually responsive either to you or to lights or moving objects. Strabismus (a squint) is also fairly

common and may be attributable to the underlying muscular hypotonia. This can be corrected surgically but may recur. Other children are longsighted and will need to wear glasses for correction. One child was found to have cataracts; these can be removed surgically to restore vision. In some children there is a difference in size and function between the eyes (Shinawi 2008; Turleau 1980; *Unique*).

■ Hearing

Children are at increased risk of a permanent or temporary hearing impairment. Where a baby fails a newborn hearing screening test, a permanent loss is more likely. As children are also vulnerable to upper respiratory tract and ear infections, they may additionally have a conductive hearing loss that can be relieved by placing grommets (aeration tubes) in the eardrum. If this measure does not improve hearing to useful levels, hearing aids should be considered.

Two children, one in the literature and one from *Unique*, had a hearing impairment in one ear and a very narrow external ear canal on that side. In two children there was malformation of the structures in the inner ear resulting in a permanent hearing loss (Shinawi 2008; Lynch 2004; Jenkins 1980; *Unique*).

■ Teeth

Children with chromosome disorders have a high rate of dental anomalies and frequently need specialist treatment. No typical pattern of anomalies has emerged in children with mosaic trisomy 14 but among the problems noted are natal teeth (visible teeth at birth); widely spaced, abnormally formed teeth; poor enamel formation of front teeth; small, conical teeth; and missing teeth (Shinawi 2008; Lynch 2004; Fujimoto 1985; Petersen 1985).

Behaviour

There has been no formal study of behaviour in children with mosaic trisomy 14 and the observations of *Unique* families suggest that there is no single typical pattern. Children are generally described as happy, relaxed, sociable and outgoing. Problems including easy distractibility, attention-seeking and obsessive-compulsive disorders (OCD) occur as they do in other children with a similar level of learning disability and should be addressed early with professional support for families (*Unique*).

“ She behaves like a normal 3 year old girl

“ He has just been diagnosed with Asperger’s syndrome and more recently with OCD so we try not to change his routine. He does not interact socially very well and does not like crowds or noise. He has four dogs so loves animals – 4 years

“ Very happy. She loves people and school. No real behaviour problems. She is a very loving little girl – 6 years

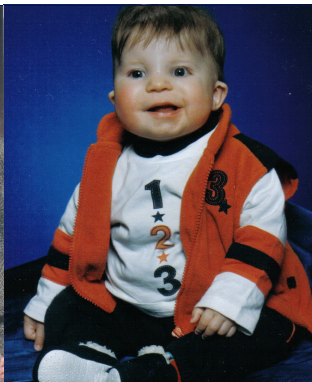“ He is eager to start his day. He wakens and gets out of bed easily and heads to the breakfast table. That’s where it starts to get tough. He fights getting dressed and ready for the bus but once he is on the bus, he has been described as pleasant and friendly by school bus drivers and teachers. After school he waits for Mom and Dad to come home from work at the front window and runs to get the first hug. Everyone loves him and he loves everyone. He does tend to be overly friendly and will start a conversation with strangers in stores and offer to shake hands and introduce himself. In fact he loves to be the centre of attention. He is extremely special. He even likes to play jokes on people. He especially likes to pretend to shake hands with someone and then at the last moment pull his hand back and say, ‘Psych!’ He gets a big laugh every time! Except when he tries the same thing with the same person five minutes later – 14 years

“ He is very sociable and loves being the centre of attention. He always offers help or assistance to others less able than himself but he needs guidelines and boundaries or he will try to make others laugh, especially children, who then start hitting him. He is such a likeable person, very hard work but worth it! He has got such a big heart, always smiles and never grumbles about his inabilities – 22 years

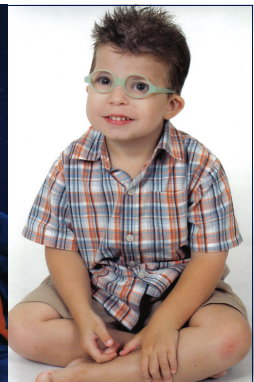Growing up with mosaic trisomy 14



6 months



9 months



4 years

How did the trisomy 14 happen? Three possibilities

Full trisomy 14 can arise in three completely different situations but the effects on a baby and child are similar. The actual cause of the trisomy is often not known and is best regarded as an accident that happened in cell division in the process of making sperm or egg cells. Trisomies, like other chromosome disorders, affect children from all parts of the world and from all types of background. There is no reason to suggest that your lifestyle or anything that you did caused it to happen.

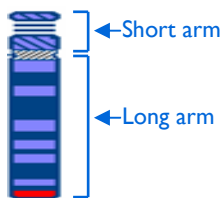
1: An entire extra chromosome

In most people with mosaic trisomy 14, a complete extra chromosome 14 is found. This usually follows a mistake in cell division producing either an egg or sperm with two copies of chromosome 14, instead of a single copy of this chromosome. After fertilisation with a normal egg or sperm, the developing fetus has three copies of chromosome 14 (**trisomy 14**). In order for cells to develop into a baby, they must grow and divide. At an early stage of development, one chromosome 14 is lost in some of the dividing cells, leaving two chromosome 14s and 46 chromosomes. The two different cell lines, one with 47 and the other with 46 chromosomes, develop at the same time, leading to **mosaic trisomy 14**. This process is called **trisomy rescue**.

2: An extra part of chromosome 14

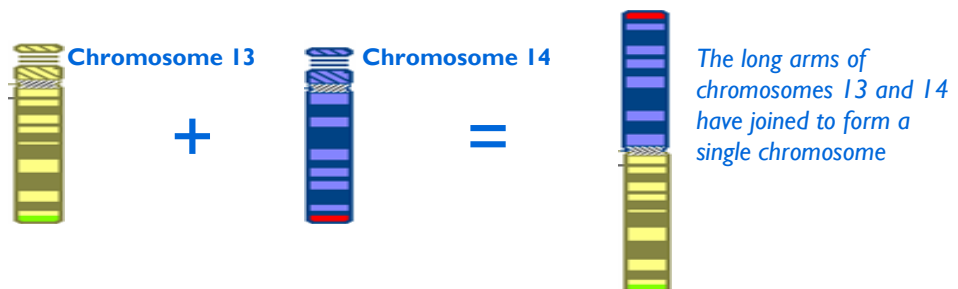
Chromosomes have two arms, one short arm (at the top in the diagram below) and one long arm (at the bottom).

Chromosome 14



No genes have yet been found on the short arm of chromosome 14 that could cause illness or developmental problems, so having too much of the short arm does not apparently matter. But having too much material from the long arm will affect development.

The other chromosomes that have short arms with no unique genes are 13, 15, 21 and 22. During the formation of an egg or sperm, when chromosomes are dividing and rearranging, the short arms of these chromosomes sometimes break off and two long arms of different chromosomes join together. For example:



This can lead to a baby having an entire extra long arm of chromosome 14. This usually occurs out of the blue, but in some cases, one parent has a chromosome consisting of two of these long arms. This is known as a Robertsonian translocation.

3: Idic 14

In addition to the 46 chromosomes that everyone has, people with Idic 14 have a small extra chromosome derived from chromosome 14. The extra chromosome usually consists of two copies of the bottom of chromosome 14 (the long arm) joined end-to-end in mirror image.



A small extra chromosome made up of two copies of the long arm of chromosome 14

How did the mosaicism arise?

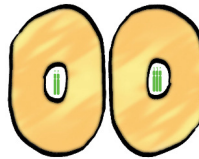
Babies with full trisomy 14 do not usually survive. For survival, they need some cells with the normal number of 46 chromosomes, containing the normal amount of chromosome material.

Pregnancies with mosaic trisomy 14 usually start in one of two ways. Following the mistake in cell division at conception, the fertilised egg has 47 chromosomes and full trisomy 14. At an early stage of development, one chromosome 14 is lost, leaving two chromosome 14s and 46 chromosomes in the process called trisomy rescue (see page 13). The two different cell lines, one with 47 and the other with 46 chromosomes, develop at the same time, leading to mosaic trisomy 14.

The other way that mosaicism can arise is after a normal conception with 46 chromosomes.

A mistake occurs in the natural copy-and-divide process of cell growth and an extra chromosome 14 travels into one cell.

This cell will have 47 chromosomes, with three chromosome 14s. The remaining



A cell with 46 chromosomes and two chromosome 14s (left) alongside a cell with 47 chromosomes and three chromosome 14s (right)

cells where no mistake occurred will have 46 chromosomes and two chromosome 14s.

Can it happen again?

The possibility of having another T14M pregnancy depends on the parents' chromosomes. If both parents have normal chromosomes, the trisomy is very unlikely to recur. All the same, the risk of chromosome trisomies increases in older mothers.

If either parent has a Robertsonian translocation involving chromosome 14 (see karyotype 2, page 2 and page 13), the possibility is greatly increased of having other affected pregnancies. Parents should have the opportunity to discuss their specific recurrence risks and options for prenatal and preimplantation genetic diagnosis (PGD) with a genetic counsellor. PGD requires in vitro fertilisation and embryo biopsy, and only healthy embryos are transferred to the mother's uterus. If the parents choose to conceive naturally, prenatal diagnosis options include chorionic villus sampling and amniocentesis to test the baby's chromosomes. Testing is very accurate, although not all tests are available in all parts of the world.

Two copies of the mother's chromosome 14: maternal uniparental disomy 14 (UPD14)

When there are two chromosome 14s in a cell, one usually comes from the father and one from the mother. In a cell with trisomy 14, there are either two chromosome 14s from the mother and one from the father, or two from the father and one from the mother. During trisomy rescue, the single chromosome 14 from one parent can be lost, leaving two chromosome 14s from the other parent in the cells with 46

chromosomes. If both chromosome 14s are from the mother, a condition occurs known as maternal UPD14. Maternal UPD14 should theoretically cause some additional features including early puberty, extremely mobile joints, spinal curvature (scoliosis), small hands and feet, tendency to overweight and high cholesterol levels. However, these have not yet been seen in children with mosaic trisomy 14 tested for UPD14. Paternal UPD14 generally has more serious consequences and so far no child has been described with mosaic trisomy 14 and paternal UPD14.

Identifying trisomy 14 mosaicism in pregnancy

Identifying and diagnosing trisomy 14 mosaicism in pregnancy is not straightforward. In particular, finding trisomy 14 cells together with cells with a normal chromosome make-up in a chorionic villus sample (CVS), which comes from the developing placenta, does not necessarily mean that the baby will have trisomy 14 mosaicism.

Detecting trisomy 14 mosaicism in CVS from 11 weeks

If the CVS shows trisomy 14 mosaicism, it will be investigated further because it usually represents a state known as confined placental mosaicism. In this, cells in the developing placenta contain the extra chromosome 14 but the cells in the baby do not. There are two ways of checking chromosomes after CVS, known as direct testing and long term culture. The most accurate results come from long term culture but in either case detailed ultrasound scans will be offered to check the baby carefully.

Diagnosing T14M from amniotic fluid from 14 weeks

Amniotic fluid contains some cells shed by the baby and by examining these cells it is usually possible to be more certain about whether the baby is affected by T14M or not. However, as amniotic fluid can also contain cells from tissues other than the baby, the results of even an amniocentesis are sometimes not clear. In order to get as complete and accurate a picture as possible, the results are usually considered together with the results of detailed ultrasound scans. In some centres it is also possible to examine cells exclusively from the baby by taking a blood sample from the umbilical cord.

Having repeated tests that can sometimes give unclear results is an extremely stressful experience. You should have the chance of an unhurried discussion of the outcomes with a geneticist before reaching any decisions about what to do next.



14 years

Support and Information



Rare Chromosome Disorder Support Group,

G1, The Stables, Station Road West, Oxted, Surrey RH8 9EE, United Kingdom

Tel/Fax: +44(0)1883 723356

info@rarechromo.org | www.rarechromo.org

Join Unique for family links, information and support.

Unique is a charity without government funding, existing entirely on donations and grants. If you can, please make a donation via our website at www.rarechromo.org Please help us to help you!

If your child's mosaic trisomy 14 is caused by a Robertsonian translocation, you may find it helpful to read Unique's lguide to Robertsonian Translocations

There is a Facebook group for Trisomy 14 mosaicism at www.facebook.com/groups/125824739443

Unique lists external message boards and websites in order to be helpful to families looking for information and support. This does not imply that we endorse their content or have any responsibility for it.

This information guide is not a substitute for personal medical advice. Families should consult a medically qualified clinician in all matters relating to genetic diagnosis, management and health. Information on genetic changes is a very fast-moving field and while the information in this guide is believed to be the best available at the time of publication, some facts may later change. Unique does its best to keep abreast of changing information and to review its published guides as needed. The guide was compiled by Unique and reviewed by Professor Sau Wei Cheung and Dr Marwan Shinawi, Assistant Professor, Department of Molecular and Human Genetics, Baylor College of Medicine, Texas, US and by Professor Maj Hultén BSc PhD MD FRCPath, Professor of Reproductive Genetics, University of Warwick, UK 2008. (PM)

Copyright © Unique 2008

Rare Chromosome Disorder Support Group Charity Number 1110661

Registered in England and Wales Company Number 5460413