

14q deletions proximal to 14q22

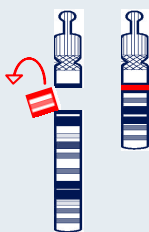

Sources and references

The information in this leaflet is drawn partly from the published medical literature.

The first-named author and publication date are given to allow you to look for the abstracts or original articles on the internet in PubMed. If you wish, you can obtain abstracts and articles from *Unique*.

The leaflet also draws on *Unique*'s database. When this leaflet was updated in 2011, *Unique* had 100 members with a 14q deletion, of whom 78 had a pure 14q deletion with no other chromosome involved.



An interstitial deletion

14q deletions

A chromosome 14 deletion means that part of one of the body's chromosomes has been lost or deleted. If the material that has been deleted contains important instructions for the body, learning disability, developmental delay and health problems may occur. How serious these problems are depends on how much of the chromosome has been deleted and where the deletion is.

Genes and chromosomes

Our bodies are made up of millions of cells. Most cells contain a complete set of genes. We have thousands of genes. Genes act like a set of instructions, controlling our growth and development and how our bodies work.

Genes are carried on microscopically small, thread-like structures called chromosomes. We usually have 46 chromosomes, 23 inherited from our mother and 23 inherited from our father, so we have two sets of 23 chromosomes in 'pairs'. Chromosomes and genes are made up of a chemical substance called DNA.

Chromosomes come in different sizes and apart from two sex chromosomes (two Xs for a girl and an X and a Y for a boy) they are numbered 1 to 22, generally from largest to smallest. Each chromosome has a short (p) arm (at the top in the diagram on the next page) and a long (q) arm (at the bottom of the diagram). In a 14q deletion, material has been lost from the long arm of one chromosome 14. The short arm of chromosome 14 contains no unique genes, so losing material from the short arm generally has no harmful effect.

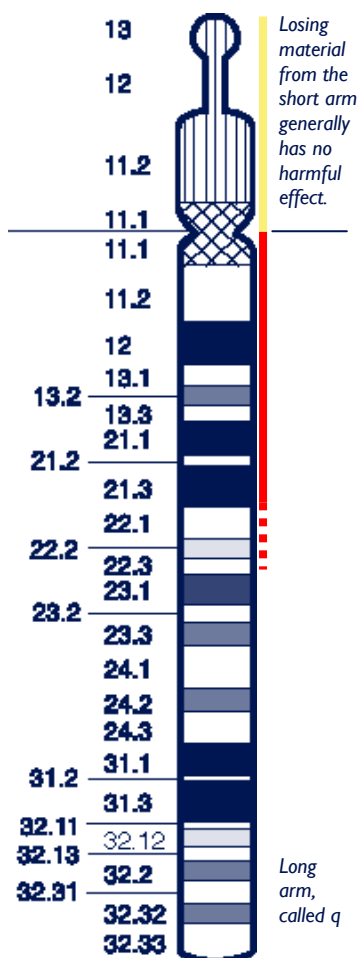
You can't see chromosomes with the naked eye, but if you stain them and magnify their image with a computer or under a microscope, you can see that each one has a distinctive pattern of light and dark bands.

A small or very large piece of the chromosome can be missing. If the piece is visibly missing when the chromosomes are magnified as much as 1250 times under a microscope or on a computer, it is called a **deletion**. The missing piece may be so tiny that the magnified chromosome looks normal and it can only be found using recently developed techniques, including molecular chromosome tests with or without DNA analysis. It is then called a **microdeletion**.

One type of deletion is called **terminal**. There is one breakpoint and the part of the chromosome from the breakpoint to the end of the arm is missing. Another type of deletion is called **interstitial**. There are two breakpoints on the same arm that have rejoined and the part of the chromosome between them is missing.

Your geneticist or genetic counsellor can tell you more about the chromosome material that has been lost. You will almost certainly be given a **karyotype**, a shorthand code for the image of your child's chromosome make-up that will show the points where the chromosome has broken and re-joined. Comparing your child's karyotype with others, both from the medical literature and within *Unique*, can help to build up a general picture of what to expect. But there will still be differences, sometimes quite marked, between your child and others with apparently similar deletions. It is very important to see your child as an individual and not to make direct comparisons with others with the same karyotype. After all, each one of us is unique.

Proximal deletions of 14q: from the end of the short arm (14p) as far as band 14q22



Some 31 cases with a pure deletion in this area are described, 21 in the medical literature, including a pregnancy that was terminated, and ten members of *Unique*. In addition, five members of *Unique* have a proximal deletion of 14q as well as loss of material from another chromosome arm (chromosomes 18q, 19q, 22q). The oldest member of *Unique* was eight years old when this leaflet was written. This is not meant to imply that the lifespan of children with a proximal 14q deletion is short; in older people the diagnosis has not necessarily been made.

It has been suggested that people with a proximal 14q deletion can be quite different from each other, although all have shown growth delay, hypotonia (a low muscle tone, making a baby feel floppy to hold), developmental delay and a small lower jaw. Differences in the size of the deletion account for many of the differences between individuals.

(Zahir 2007; Bisgaard 2006; Kamnasaran 2005; Su 2004; Kamnasaran 2001; Zannolli 2001; Ramelli 2000; Mehta 1999; Schuffenhauer 1999; Devriendt 1998; Chen 1997; Bruyere 1996; Govaerts 1996; Grammatico 1994; Shapira 1994; Levin 1991; Kodoma 1990; Remes 1982; *Unique*)

In eight cases where pregnancy was described, it was considered normal in four cases. Two pregnancies, and possibly three, had little amniotic fluid (oligohydramnios); another pregnancy was affected by excess amniotic fluid (polyhydramnios). Two babies were noted to be growing slowly (intrauterine growth retardation, IUGR) and a cleft lip and palate were observed on ultrasound at six months in a baby with a 14q12q13.1 deletion. Most pregnancies went to term and any problems were only noted after the delivery but one baby was delivered at almost 35 weeks after early separation of the placenta.

At birth

| What was unusual? | How many babies affected? |
|---|---------------------------|
| ■ Reluctant or unable to feed | 11/12 |
| ■ Low muscle tone (floppiness) | 12/17 |
| ■ Microcephaly (very small head) | 12/25 |
| ■ Minor anomalies of genitals | 3/8 boys |
| ■ Low birth weight | 4/18 |
| ■ Respiratory distress | 5/26 |
| ■ Partial or complete split in roof of mouth (cleft palate) | 4/25; 2/25 cleft lip |

Range of birth weights at or near term: 4lb 9oz/2.07 kg to 9lb 3oz/4.16 kg.

Most babies were delivered at or near term, though three were delivered at 35-6 weeks. Babies were generally not small-for-dates and birth weights in the *Unique* sample were higher than those reported in the medical literature; the mean birth weight was 6lb 6oz (2.9 kg). Growth after birth among babies was generally slow, with average height, weight and especially head circumference typically below the bottom line (marking the lowest three per cent of the population) on the growth chart in the first year of life. However, most children were proportionately small and light and after feeding problems were corrected grew steadily, if slowly.

By contrast, a *Unique* member with a small deletion in 14q13 was average height and weight by the age of seven years despite a low birth weight (6lb, 2.721kg).

Most babies were in good condition at birth, with Apgar scores at one and five minutes after birth (ratings of general wellbeing, on a scale 0-10) of seven and above. One baby with a 14q11q12 deletion had Apgars of 4 and 7 but no problems were noted in a baby with a tiny deletion at 14q12. A group of five babies, each with a deletion including 14q13, experienced severe respiratory distress at birth (page 6).

■ Feeding

Feeding difficulties were common, with babies generally unable to suck and swallow

effectively at birth. The *Unique* series shows that breastfeeding was not generally achieved and the great majority of babies required feeding by nasogastric or gastrostomy tube for weeks or months.

Gastro oesophageal reflux (GORD, GERD), where the stomach contents return up the food passage, was common and could persist, in one case affecting a six-year-old. One baby with a 14q11.2q13 deletion had swallowing difficulties and reduced peristalsis (automatic movement) of the food passage (oesophagus) with reflux. Reflux raises a baby's risk of inhaling feeds and causing an infection in the lungs known as aspiration pneumonia. Reflux can be eased by careful semi-upright positioning during and after feeds, sleeping in a prescribed sleep chair rather than a bed, raising the head end of the baby's cot and if necessary by prescribed medication that helps to keep the feed within the stomach. Babies who have continuing problems can have a surgical procedure called a fundoplication to improve the action of the valve at the junction of the food passage and stomach.

Where feeding and reflux problems are persistent, a gastrostomy tube (PEG, button) can be inserted to allow direct feeding into the stomach until the baby is sufficiently mature to tolerate feeding by mouth.

Constipation was common and many children needed to take daily laxatives.

“Breastfeeding didn't work for her. She was tube fed for six weeks, then bottle fed, and by six months was able to take cereal. Now at 14 months, she eats blended and minced food as part of a high calorie diet” -14q13q21 deletion

“She had severe reflux and two hospital stays for aspiration pneumonia. Her reflux was treated first with medicine, then a G-tube, then a G-J tube, then a Nissen fundoplication. She has dysphagia but no oesophageal anomalies and hasn't taken anything by mouth since birth” - 14q12q21, at 16 months

■ Hypotonia

An unusually low muscle tone, so that the baby or child feels floppy to handle. Babies with hypotonia tend to lie with their arms and legs loosely outstretched instead of bent at the knee or elbow. When held under the arms, their bodies easily slip through the hands. Babies and children with hypotonia benefit from early intervention with physiotherapy.

■ Head and brain

An unusually small head (microcephaly) appears to be typical ; the head may grow in proportion to the rest of the body or more slowly. However, one baby with a 14q11q12 deletion had a large head at birth and a baby with a microdeletion at 14q11.2 had a head size within the normal to large range. The head shape may also be unusual and asymmetrical but this was due in only one case to early fusion of one of the seam lines (sutures) where the bony plates of the skull join. Loss of the *FOXP1B* gene at 14q12 may cause microcephaly (Bisgaard 2006).

Where the head is unusually small or an abnormal shape, imaging of the head and brain with a CT or magnetic resonance imaging scan may be recommended. The outcome of scanning may show that all is normal, if small. All the same, a significant number of babies with a proximal 14q deletion have shown abnormalities within the structure of

the brain, including absence or thinning of the corpus callosum (the band of nerve fibres that links the two hemispheres of the brain), incomplete differentiation of the brain into two separate hemispheres and delayed maturity of the brain structures. The range of outcomes for babies with these abnormalities is quite broad; your child's neurologist or paediatrician is best placed to interpret what they are likely to mean.

■ Genitals

Children with chromosome disorders have a generally raised rate of minor disorders of genital development. This is usually most obviously seen in boys, where testicles that are undescended at birth (cryptorchidism) and hypospadias (the hole is situated on the lower side of the penis instead of at the tip) are both relatively common. Neither condition was observed among *Unique* members, but two boys have been reported in the medical literature with hypospadias or undescended testes (Grammatico 1994; Remes 1982). Treatment for undescended testicles depends on the suspected cause but is usually needed if the testicles do not descend naturally in time. A short course of hormone treatment may be suggested if a hormone problem is suspected. Otherwise the testicles can be brought down in a short operation under general anaesthetic called an orchidopexy. Hypospadias can also be corrected surgically.

■ Breathing

All the babies with a 14q13q21 deletion experienced severe respiratory distress at birth and needed their breathing supported at first with a ventilator. Severe breathing difficulties are believed to be caused by a missing gene at 14q13. This gene, the thyroid transcription factor-1 gene (*TTF-1*), is believed to be important for producing the surfactant that coats the surfaces of the air sacs inside the lungs and stops them from collapsing inwards. Not all babies with a deletion at 14q13 are affected, however, probably due to variations in the level of expression of the gene.

■ Partial or complete split in roof of mouth (cleft palate)

A few babies have been born with a cleft palate (a split in the roof of the mouth). The hard palate at the front of the mouth may be split or the split may be found further back in the soft, fleshy tissue at the back of the top of the mouth. Occasionally the split is only seen in the tissue that hangs down above the tongue at the very back of the mouth (uvula, known as a bifid uvula when it is split). A cleft lip may also occur (see pages 7-8 Brain and central nervous system).

A cleft lip and palate causes difficulties both in feeding and in speech production. Your baby's caregivers will advise on how to minimise problems. Surgical repair is usually needed to ease these difficulties and eventually may eliminate them altogether.



Appearance

There may be little sign in the appearance of most babies with a proximal 14q deletion of the underlying disorder. Doctors may notice what are known as 'dysmorphic features' which may or may not be obvious to a parent. Some of the typical features include a round face, some degree of facial asymmetry, a high, prominent

forehead, a short, upturned nose with a low bridge and sometimes widely flared nostrils, wide set eyes, large ears placed low on the head, a small lower jaw and a short neck.

Each baby is an individual and some have almost no features considered ‘typical’. One baby with a large deletion from 14q11.2 to q21.1 had a triangular face and a prominent chin; a *Unique* member with a 14q13q21 deletion had none of the typical facial features. Another *Unique* member with a microdeletion at 14q11.2 had pointed ears as the only unusual facial feature.

■ Hands and feet

Minor, non-functional anomalies of the hands and feet are relatively common in children with chromosome disorders. One baby had incurved fifth fingers and two children have been described with a single palm crease. One child had marked furrowing of the soles of the feet, two children with a deletion between 14q12 and 14q21/2 had overlapping toes and one baby had prominent heels. These can usually be corrected passively, using plastic splints; toe position may improve when a child starts to walk.

One child was born with feet in the calcaneovarus position (the foot points inwards and up); another with unspecified club feet. Treatment options, tailored to the individual, include physiotherapy, strapping, casting and surgery.

Medical concerns

| | How many children affected? |
|---|-----------------------------|
| ■ Difficulties with growth or weight gain | 9/13 |
| ■ Midline defects of central nervous system | 12/26 |
| ■ Abnormal thyroid function | 8/24 |
| ■ Seizures | 7/25 |
| ■ Structural heart problem | 3/24 |
| ■ Long term lung problem | 3/5 |
| ■ Visual impairment | 12/24 |

■ Difficulties with growth or weight gain

Many babies and children grow slowly and have difficulties with weight gain but there is no evidence of underlying growth hormone shortage or resistance. It is also not yet known what adult height most children can expect to achieve. Many children have needed feeding support, either by nasogastric tube or longer term using a gastrostomy tube direct to the stomach, after which their rate of growth and weight gain usually stabilises.

■ Brain and central nervous system

Around half the babies born with a proximal 14q deletion have signs of a midline defect in the central nervous system. Holoprosencephaly (HPE) is the term for a spectrum of developmental abnormalities of the forebrain affecting its division into two hemispheres. The abnormalities can be anything from severe to trivial and include a thinned or missing corpus callosum (the band of nerve fibres that links the two hemispheres of the brain). HPE is often reflected in the midline structures of the face, resulting in anomalies such as a cleft lip or, at the less severe end of the spectrum, a single, symmetrical upper front tooth. There are many different causes of HPE, but a site for a gene (*HPE8*) has been mapped to 14q13 (Kamnasaran 2005; Chen 1997).

■ Thyroid function

A number of children have been reported with thyroid dysfunction and a gene that is important for normal thyroid functioning (*TITF-1*) has been mapped to 14q13. This gene is also thought to play a role in the development of healthy lung function (see page 6, [Breathing](#)). Children with abnormal thyroid function have been successfully treated with thyroxine replacement (Krude 2002; Iwatani 2000; Mehta 1999; Devriendt 1998).

■ Seizures

Although seizures are more common in children with a proximal 14q deletion than in others, most children do not experience them. Seven of the 25 children had a possible or confirmed seizure diagnosis, of whom five had a documented brain anomaly and four had a missing corpus callosum (see Brain and central nervous system). One child with normal cranial scans also experienced seizures. Generally seizures were controlled with anti-epileptic medication but among *Unique* members, one child experienced seizures that were hard to control.

■ Heart

Most children were born with a normal heart structure and function. Three babies were found to have a patent foramen ovale, the persistence of a hole between the two upper chambers of the heart that usually closes at birth and in one case this was accompanied by a patent ductus arteriosus (PDA), another persisting structure of the fetal circulation. In another case, the PDA was accompanied by a narrowing of the valve in the pulmonary artery that leads to the lungs (pulmonary stenosis). Treatment of these heart conditions is decided on an individual basis but can include initial monitoring to see whether they resolve naturally and, if need be, surgical correction.

■ Lungs

Of the five babies with severe respiratory problems at birth, three experienced ongoing breathing difficulties. Two babies developed bronchopulmonary dysplasia, a form of chronic lung disease in which scar tissue within the lungs causes small areas of the lung to collapse while other areas trap air and expand. Recovery usually takes months and even years and meanwhile a child will need extra oxygen.

■ Kidneys

One child described in the medical literature had renal tubular acidosis, a condition in which the kidneys fail in their job of maintaining an even acid-alkaline balance in the

body by not excreting acids into the urine, causing the blood to remain too acidic. Another child had kidney cysts. Despite extensive imaging in others, the only other kidney anomaly was found in a child with healthy horseshoe kidneys. In this condition, the bottom points of the two usually separate kidneys are fused. It usually causes no symptoms but may be prone to obstruction.

■ Eyesight

A degree of visual impairment appears to be common, affecting 12/24 children, with three described as cortically blind and at least three more as cortically impaired. In cortical blindness, the eye structures may function normally, but the visual systems in the brain do not understand or interpret what the eyes see. Three further children were described as unable to fix and follow by the age of six months, raising questions over their functional sight. Two further children were described as having a 'variable / alternating squint with crossed fixation' - seeing left with the right eye and right with the left eye. Another child had a developmental defect affecting the optic nerves and the retina at the back of the eye.

Visual impairment was observed regardless of the size or position of the deletion.

■ Hearing

Hearing appears to be generally unaffected, with just three children diagnosed with middle ear dysfunction caused by the build-up of fluid known as glue ear and treatable where necessary by drainage and the insertion of tubes in the eardrum. Normal hearing appears despite the presence of genes for deafness (*DFNA53* and *DFNA9*) at 14q11.2q12 and 14q12q13.

General wellbeing

Most children were healthy, although four, including three of the babies in the *Unique* series of ten, suffered from repeated infections, in particular chest infections, in the first months of life. Those babies who had severe respiratory distress at birth were especially vulnerable to long-term lung problems.

Development

Sitting, moving - gross motor skills

Babies and children with a large proximal 14q deletion typically appear to face considerable delay in reaching their mobility milestones. Recently, some children have been diagnosed with very much smaller deletions, known as microdeletions, and it is possible that they will experience less delay. Among those with a larger deletion, head control typically develops late and babies need to sit supported for a long time before achieving unsupported sitting. The skill of rolling may emerge in the first or second years of life.

However, there is a lot of individual variation: a child with a small deletion within band 14q13 crawled at 19 months and walked at the age of 2 while another child with a deletion between 14q13.1 and 14q13.2 was scooting on her back indoors at seven.

Early physiotherapy input is important to assess babies' needs for therapy and equipment and to guide families to stimulate early activity. Adapted seating, standers, gait trainers and walkers are likely to be helpful in extending children's range of

mobility. Children are likely to also benefit from supports for their joints, which may be loose and floppy due to their underlying hypotonia or unnaturally stiff due to raised muscle tone.

Using their hands: fine motor and coordination skills

Hand and eye coordination skills such as holding a bottle and playing with small toys may not develop in line with gross motor skills. A child who is late to hold his head steady may still reach for toys. Overall, there appears to be fairly consistent delay in hand use and fine motor skills, regardless of the deletion size. The delay may be quite marked, so that in some cases, school-age children are not yet able to hold toys for any length of time.

This delay means that early intervention by occupational therapy to stimulate hand use is vital.

“ At 14 months she started reaching and grasping for toys; at 15 months she started taking and shaking rattles. We are thrilled! ” – *14q13q21 deletion*


Learning

Although the information available comes exclusively from young children, it is clear that children with a proximal 14q deletion are likely to need considerable support with their learning. Those with a smaller microdeletion may be more mildly affected but it is really too early to know for certain. In the *Unique* series, children are in both mainstream and special needs settings; this depends largely on local arrangements.

- A child with a 14q13.1q13.2 deletion is described as having a good memory and learning by her own persistence and when she is happy; she has a learning disability characterised as severe.

Speech and communication

Generally, speech and language reflect the level of learning disability and children with greater learning difficulties appear to use less speech. Understanding is also affected but children generally understand more than they can express. Children with a proximal 14q deletion may not develop speech but communicate instead using vocal noises, expression or occasional words. The evidence from *Unique* suggests that understanding may also be limited, despite unimpaired hearing, but children can learn to respond to familiar voices, signs and phrases. Against this background, a child with a small deletion within 14q13 spoke her first words at 32 months and was speaking in six-word phrases by the age of four years and a child with a microdeletion at 14q11.2 was also talking well at four years.



Behaviour

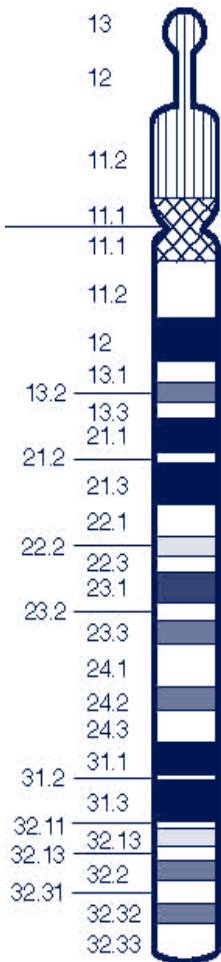
Children and babies with a proximal 14q deletion are described as generally easy-going and happy. In the absence of descriptions of older children and adults, it is not yet possible to predict mature behaviour but in early childhood the picture is generally positive. Despite this, two children have been described with autistic-like features, such as hand-wringing and

repetitively opening and closing doors and one child who is otherwise mildly affected has shown social communication delays.

“ She loves music, trees and enjoys people talking to her ” - *del(14)(q13.1q13.2)* at 7 years

“ A happy, sweet cute baby very much loved by her family and extended family. She enjoys music, laughs and is a total sweetheart. Her family think she is just perfect the way she is and we will love her and support her to ensure that she can do anything she desires. We love her very much ” - *del(14)(q13q21)* at 15 months

Microdeletions of 14q11.2



Four children including one *Unique* member have been identified with a microdeletion within 14q11.2. All have lost part or all of two genes, *SUPT16H* and *CHD8*, and this may explain their symptoms. The children look like each other and three have widely spaced eyes, a broad flat nasal bridge and short nose, a long groove between the nose and upper lip, an obvious ‘Cupid’s bow’ on the upper lip and a full lower lip, and some have unusual ‘pointy’ ears. All four children were floppy (hypotonic) as babies and all have experienced developmental delay (Zahir 2007; *Unique*).



Deletions from 14q22

You can find information about deletions from 14q22q23 in *Unique*’s guide to **14q deletions: between 14q22 & 14q32**

Support and Information



Rare Chromosome Disorder Support Group,

G1, The Stables, Station Road West, Oxted, Surrey RH8 9EE, United Kingdom

Tel/Fax: +44(0)1883 723356

info@rarechromo.org | www.rarechromo.org

Join Unique for family links, information and support.

Unique is a charity without government funding, existing entirely on donations and grants. If you can, please make a donation via our website at www.rarechromo.org Please help us to help you!

This information guide is not a substitute for personal medical advice. Families should consult a medically qualified clinician in all matters relating to genetic diagnosis, management and health. Information on genetic changes is a very fast-moving field and while the information in this guide is believed to be the best available at the time of publication, some facts may later change. Unique does its best to keep abreast of changing information and to review its published guides as needed. The guide was compiled by Unique and reviewed by Dr Kamilla Schlade-Bartusiak PhD, Department of Medical Genetics, University of Alberta, Canada and by Professor Maj Hultén BSc PhD MD FRCPATH, Professor of Reproductive Genetics, University of Warwick, UK 2007.

Copyright © Unique 2007

Rare Chromosome Disorder Support Group Charity Number 1110661

Registered in England and Wales Company Number 5460413