

# Tetrasomy 9p



## Tetrasomy 9p

Tetrasomy 9p is a rare condition that was first described in 1973 (Ghymers 1973). People with this syndrome usually have a small extra chromosome made up of two copies of part of chromosome 9. This extra chromosomal material makes it very likely that people with tetrasomy 9p will need support with their learning and development, as well as help for some birth defects and health problems.



3 years

## Genes and chromosomes

Our bodies are made up of billions of cells. Most of these cells contain a complete set of thousands of **genes** that act like instructions, controlling our growth, development and how our bodies work. Inside all human cells, except the red blood cells and platelets, there is a nucleus where the genes are carried on microscopically small, thread-like structures called **chromosomes**.

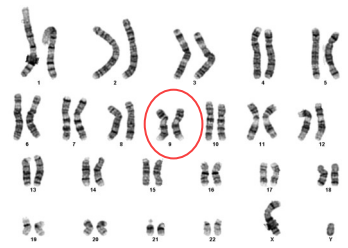Chromosomes come in pairs of different sizes and are numbered from largest to smallest, roughly according to their size, from chromosome 1 to chromosome 22.

In addition to these so-called autosomal chromosomes are the sex chromosomes, X and Y. A normal, healthy cell therefore has 46 chromosomes: 23 inherited from our mother and 23 inherited from our father, so we have two sets of 23 chromosomes in pairs. A girl will have two X chromosomes (XX) while a boy will have one X and one Y chromosome (XY). Each chromosome in a pair has a short (**p**) arm (from the French *petit*, small) and a long (**q**) arm separated by a constricted region called the **centromere**. Most of the time, chromosomes are entangled in the nucleus.

## Sources

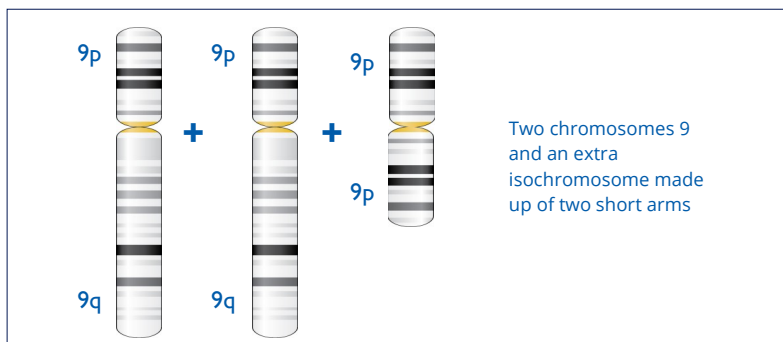
The information in this booklet is drawn from published medical literature, where approximately 65 cases are reported, and information from *Unique* members. The first-named author and publication date of articles in the medical literature are given to allow you to look for the abstracts or original articles on the internet in PubMed (<http://www.ncbi.nlm.nih.gov/pubmed>). If you wish, you can obtain most articles from *Unique*. The most recent survey of *Unique* members was carried out in 2017. At this time, *Unique* had 42 members with tetrasomy 9p.

A **karyotype** is a classification of all the chromosomes according to their size and the position of their **centromere**. This allows analysis of the number and appearance of a person's chromosomes.



Karyotype showing chromosome pairs 1-22, X and Y (male)  
Chromosome 9 pair circled in red

People with tetrasomy 9p usually have two normal chromosomes 9 (one inherited from each parent) as well as an additional small 47<sup>th</sup> marker chromosome made up of material from two extra copies of material from at least the short (p) arm of chromosome 9 - sometimes it also includes some material from the long (q) arm. This means that in total they have four copies of the 9p arm, hence the name 'tetrasomy 9p' from the Greek word 'tetra', meaning four. An extra chromosome made up of two copies of the same part separated by a centromere, thereby forming a "mirror-image", is called an **isochromosome**. When the isochromosome contains two centromeres or part of the long (q) arm, this is described as an **isodicentric** chromosome.



To date, approximately 65 cases of tetrasomy 9p have been described in the medical literature, including 20 prenatal cases (El Khattabi 2015; Wang 2015). No bias in the ratio of boys to girls affected has been observed (Chen 2014).

## Tetrasomy 9p mosaicism

When all the cells of the body contain the extra isochromosome 9, this is known as **non-mosaicism**. Non-mosaic tetrasomy 9p usually results in miscarriage and babies with non-mosaic tetrasomy 9p are not usually able to survive beyond the newborn period. In most newborn babies the isochromosome 9 is only found in some cells and the remaining cells have a normal karyotype of 46 chromosomes. This is known as **mosaicism** and affects almost 40% of cases (El Khattabi 2015; Ogino 2007). The cells tested

for the karyotype (*see below*) are most often taken from a blood sample. In tetrasomy 9p, blood cells often show non-mosaicism (that is, only tetrasomy 9p cells), even where there is mosaicism or cell types with only normal cells in other tissues of the body. So a person who has only had a blood test may be thought to have non-mosaic tetrasomy 9p, when in fact there is mosaicism in other tissues. For this reason, most geneticists recommend testing samples from more than one tissue, usually either from the skin or from inside the cheek, to try to confirm mosaicism (Lloveras 2004). Babies found to have mosaic tetrasomy 9p are likely to do better than those with non-mosaic tetrasomy 9p, especially in terms of survival (El Khattabi 2015; de Azevedo Moreira 2003; Dhandha 2002; Dutly 1998).

## The karyotype

Your geneticist can tell you more about how much material there is in the extra isochromosome. The chromosome usually breaks in the [centromere](#) but sometimes it breaks in the long arm, usually close to the centromere.

[47,XY,+i\(9p\)](#) This shows that there are 47 chromosomes, it's a boy (XY), and the extra (+) chromosome is an isochromosome (i) made up of material from the short (p) arm of chromosome 9.

[47,XX,iso\(9\)\(q12\)de novo](#) This shows that it's a girl (XX) and that the extra chromosome is made up of the short arm and material as far as band q12 in the long arm. *De novo* means that the parents' chromosomes have been examined and are normal. Hence, the anomaly appeared as a new event (*de novo*) in the child. *Iso* was used by laboratories in the past but today would be (i) or, strictly speaking in this case, *idic* (*see below*).

[47,XY,+idic\(9\)\(q13\)](#) This shows that the extra chromosome is made up of material from the entire short arm and the long arm as far as q13, including the centromeres where the short arms meet the long arms. Since the extra isochromosome includes two centromeres it is an isodicentric chromosome, shortened to *idic* (pronounced 'eye-dic').

[47,XY,+i\(9\)\(p10\)\[4\]/46,XY\[16\]](#) This is a boy in whom 20 cells were tested. Four [4] showed tetrasomy 9p while sixteen [16] showed a normal karyotype for a boy or man.

[arr\[hg19\] 9p24.3q21.11\(203861\\_69002886\)x4](#) This result shows that a technology known as chromosomal microarray analysis ([arr](#)) showed that there are 4 copies of the p arm of chromosome 9 and part of the q arm as far as band q21.11. [hg19](#) tells you which version of the human genome was

## Genome Assemblies

The human genome project, an international effort to sequence the entire human genome and map all of its genes, was announced complete in 2003.

However, there were many gaps in the sequence and mapping data, and scientists have since been working continuously to identify the missing information. When new sequence information is identified, the base pair numbers of each chromosome change slightly and hence the numbers for individual genes and duplications can shift.

Each new version of the genome is often referred to as an 'assembly'. Every few years a new assembly is released. The genetic information you are given will be based on the Genome Reference Consortium (GRC) human (h) genome assembly that was the most up-to-date at the time the test was carried out. Therefore, you may see the DNA sequence referred to as hg19 (human genome 19) (on your child's genetic report it may also be referred to as GRCh37), which was released in 2009, or hg 18, which was released in 2006. The lower the hg number, the earlier the release. The most recent assembly is named GRCh38/hg38 and was released in 2014.

used to make these measurements (*see above*). The DNA anomaly is identified by its base pair numbers (the points where the chromosomal change has occurred). In this example, the DNA anomaly lies between base pairs 203,861 and 69,002,886 (a region covering almost 69 million base pairs). There are four copies (x4) of the piece of DNA specified. Note that these boundaries cannot be precisely defined by this technique.

### Most likely features among those with tetrasomy 9p

The most likely features among those with tetrasomy 9p - found in at least half of all children and adults reported or described so far - are listed below (El Khattabi 2015; Papoulidis 2012; Ogino 2007; de Azevedo 2003; Dhanda 2002; Unique).

- Developmental delay/learning difficulties: In 25/27 *Unique* cases and 73% of cases reported in the literature (El Khattabi 2015), a delay in expected development was observed and was often the first sign that anything was wrong. Signs were first noticed between the newborn period and early secondary school age. Some degree of learning difficulty is to be expected.
- Central nervous system (brain and spinal cord) anomaly.
- Abnormal features of arms or legs. These can include dislocated/hyper-mobile joints and clubfeet.



6 months

- Growth delay before or after birth.
- Heart defects.
- Abnormalities of the kidneys, urinary or genital systems (43%) (El Khattabi 2015). In boys, minor anomalies of the genitals or undescended testicles are common. Abnormalities in the genitals of girls are less common.
- At birth, wide gaps between the bony plates of the skull. The front soft spot (fontanelle) may be large.
- Typical facial features including wide set eyes, small jaw (chin), oddly formed or positioned ears and a bulbous or beaked nose.
- Cleft lip/palate or a high-arched palate.



1 year

## Other typical features

- Unusually formed nails; a single crease across the palm; incurving fingers, especially the fifth finger; short hands and feet with small toe and finger joints.
- Widely-spaced eyes; small skin folds across the inner corner of the eyes; eyes that slant somewhat downwards; a small lower jaw, set back from the upper jaw; downwards-slanting mouth.
- Low muscle tone, making the body feel floppy (hypotonia).
- Unusual head size - small (microcephaly) or large (macrocephaly).
- Enlarged fluid-filled ventricles within the brain (hydrocephaly).
- Strabismus (squint) or short sight (myopia).
- Dimple near the base of the spine.
- Sunken eyes due to the eyeball being recessed within the orbit.
- Missing or underdeveloped bones.
- Benign (non-cancerous) skin growths (pilomatricoma).



8 years

Not all signs are present in all patients. Some patients do not display any visible signs or only a few minor ones.

## How is tetrasomy 9p diagnosed?

Tetrasomy 9p cells are usually found in highest concentrations in the blood, so diagnosis in a baby, child or adult means taking and analysing a blood sample (Lloveras 2004). A blood sample that shows the presence of an isochromosome in every cell may suggest that a person has tetrasomy 9p in its non-mosaic form, but testing cells present in the saliva and other tissue types may reveal that abnormal cells are present at much lower levels or are completely absent (mosaicism). This could explain why a person may have only mild features despite an initial diagnosis of non-mosaic tetrasomy 9p based on testing only cells found in the blood (Shehab 2011). There is, of course, a limit to the types of tissue that it is possible to test through these less invasive means, and it may therefore often not be possible to obtain a conclusive diagnosis of mosaicism; it is not uncommon for families to decide not to pursue further tests once a blood test has confirmed tetrasomy 9p (even in cases where mosaicism isn't confirmed) (Unique).

The majority of *Unique* children received a diagnosis within the first few years of life, usually as a result of developmental or growth delay.

“ She was diagnosed at four months as she was failing to thrive, had features of a chromosomal disorder and developmental delay. The diagnosis has been helpful. ”

“ He was first diagnosed with failure to thrive at two months of age. At 7 months, he was hospitalized due to continued failure to thrive. Blood tests were completed by a geneticist and we received the diagnosis six weeks later. Contact with other parents has been the biggest benefit. ”

“ He was diagnosed at five months of age when he was showing low muscle tone and developmental delay. The diagnosis was very helpful. We were able to get the correct therapist to help him progress. ”

## Prenatal diagnosis

Diagnosis during pregnancy is challenging as routine foetal ultrasounds may appear normal and tetrasomy 9p cells may not be found in foetal cells in the amniotic fluid (Papoulidis 2012). It is therefore quite possible for a pregnancy to be affected by tetrasomy 9p but for the amniotic fluid or chorionic villus sample to show only cells with normal chromosome numbers (Chen 2007; Eggermann 1998; Grass 1993).

Interphase fluorescence in situ hybridisation (FISH) can be used to confirm the diagnosis of tetrasomy 9p and help determine the true degree of mosaicism since it allows for a fast analysis of a high number of cells (El



Khattabi 2015; Chen 2014; Shehab 2011). *Unique has a supplementary information sheet on prenatal diagnosis.*

## Why are some people with tetrasomy 9p more severely affected? Why is tetrasomy 9p so variable?

There are four key reasons: whether the person has mosaic or non-mosaic tetrasomy 9p; whether this mosaicism is limited to certain tissues; the size of the isochromosome; which regions of chromosome 9 have been duplicated (Wang 2015; Nakamura-Pereira 2009).

**Mosaic or not mosaic:** When only tetrasomy 9p cells and no normal cells are found in both blood and skin cells or amniotic fluid, the effects are likely to be more obvious and more severe. Babies with mosaic tetrasomy 9p are more likely to survive the newborn period (El Khattabi 2015).

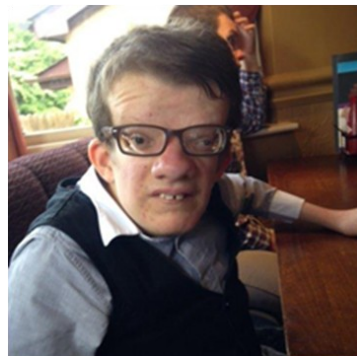
It might seem obvious to suggest that when a higher proportion of tetrasomy 9p cells is found, the effects are likely to be more severe. But this is not necessarily true (Papoulidis 2012). One reason for this discrepancy may be varying proportions of tetrasomy 9p cells in tissues of importance for development – tissues that often cannot be investigated.

**Tissue-limited mosaicism:** The proportions of tetrasomy 9p cells are different in different body tissues. A review in 2015 found that approximately one third of reported cases of tetrasomy 9p showed tissue-limited mosaicism (El Khattabi 2015). In blood there are more tetrasomy 9p cells and sometimes no normal cells are found. In other tissues, especially skin and mucous membranes, the proportion of tetrasomy 9p cells is usually lower and no tetrasomy 9p cells may be observed. Organs such as the brain and lungs, may have different proportions again and this variability is very likely to affect the outcome (Lloveras 2004; Dhanda 2002). It should be noted that in some cases the degree of mosaicism did not seem to correlate with the severity of the symptoms observed (Papoulidis 2012).

**Size of isochromosome:** That is, the amount of extra chromosome material. Common sense suggests that those with larger extra chromosomes will be more severely affected; however, there have been reports of people with isochromosome 9p who are only very mildly affected or indeed seem not to be affected at all. It should be noted that a recent review of almost 60 cases suggests that developmental delays are more frequent when a portion of the long arm of chromosome 9 (9q) forms part of the isochromosome (El Khattabi 2015). This variability means that when tetrasomy 9p is identified prenatally, providing appropriate genetic counselling can be difficult. It is also true that individual differences between children even with the



same karyotype can be fairly marked. We do know that of 14 cases of prenatally-detected tetrasomy 9p (three mosaic and 11 non-mosaic), all the reported cases with non-mosaic tetrasomy 9p were associated with severe abnormalities (Chen 2014). Equally, there have been five reports of patients with mosaic tetrasomy 9p with no apparent clinical symptoms (Papoulidis 2012; Baronchelli 2011; McAuliffe 2005).



26 years

**Specific duplicated regions:** Not unsurprisingly, the specific region that is duplicated and the genes that are disrupted can have a marked influence on the severity of symptoms.

A boy with three copies of the section of chromosome 9 between band p13 and p22 shared some similarities with children with an isochromosome 9p, but had no major anomalies apart from enlarged ventricles within the brain. While this could suggest that the part of 9p that he did not have extra copies of (9p23 to the tip of 9p) is the part that causes important birth defects (Verheij 1999) this may be over-simplistic.

## **Are there people with tetrasomy 9p who are healthy, have no major birth defects and have developed normally?**

Yes, there are. Out of around 65 reports in the medical literature, there are at least five people with apparently normal development and a possible sixth. One adult is an accountant and was discovered to have tetrasomy 9p when infertility was investigated. Two apparently healthy 20- and 28-year-old women with tetrasomy 9p mosaicism were also reported, highlighting that there is not always a correlation between the level of mosaicism and the degree to which a person is affected. Another adult was investigated for skin lesions (pilomatricoma). Another case is of a child who has developed normally to the age of five, although he showed growth delay before birth; a six-month-old baby also had no apparent abnormalities at the age of six months (Papoulidis 2012; Shehab 2011; Baronchelli 2011; McAuliffe 2005; Lloveras 2004; Nakamura 1990). Among *Unique's* members, two children were only diagnosed after being investigated for developmental delay in the late primary school or early secondary school years.

A 10-year-old boy with tetrasomy 9p mosaicism had features that mimicked Klinefelter syndrome. Klinefelter syndrome occurs in males with an extra X chromosome (47,XXY) and is associated with tall stature and anomalies of

the genitals, including an inconspicuous penis (when the penis appears to be absent or too small) and testicular dysfunction, and no other major anomalies. Otherwise, this boy exhibited normal motor skills, was in good health and progressing well at school. In this case, it is likely that the percentage of tetrasomy 9p cells in the testis was higher than in the blood or saliva. This was in fact the second reported case of tetrasomy 9p mosaicism mimicking Klinefelter syndrome and other cases of trisomy 9p and mosaic tetrasomy 9p cases with gonadal hypofunction, when the testes or ovaries show a diminished level of function, have also been reported. This suggests that over-expression of some genes on chromosome 9p may lead to gonadal/testicular hypofunction (Ogino 2007; Peters 1982).

## What is the outlook?

The outlook for babies diagnosed with tetrasomy 9p is extremely variable. In some babies there is little or no effect on development or health, while in others the effects are obvious and sadly survival may not be possible. Among *Unique's* members, two babies were stillborn, one passed away at 22 days and another died at 13 months. Those babies diagnosed with non-mosaic tetrasomy 9p appear to be at greatest risk and typically do not survive the newborn period. Babies with a mosaic form of tetrasomy 9p have a better outcome. People with an isochromosome containing part of the 9q region or when at least two tissues are affected, appear to be more likely to have heart defects and learning difficulties and may be less likely to survive the newborn period (El Khattabi 2015).

As tetrasomy 9p is most likely to appear to be non-mosaic in blood, in babies where with the diagnosis has been made from a blood test, it is sometimes recommended that tissues from another part of the body (such as skin or mucous membranes) are examined as well, as they are more likely to show mosaicism (Shehab 2011; Tang 2004; Moreira 2003; Dhanda 2002).

There is little published information on the long-term outlook for babies born with tetrasomy 9p. Among *Unique* members born without complex heart problems, the majority were healthy and active and taking no regular medications apart from vitamins. One child has Raynaud's disease, with spasm of the blood vessels in the extremities, and polyarthritis causing pain in many joints; one has developed chronic relapsing fatigue; and several have recurring pilomatricoma, which have sometimes been removed surgically (see pg 31) (Unique).

## How did this happen?

In the great majority of children, the extra material from 9p appears as a

separate, small chromosome. When the blood of parents with an affected child is examined, it has so far always revealed normal chromosomes (McAuliffe 2005, Unique). In this situation, studies have indicated that the most common reason for the extra chromosome is the failure of the chromosomes 9 in one parent to separate in the process of preparing the eggs or sperm, leading to an extra whole chromosome 9. This extra chromosome is believed to then undergo a breakage in the long arm, followed by a duplication of the short arm containing the centromere and a variable portion of the long arm. The remaining long arms are lost because they do not contain the centromere (Dutly 1998).

Separation failure, termed non-disjunction, is more common in older mothers (as in Down's syndrome) and both the maternal and paternal average age of those having a child with tetrasomy 9p is slightly higher than average; however, a clear correlation between advanced maternal age and the occurrence of tetrasomy 9p has not been reported (El Khattabi 2015; Di Vera 2008; de Azevedo Moreira 2003; Dutly 1998; Grass 1993).

### Can it happen again?

So long as the parents have normal chromosomes, the extremely unusual sequence of events that led to a foetus with tetrasomy 9p is very unlikely to happen again. Many couples will want the reassurance of having their next baby's chromosomes tested during pregnancy by chorionic villus sampling or amniocentesis. Although there are some very rare cases of tissue-specific tetrasomy 9p that do not show tetrasomy 9p in the amniocytes or chorionic villi that are tested, a normal result is reassuring (see How is tetrasomy 9p diagnosed?). Only one instance of two children affected by tetrasomy 9p being born to the same parents has been reported and is likely to be due to gonadal mosaicism, that is the presence of tetrasomy 9p in some cells of the testes of the father or ovaries of the mother. If a sperm or an egg containing the isochromosome 9p is involved in the formation of the embryo, then the child will be affected (El Khattabi 2015).

### Can it be passed on?

The great majority of children with tetrasomy 9p have parents with normal chromosomes. But there are some people - and no-one really knows how many of them there are - who themselves have tetrasomy 9p but are very mildly affected by it. They can pass it on. They can also have unaffected children. One man with tetrasomy 9p had two children with normal chromosomes, but his wife also had five pregnancies resulting in miscarriage (McAuliffe 2005).

## Pregnancy


Whilst pregnancy is often described as uneventful, information from both *Unique* members carrying babies with tetrasomy 9p and reports in the medical literature, reveals that some babies showed reduced growth and movement in the womb. There are also reports of unusual ultrasound findings, although these were more common in babies with non-mosaic tetrasomy 9p (see Prenatal Diagnosis, pg 7).



## A child with tetrasomy 9p

### Facial appearance

Certain facial features are found more often in children with tetrasomy 9p than in other children. These features do not matter to your child, but they may mean that you see unexpected similarities between your child and others with tetrasomy, or even trisomy 9p. The most common features are: a broad, bulbous or beaked nose; widely-spaced eyes that can be deep set or even sunken and may slant upwards or downwards; unusually formed or positioned ears; a small lower jaw (micrognathia) that may also be receding (retrognathia); a large mouth with down-turned corners or a short groove between the upper lip and the nose; a short/broad neck or too much nuchal skin; and skin folds at the inner corner of the eyes. Your child's head may have an unusual shape: some *Unique* members mention that their child has a flattened skull, either at the back (brachycephaly) or on one side (plagiocephaly), while several children have trigonocephaly, where when seen from on top the head looks pointed or triangular. The head may be unusually small (microcephaly) or large (macrocephaly). In the *Unique* series, newborn babies often had wide gaps between the bony plates of the skull and a very large soft spot (fontanelle) on top of the head that sometime took years to close. Affected babies also showed a decreased rate of growth (El Khattabi 2015; Ogino 2007; Tan 2007; Henriques-Coelho 2005; Dhanda 2002; Park 1995; Schaefer 1991; Moedjono 1980; Unique).



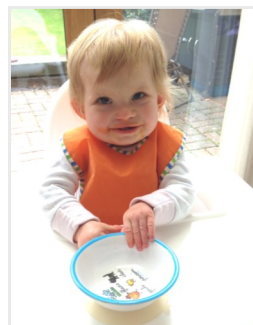Similarities

## Feeding

Feeding problems are common in babies and children with a chromosome disorder. In this group, breastfeeding was possible for some and in one case continued to over three years, but the information we have showed that 17/24 (71%) of *Unique* babies had difficulties with breastfeeding, with many parents saying their baby had difficulty latching on. Some babies also experienced episodes of difficulties with swallowing and choking during feeds. There was one report of a baby who struggled with both breast- and bottle-feeding and tired quickly due to hypotonia, and another of a baby whose feeding problems resolved after his tongue tie was snipped. Some babies were diagnosed with allergy to a milk formula, and in one case to soy, and were fed on replacement milk. It is not known whether a mild degree of reflux (bringing feeds back up) was interpreted as a milk allergy (Unique). Upon the advice of a dietician, a number of parents reported the successful use of fortified baby milk substitute to promote weight gain (Unique). A few babies also brought back up their feeds frequently and forcefully and were at risk of inhaling milk as it flushed up their food pipe. This is called gastro-oesophageal reflux disease (GERD) and can be helped by holding a baby upright for feeds and letting them sit in a semi-upright position afterwards. Your doctor can prescribe milks that are thickened and easier to keep down, and medicines that help feeds to stay down and act against the acid effect of stomach contents on the food pipe. If these measures do not work, it is possible to strengthen the valve between the food pipe and the stomach with a surgical operation called a fundoplication.

A number of *Unique* parents report that their child had problems with constipation; several families have found that laxative medications, such as Polyethylene glycol powder, have helped with symptoms.

We have one feeding report for a baby with significant heart problems; not unexpectedly, this child was fed by gastrostomy tube (G tube) direct to the stomach. Several other children have needed a gastrostomy tube; in at least one case it was successfully removed at the age of five years (Unique). Quite a few babies with tetrasomy 9p have a cleft palate (a split in the roof of the mouth), sometimes with a split in the upper lip as well, but feeding was even problem-free in one baby with a cleft lip and palate (El Khattabi 2015; Orye 1975). Typically, babies with a cleft lip or palate have greater feeding difficulties until their condition is stabilised or surgically corrected.



14 months

One adult we know of eats well, but seems to have problems with chewing and cannot suck through a straw [Unique].

“ He had trouble latching on to nurse. It was very minor and did not require treatment. ”

“ Difficulty swallowing and aspiration that cleared. Small size led doctors to believe there was a failure to thrive and a feeding tube was inserted. ”

“ GERD was present and severe food allergies. Oral medications for GERD were given. ”

“ He was an excellent breast-feeder for two years. ”

## Growth

Birth weights at term: Non-mosaic 2lb 11oz /1.21kg to 5lb 15oz /2.7kg

Mosaic 3lb 10oz/1.644kg to 8lb 8oz/ 3.856kg

Almost three quarters (15/21) of *Unique* children for whom we have information relating to growth, and 40% of children reported in the medical literature, had growth delay (El Khattabi 2015; Unique). For some this was transient, while for others the delay continued well into or throughout childhood. Indeed, there does not appear to be a clear link between growth delay before birth and childhood height, with examples of small-for-gestational-age babies growing into average-height children (Lloveras 2004), and others of babies of average birth weight later failing to thrive (Stumm 1999; Unique).

Height and body build are variable, with some adults short (5' 1"/1.55m in a girl of 19 years; an adult man the height of a 12-year-old) while others are of average height (5' 9"/1.75m in a boy of 16 years; 5' 11"/1.8m in a boy of 15); however, the data supplied to *Unique* does suggest that on average height and stature are generally below average. Body build also varies from stocky to slight, with more children described as slight or thin. We don't know whether children with tetrasomy 9p continue to grow in their 20s, as some with trisomy 9p do.

“ He is slight - to the amazement of those who know how much he can eat. ”  
- adult

## Development: sitting, moving, walking (gross motor skills)

Many babies and children are late to achieve their 'milestones' of sitting and walking and are helped by regular physiotherapy. There is a wide range of eventual ability, however, with some children acquiring mobility skills around the same age as typical children and others showing more obvious delay.



Among children from *Unique*, rolling over was achieved between three and 18 months; sitting between four months and four years (with most sitting by 12 months); crawling or bottom shuffling between six months and three years; and walking independently between 12 months and seven years (with approximately half walking by two years).

Mobility is affected by abnormal muscle tone and many children have low tone (hypotonia) or in a few cases high tone (hypertonia). Babies with low muscle tone at birth feel floppy to hold and have obvious head lag. Low muscle tone generally improves with maturity but may still be present in adults. Regular physiotherapy helps, and the use of orthotics such as support boots may also help increase mobility.

Eventual walking style also varies. While some achieve total mobility and learn to climb stairs (at least with a rail), to run, ride a bicycle, swim, and even ski, others retain an uneven and uncoordinated walking style and some rely on wheelchair use for long distances and outdoors. In general, it appears that those least affected or unaffected in early childhood are most likely to achieve normal mobility and sporting prowess as adults, while those children who have obvious mobility problems early on achieve a more limited degree of mobility. But a child

who walked first at seven years can walk long distances with other people as an adult and doesn't use a wheelchair [Unique].

**“At four months of age he was very much like a small baby still. He is much better today but still has low muscle tone.” - Age 2**

### **Development: hand use and coordination (fine motor skills)**

Development of hand use and hand-eye coordination are frequently delayed but the evidence from *Unique* is that adults are generally able to carry out daily personal care tasks. One family supplied a detailed timetable of their son's fine motor development: used a spoon at 13 months; placed three bricks in a tower at 21 months; used a knife and fork at 27 months; bounced and caught a ball at 27 months; drew a circle at 36 months; drew a person at 42 months. As an adult, this young man is able to dress and care for himself





but needs help with small buttons and shoe laces. Another young man in his twenties eats with a fork and spoon, and knows how to dress, but needs help.

“ Her fine motor skills are pretty good. She still prefers to feed herself with her fingers rather than using a spoon and fork - struggles more with a fork than a spoon. She is not yet at writing age so I'm not sure how she will manage with a pencil, but she works on 'pre-printing skills' at preschool. ” - Age 4

“ These skills have progressed quite rapidly over the past 12 months. He is currently still experiencing issues with fine motor skills e.g. fastening buttons, but hand-eye coordination is only slightly behind. ” - Age 12

“ A bit clumsy and struggles with fine work. ” - Age 26



8 years

## Development: toilet training

Data relating to the age at which children with tetrasomy 9p were toilet trained is limited; however, within the *Unique* series, for some toilet training was successful between 27 months and six years, but was not possible for all.

“ She uses the toilet and potty but rarely by request. ” - Age 4

“ Toilet trained by 2.5 years. ” - Age 19

“ Bed wetting and sometimes accidents resulting from laxative use for constipation. ” - Age 9

## Learning

The range of learning ability is very broad, but some degree of learning disability is to be expected. At one end of the spectrum are an adult with a professional career and children who attend mainstream schools, are able to follow the standard curriculum - sometimes with help for specific learning difficulties - and achieve a range of school-leaving qualifications. At the other end are children and adults with a moderate to severe learning disability. A statement or EHC plan allowing for 1:1 support has proved invaluable for many children.

The evidence on learning comes chiefly from *Unique* and shows that in general children with tetrasomy 9p have mild to moderate learning difficulties. Many learned to read, write and use a keyboard between the ages of five and 11 years. Age of first reading does not necessarily predict eventual ability as one of the highest achieving adolescents was a relatively late reader. Specific areas of high ability and specific learning difficulties occur and a common theme appears to be a facility for visual learning. Parents also mention that their child can at times be reticent to acquire new skills, becoming frustrated if they are unable to master them quickly, but through repetition and encouragement new skills are often mastered.

- An adult man enjoys practical work and has a good memory for some things, but cannot read and has no interest in writing. He was at a special school from two to 19 years, then a residential college for three years and is now finishing a part-time course at a local special needs college.
- A 19-year-old girl has a highly developed memory for people, upcoming events, lost or misplaced property and travelling directions. She is better able to learn practical tasks than academic tasks. She is extremely observant and interested in people. She can sign her name, copy most letters and write them with verbal prompts. She attended a mainstream primary and special secondary school.
- A 16-year-old boy who has attended a mainstream school with 1:1 support passed the United Kingdom school-leaver examinations in mathematics, science, and art & design and shows particular strengths in subjects where word use is minimised. He has a talent for abstract art and impressionism.
- One 15-year-old shows an excellent - even remarkable - long-term memory but has poor short-term recall and working memory. He is a strong visual learner and is good at mathematics. He has dyslexia which prevents avid reading but he listens to stories such as Harry Potter. His drawing and writing are normal. He attends a private school for students with normal intelligence but learning disability.
- A 13-year-old girl, attending a mainstream secondary school, is reading books for 8- to 10-year-olds and writing at a similar standard.



26 months

- Another girl, aged 10, has a very good memory and is able at English. She attends a special school where her learning is most helped by her determination, by observation of people and things around her and her good memory.
- A six-year-old girl also has a very good memory and is willing to learn but lacks concentration and confidence. She reads school books, can write her name, some letters and some numbers and can draw people and butterflies. She attends a mainstream school with additional support.

“ My four-year-old daughter attends an integrated preschool where about 70% of children have special needs and the rest are typically-developing. We went through a Special Education Review Committee process (an optional process for families of children who are eligible to start junior kindergarten - turning four within the calendar year). We declined the recommendation for a special education placement for junior kindergarten, and in the end have decided to delay junior kindergarten for another year. After that, we hope to send her to our local school for at least junior and senior kindergarten (she will be four/five and five/six in those years), where she will be with typically-developing peers and (we hope) will receive some additional support from an educational assistant and special needs assistant. She can get easily frustrated and distracted if she does not have immediate success with something, particularly fine motor skills, although this seems to be improving as she gets older. Although she is only young, she is showing some age-appropriate early literacy skills (letter and number recognition). She is a very physical and active child. She likes sensory experiences: painting, art-making, playdough, baking, that kind of thing. ”

“ My son was diagnosed with "specific learning disability", which means a disorder in one or more of the basic physiological processes involved in understanding or in using language - spoken or written - that may manifest itself in the imperfect ability to listen, think, speak, read, write, spell or do mathematical calculations. He goes to a standard school and is in a regular classroom with his peers. He is assigned a buddy who helps him with his tasks and he also works 1:1 with a special teacher to complete assignments. His assignments are different to those of his peers i.e. not as many/simpler questions. He has had occupational therapy, physiotherapy and speech therapy throughout his schooling. He currently only does occasional occupational therapy and weekly speech therapy. ” - Age 12

“ Socially he is quite capable, and is in a special educational program for the mildly impaired. He is persistent and very eager to learn: it eventually

happens, but at a delayed pace. His main areas of strength are reading and memorising and he is eager to learn new hands-on jobs. Our Early On process was very easy and the school district reached out to me proactively when he was a year old! Information was initially provided by my doctor. The doctor also proactively supplied information to the State. The Special Education Program he attends is called the Creative Learning Program and he is mainstreamed 30% of the day. Most academic activities are in the special education classroom; specials and more social activities are mainstreamed. He has had occupational, speech and physical therapies, but speech is the most intensive as he has severe speech apraxia. My advice would be to be an advocate for your child! If it doesn't feel right, don't accept it. No one knows your child as well as you do! ” - Age 9

## Speech and communication

The ability to speak and converse generally reflects learning abilities, so children who need greater learning support tend to be those who start speaking later and develop less complex language. Children whose learning ability falls within the normal range may show little or no delay in initially acquiring speech and language and go on to develop complex conversational skills and a broad vocabulary.

Information provided to *Unique* indicated that most [21/24] children had delayed speech and this could be linked to hearing loss (*see below*) and low muscle tone. A number of parents reported that even where speech was delayed there was a big improvement in speech later in childhood. First words have generally emerged between nine months and four to five years and linked words and longer phrases by 10 years, but not everyone acquires speech. There are wide differences between individuals in understanding, with understanding and expression on a par in some children while in others expressive skills outstrip receptive language or vice versa. Where individuals have no speech or very few words, communication has still been successful through signing, gesture, facial expression and assistive technology.

Even among the fluent speakers, some lack of clarity has tended to persist with a small cluster of families remarking on their child's disordered phonology and inability to discriminate between s, f, th and v sounds. An assessment by a speech therapist should be able to identify your child's specific difficulties allowing regular therapy sessions tailored to your child's specific areas of need. Speech therapy has proved beneficial to many *Unique* families.

“ He seems to understand a lot even though he can not communicate through speech. ” - Age 2

“ My daughter is a 'total communicator', using sign language, speech (words and word approximations), her communication device, gestures and vocalizations, often in the same sentence. She only says one or two words at a time. She has 40-50 signs, a couple of words that others can understand (mama, dada, her name) and about 30 word approximations made with only a few speech sounds. For example, she will say 'ba' for ball, bath, bus, bum, etc. She sees a speech therapist focusing specifically on speech and working on oral motor challenges via a method called PROMPT biweekly. Her communication device is an iPad with the software Speak For Yourself. She started using that a month ago and is making progress with it. ” - Age 4



3 years

“ He speaks in complete sentences but most people can't always understand what he's saying. ” - Age 12

“ He has 3-5 signs, 3-6 different types of grunts, uses augmentative/ alternative communication device (ACC) pictures from a small booklet (mostly food), and points at things he wants. He also grabs my hand and "shoos" me away for things he doesn't want. ” - Age 3

“ It varies depending on the excitement/sadness/anger/importance level and how quickly or urgently he wants to get his point across. He uses mostly full sentences with poor grammar e.g. “me no like that”. ” - Age 12

“ He uses normal sentence structures with a wide ranging vocabulary, including some specialist words e.g. with respect to cycling, skiing & work. ” - Age 26

## Behaviour

The evidence from *Unique* shows that children and adults with tetrasomy 9p are loving, happy, caring individuals and generally speaking have an open and sociable temperament. Some are somewhat shy while others may be over-friendly with strangers. There is no obvious relationship between behaviour and learning ability, although those children with greater functioning difficulties will be in an environment where less is expected of

them. Individuals do have difficulties in interpreting and responding suitably to social cues and this is most apparent in those who are in a mainstream environment outside their family. They may well be popular with their peers but find it easier to relate to people older or younger than themselves. Within the family, children may experience difficulties with frustration, temper tantrums, depression and in accommodating their brothers and sisters, while some children may find it difficult to entertain themselves and require a greater degree of 1:1 attention. Early access to advice, input and therapy will help those families who find themselves in difficulties with their child's behaviour. One child has a diagnosis of attention deficit hyperactivity disorder (ADHD) but methylphenidate (Ritalin) medication controls restlessness and inappropriate comments. Another child with frustration difficulties within the home has been helped by a behaviour chart and a clear reward system.



7 years

“ A very outgoing personality who copes quite well socially. She can approach strangers but will withdraw or proceed depending on the reaction she gets. She does pick up on social cues and is very keen to help. She will initiate assistance and predict your needs. ” - Age 19

“ Happy! So happy, contented, totally in love with his family, affectionate and sweet-spirited. ” - Age 3

“ My daughter is a very happy, easy-going, loving, charming and friendly child. She adapts easily to new situations and people. She is not easily overwhelmed. She is easily soothed. She is very sociable and a motivated communicator. ” - Age 4

“ He is a friendly child with a fantastic sense of humour. ” - Age 12

“ He is such an amazing little boy. He is constantly on the go! He loves to be up high and that includes being in someone's arms. He loves his siblings and has a special bond with his Daddy. He is happy but quiet and beginning



to show some shyness around strangers. He will engage but is not super expressive without being stimulated. He always checks in though (looking to see if you're looking at him). ” - Age 2

“ A likeable personality, very affectionate. Most of the time he is lovely and continues to be well-behaved outside the family environment. He can be rather obsessive at times, e.g. tidiness, washing clothes etc. Socially, he is popular but his immaturity makes it difficult for him to have close friendships with people of his own age. ” - Age 16

“ A very sweet, loving child, he has an acute perception of people's true selves. ” - Age 15

“ He is sociable but it takes time to establish relationships, though they can become very positive. He is vulnerable without adult supervision and can be volatile. He takes an interest in the world around him and people generally like him. He is law-abiding and reliable. ” - Age 26

“ Socially, she gets on brilliantly with strangers; gets on OK with the family until she can't do something she wants. ” - Age 10

“ Very friendly, loves to stop and chat with people. Happy and cheerful and her happiness rubs off on everyone. ” - Age 6

## **Other behaviours**

A 20-year-old female who was diagnosed with mosaic tetrasomy 9p at the age of six years due to her facial appearance and developmental delays (including deficiencies in her speech and language skills and impaired social communication) was subsequently diagnosed with an autism spectrum disorder (ASD) (Chen 2012).

ASDs include autism and Asperger's disorder and are associated with impaired social skills, problems with communicating, and a need to carry out repetitive and restrictive behaviours from which an individual derives comfort. A related but distinct disorder called obsessive-compulsive disorder (OCD), which may co-exist alongside an ASD or manifest separately, describes an individual who experiences anxiety that can be relieved to some degree by carrying out specific, repetitive rituals e.g. obsessive hand-washing, repetitive counting/checking. Those with OCD don't derive pleasure from these routine behaviours, but fear that something bad will happen if they don't complete them.

A single gene located on chromosome 9 at region 9p24 is thought to be linked to ASDs and OCD (Martinez-Jacobo 2015; Kantojarvi 2010). There is



anecdotal evidence from *Unique* of other people with tetrasomy 9p exhibiting ASD and OCD behaviours but a causal link has not been established, and some expert opinion doubts any link as long as other known or as yet unknown causes have not been fully investigated [El-Khattabi, *personal communication*].

“ He is inflexible and needs to be prepared in advance for new experiences. He is highly organised and can be obsessive e.g. he will pack for a holiday several weeks in advance. He likes routine and doesn't like spur of the moment changes in plan. He gets worried and anxious. ” - Age 26

## Sleep

Almost half of *Unique* families mention that their child experiences some degree of sleep disruption, although the reasons are not yet well understood. Some children have difficulty getting to sleep or do not sleep for long periods of time and wake repeatedly in the night. A few experience sleep apnoea, a sleep disorder that is characterized by pauses in breathing or periods of shallow breathing during sleep. Some parents also say that their child needs their comforting presence at bedtime in order to fall asleep and may reach or call out for them in the night.

It can be challenging for all the family when a child does not settle well to sleep or is not getting enough good quality sleep. Our [Sleep problems in children with chromosome disorders](#) guide, in the practical guides for families section of our website, has further information.

“ Her sleep has gotten much better lately. As an infant she wouldn't nap during the day for more than 30 minutes at a time. As she got older she developed the capability for uninterrupted daytime sleep (still naps for 1.5-2 hours a day). She is able to soothe herself to sleep when she wakes at night now (still typically once or twice a night). ” - Age 3

“ Woke-up once almost every night between the ages of 18 months and 16 years, triggered by a house move. ” - Age 26

“ She has sleep apnoea and had breathing difficulties (a stridor) post op when she had her lip repaired, plus a tug of some nature that was restricting her breathing. She has had two sleep studies and the second one concluded that everything is improving as she grows. ” - Age 16 months

## Health concerns

### ■ Joint abnormalities

Joint abnormalities are a known feature of tetrasomy 9p at birth, with

extremely loose (hyper-mobile) joints (elbows, wrists, knees, hips) often observed (El Khattabi 2015; De Azevedo 2003; Tonk 1997; Leichtman 1996; Linuma 1994; Cavalcanti 1987; Shapiro 1985; Moedjono 1980; Unique). This means babies and children can move their limbs into positions others find impossible. While this may cause no problems, hyper-mobility is sometimes associated with pain and stiffness in the joints and muscles, joints that dislocate (come out of position) easily and injuries including sprains. Children with very loose joints may need additional braces (supports, splints) before they are able to walk. In some cases, joints are unusually tight and may require surgery and tendon lengthening to extend their range of movement.

Some children have a degree of hip dysplasia, in which the hip joints are easily dislocated. This may be apparent at birth or develop later. In either case it is treated with splinting and if necessary immobilisation in plaster and possibly surgery (Eggermann 1998; Papenhausen 1990; Unique).

## ■ Spine

Some babies are born with or develop a spinal curvature, either curving sideways (scoliosis) or forwards (kyphosis). Underlying the curve may be abnormalities of muscle tone and in some cases the bones of the spine (vertebrae) may be fused together or incorrectly formed. The curvature can be treated with physiotherapy and exercises, or a support brace may be needed. If the curve becomes marked it is possible to straighten the spine using rods (Dhanda 2002; Stumm 1999; Verheij 1999; Dutly 1998; Melaragno 1992; Sjöstedt 1989; Balestrazzi 1983; Moedjono 1980; Unique).

## ■ Eyesight

Known difficulties include a squint (strabismus), including exotropia (divergent squint), which is frequently intermittent, and lack of stereoscopic vision (teaming of the eyes), causing loss of 3D vision and depth perception. Strabismus may be treated with patching, glasses, exercises or surgical correction. In at least one *Unique* child, the squint self-corrected by the age of six years.

There are 12 cases of marked short-sight and one child and two adults are registered as partially-sighted. Other children have sunken eyes; lazy eye (amblyopia); uncontrolled eye movements (nystagmus); an abnormal development of the iris; damage to the part of the back of the eye known as the chorioretinal area; a single eye; long sight; and cataracts (El Khattabi 2015; Lloveras 2004; Cazorla Calleja 2003; Dutly 1998; Tonk 1997; Papenhausen 1990; Balestrazzi 1983; Cuoco 1982; Garcia-Cruz 1982; Abe

1977; Orye 1975; Unique). In at least one child the development of good vision was affected by raised pressure within the brain (Stumm 1999).

## ■ Hearing

A mild to moderate hearing loss appears to be common with almost three quarters (16/22) of *Unique* members affected. Hearing tests at birth are often normal, with hearing loss developing due to glue ear, made worse for a few children by unusually narrow external ear canals and excess wax in the ear canal, in a few cases (Sepahi 2010; Tonk 1997; Melaragno 1992; Orye 1975, Unique). Glue ear is typically treated by inserting aeration tubes (grommets) into the eardrum and this surgical operation may need to be repeated. Normal hearing may not be achieved with aeration of the space behind the eardrum (middle ear) and hearing aids may help as a temporary or longer-lasting measure, although this appears to be uncommon. As children are at risk of speech delay, parental concerns should be acted on early and home- or school-based therapy provided.

“ She had glue ear for many years, which was treated with the insertion of grommets. She has no problems now. ” - Age 29

“ Mild to moderate hearing loss. Narrow ear canals. Problems with wax build-up. ”- Age 26

## ■ Hands and feet

The hands are sometimes affected by tetrasomy 9p with features such as bent and shortened fingers and thumbs, occasionally overlapping each other or joined by a bridge of skin and tissue, as well as abnormal or missing fingernails. The tips of the fingers may be noticeably shortened and even missing. The *Unique* experience is that these features are rare, do not generally affect the way a child uses their hands and only need correction when hand use is affected.

A wide variety of specific abnormalities of toe and foot position are also a common feature of tetrasomy 9p. By far the most common is pes planus (flat feet), which affected 11/14 children in the most recent 2017 *Unique* survey. Other conditions may include pes cavus ('claw foot'), rocker bottom feet (the sole is curved without an instep, like a chair rocker), pes planovalgus (the feet are flat and stick out), pes equinovarus (club feet, with the foot turned inwards, the soles pointing towards each other), pes adductus (so-called 'banana foot', where the toes point inwards) and other less common positions. Babies born with feet affected in this way should receive specific physiotherapy which may avoid the need for corrective

surgery and plaster casting. Treatment is tailored to the individual child and in some cases surgical correction will best enhance eventual mobility. Several parents mention that their child's nails are unusually thick.

“ His fingernails and toenails curve over the tips and at the nail bed they are more bulbous. ” - Age 12

## ■ Head and brain

Many babies were born with a very large soft spot (fontanelle) or wide spaces between the bony plates of the skull. The front fontanelle was also often slow to close and in one child was still open at age four (Unique). Additionally, some babies have an unusual head shape or size ('strawberry skull'; asymmetric head shape; microcephaly (small head); macrocephaly (large head); brachycephaly (the head is disproportionately wide ear-to-ear compared to the measurement from front to back). One *Unique* baby was two-years-old before he was able to support his head.

In some babies and children, a structural abnormality of the brain was found, much more commonly among youngsters with a non-mosaic form of tetrasomy 9p. Structural anomalies such as enlarged ventricles (fluid-filled spaces) within the brain, absence or underdevelopment of the corpus callosum (the bundle of nerve fibres that links the brain's two hemispheres) and Dandy Walker, may be detected on prenatal ultrasound. The Dandy Walker anomaly is a cyst in the balance-control part of the brain (cerebellum) that is involved with the fourth ventricle, one of the fluid-filled spaces within the brain. This may interfere with the body's ability to drain cerebrospinal fluid from the brain, resulting in hydrocephalus, a build-up of fluid within the brain (see below) (El Khattabi 2015; Nakamura-Pereira 2009; Lloveras 2004; Cazorla Calleja 2003; Stumm 1999; Andou 1994; Melaragno 1992; Balestrazzi 1983; Cuoco 1982; Garcia-Cruz 1982; Peters 1982; Ghymers 1973; Unique).

Other brain anomalies include: under-development of the grey matter both in the cerebellum and the cerebral hemispheres; lissencephaly (smooth rather than ridged brain surface); pachygyria (where the 'hills' in the undulating landscape of the brain's surface are unusually large); and polymicrogyria (where the 'hills' are many and small) (Cazorla Calleja 2003). The most frequent problem that occurs after birth is hydrocephalus, usually requiring a shunt to drain the excess cerebrospinal fluid and relieve pressure on the growing brain. The build-up of hydrocephalus may occur even when a child's head is unusually small. The experience of treatment for hydrocephalus is challenging for families, but one *Unique* family whose baby

son had a shunt fitted at six months reported that at 12 months old he 'has come a long way and is developing very well, even though he is still behind'. Despite the high rate of brain anomalies, only one child has been described as having had a seizure (not repeated) and among *Unique* members only one has reported a few cases of absence seizures (Andou 1994; Unique). Some data suggest that the over-expression of genes located on 9pter-9q12 may be responsible for the abnormal migration of neurones (brain cells) during the development of the brain (di Vera 2008).

## ■ Teeth

Children with rare chromosome disorders are at risk for dental problems. In this group, many children were affected and at least one child with abnormal enamel has been reported (El Khattabi 2015; Unique). Both crowding (with mal-positioning) and failure of milk teeth to fall out as permanent teeth came through were common, and children had a high rate of dental extractions. One child only lost her first milk tooth at nine-and-a-half years. In two children the milk teeth were late to emerge. A high standard of dental care is important to minimise damage by decay and erosion (by grinding) (Garcia-Cruz 1982; Peters 1982; Unique).

“ Grinds his teeth, particularly when tired. A brace would have been useful to straighten his teeth, but the dentist and I can't see him wearing one. He has no fillings, no extractions and no decay - but he doesn't like sweets or fizzy drinks. ” - Age 26

“ He has decay from late diagnosis of reflux. ” - Age 12

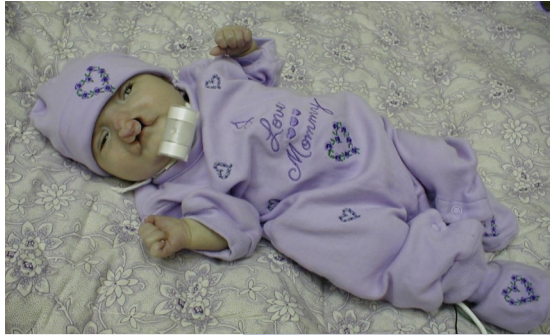“ He has extremely crooked teeth and an overbite. ” - Age 12

## ■ Palate

Abnormalities of the roof of the mouth are relatively common, affecting 32% of babies reported in the medical literature (El Khattabi 2015) and 34% of *Unique* children. Abnormalities can range from those invisible to the casual onlooker (a high palate, a divided uvula, the projection of soft tissue that hangs down from the back of the mouth) to an obvious defect with a divided upper lip and a large gap in the roof of the mouth. More serious defects were much more common in those with a non-mosaic tetrasomy 9p. A cleft lip and palate is caused by an error in fusion when the fetus is forming: the lip and palate fuse from pieces that start on opposite sides of the head. The lip fuses around weeks six to seven and the palate at around 12 weeks. A cleft occurs when the pieces come round but do not join. A cleft

lip/palate causes difficulties in feeding and speech production. Surgical repair eases these and may eliminate them, as was the case for several *Unique* children.

“ She has a high palate and is unable to coordinate a bottle or pacifier (dummy). There were breast- and solid-feeding difficulties due to high palate and low tone. ” - Age 1



Above: before lip and palate repair



Above: four months



Right:  
14 years



Right:  
one year

## ■ Heart

A structural heart anomaly has been found in around one third of children and adults with mosaic tetrasomy 9p (El Khattabi 2015). The rate among *Unique* members was similar at 35%, but half of these babies were born with complex, serious heart problems.

There were a wide variety of heart problems and outcomes. Among *Unique* members, in one adult the heart is positioned to the right instead of the left of the chest (dextrocardia), without any effect on function or development.

One youngster has insufficient mitral valves, a condition in which the valve between the upper left heart chamber and the lower left chamber does not close well enough to prevent back flow of blood when the ventricle contracts; this usually needs correction with surgery. A further youngster had mitral valve prolapsed (MVP), in which the flaps of the mitral valve do not work well and allow back-flow of blood from the ventricle to the atrium. This condition occurs in 1:20 people in the general population and often does not need treatment. Several children have a heart murmur, which was not believed to be of concern in at least one case, while one child had an enlarged main pulmonary artery, which was being monitored.

Among the cases reported in the medical literature, seven babies had a persisting feature of foetal circulation known as persistent left superior vena cava, as did two *Unique* children. This usually causes no problems but can be associated with other heart problems. In this group, five babies had additional heart problems; unfortunately, none of these babies survived the newborn period. Other babies had complex heart problems including holes between the upper and lower heart chambers (atrial septal defect (ASD); ventricular septal defect (VSD)); narrowed or thickened heart valves; and further persisting features of foetal circulation including most prominently a patent ductus arteriosus (PDA) that were not compatible with life. However, not all babies with heart problems requiring surgical correction had a gloomy outcome. One *Unique* baby was born with multiple heart problems that were corrected surgically at one week of age and a baby with a VSD and PDA, repaired at four months, was doing well at the age of three (Tang 2004; Lloveras 2004; Cazorla Calleja 2003; Dutly 1998; Tonk 1997; Papenhausen 1990; Calvieri 1988; Melaragno 1992; Orye 1975; Ghymers 1973; Unique).

“ She has a benign heart murmur and enlarged main pulmonary artery, which is being monitored. ” - Age 4

“ He has a persistent left vena cava but no problems or effects. ” - Age 3

“ She had a PFO, which is now closed at 16 months. She has a slight variant in an artery from her heart to her brain in that the "Y" fork has not quite formed correctly. We have been advised this is not serious and should not cause her any issues. ”

## ■ Minor anomalies of the genitals

Minor anomalies in boys with a mosaic tetrasomy 9p are relatively common, but girls are much less likely to be affected. Within the *Unique* series, eight boys were born with un-descended testicles (cryptorchidism). The testicles



begin their descent from the abdomen during foetal life and have usually arrived in the scrotum by birth. In a significant number of boys without any chromosome abnormality, that journey is not complete by birth but is completed within the next few months. When descent does not occur, the testicles can be brought down in a surgical operation and anchored in the scrotum. Natural descent occurred during the first year of life in one boy. Three boys were born with a small penis (micropenis) and one boy had a buried (hidden) penis, which was surgically corrected at two and a half years. One adult, otherwise normal, had no genital anomalies but low levels of sperm (oligospermia). Among those with a non-mosaic form of tetrasomy 9p, more babies were affected and generally more severely (McAuliffe 2005; Tonk 1997; Melaragno 1992; Sjöstedt 1989; Balestrazzi 1983; Garcia- Cruz 1982; Peters 1982; Abe 1977; Unique). Many of these minor anomalies can also be seen in children without tetrasomy 9p and are not of major concern.

## ■ **Skeleton and bones**

A variety of unusual features of the skeleton have been reported, including: underdeveloped shoulder blades; missing ribs in four babies; a prominent collar bone; underdevelopment of collar bones causing marked sloping of the shoulders; winged scapula; and uneven skeletal growth with one side of the body larger than the other, a condition known as hemihypertrophy (El Khattabi 2015; Stumm 1999; Dutly 1998; Calvieri 1988; Balestrazzi 1983; Cuoco 1982; Garcia-Cruz 1982; Unique).

## ■ **Kidneys**

The kidneys were affected in more than one baby/child in three with mosaic tetrasomy 9p in the medical literature. Among *Unique* members problems were less common. One child had repeated urinary infections that needed preventive treatment with antibiotics. In several other children the kidneys were small or large, but without functional implications, and one child had difficulty regulating levels of salt in the blood.

Among babies reported in the literature, cystic kidneys occurred once. These fluid-filled sacs form in the kidneys, usually during foetal life. A solitary cyst may not interfere with function unless it is large, but multiple cysts may stop the affected kidney from working. A multi-cystic kidney may be removed if it is causing discomfort. The important thing is to ensure optimal functioning of the other kidney.

Hydronephrosis (enlarged kidneys) occurred in three cases and horseshoe kidneys in one – the bottom points of the two usually separate kidneys are

joined, creating a U (horseshoe) shape. In itself this is not harmful and around one third of children with horseshoe kidney have no symptoms and may need no treatment. However, a horseshoe kidney can increase the risk of urinary tract infections. One child had a single kidney (El Khattabi 2015; Sepahi 2010; Tang 2004; Cazorla Calleja 2003; Dutly 1998; Melaragno 1992; Balestrazzi 1983; Ghymers 1973; Unique).

## ■ Spine

A sacral dimple (dimple or hole in the skin just above the crease between the buttocks) is also sometimes seen, but is more common in babies with non-mosaic tetrasomy 9p than in babies with the mosaic form. The sacral dimple may be shallow so you can see the base, but stools can collect there before your child is toilet-trained, so keeping it clean and protected is important. A sacral pit may be deep and even connect to the spinal canal or the colon. If there is any concern about this, your baby's spine will be imaged, usually with ultrasound or an MRI scan (Tonk 1997; Calvieri 1988; Unique).

## ■ Skin lesions (pilomatricomas)

Benign (non-cancerous) skin lesions known as pilomatricomas, pilomatrixoma, trichomatricoma or 'calcifying epithelioma of Malherbe', have been found in some people with tetrasomy 9p, including four *Unique* members. Pilomatricomas arise from the cells at the base of hair follicles, the specialised structures from which hairs grow, and tend to be found on the head or neck, although they can also sometimes arise on the arms, torso, or legs. They are skin or purplish in colour, with white areas due to calcium deposits that make them feel surprisingly hard to the touch. Pilomatricomas are harmless, but occasionally they may burst and release a white and yellow chalky fluid. Very occasionally they can become sore and inflamed if they become infected, so picking and squeezing them should be avoided.

Several *Unique* members have had pilomatricomas surgically removed (El Khattabi 2015, Unique). One otherwise healthy 41-year-old man with skin lesions was only found to have mosaic tetrasomy 9p as a result of cytogenetic analysis carried out to investigate their cause (Papoulidis 2012).

“ She has had two pilomatrixoma removed - one on her cheek and one on her forearm. ” - Age 4

## ■ Autoimmune disorders

A six-year-old girl with mosaic tetrasomy 9p was recently reported to show signs of inflammatory myositis (chronic muscle inflammation accompanied by muscle weakness) and lupus-like features (an autoimmune condition which occurs when, for as yet unknown reasons, the immune system starts to attack and damage healthy cells, tissues and organs). It has been suggested that the additional copies of genes related to the correct functioning of the immune system that may be present in some cases of mosaic tetrasomy 9p, can lead to the immune system becoming over-active. Upon diagnosis, appropriate treatment with corticosteroids and mycophenolate [mofetil] resulted in the total remission of all symptoms (Fremond 2015).

Three cases of a confirmed autoimmune disorder have been reported to *Unique*. A girl had painful polyarthritis, Raynaud's disease, positive anti-cardiolipin antibody, undiagnosed intermittent abdominal pain, was often sick and seems to have poor immunity. There was also a report of a girl with juvenile arthritis, which is characterised by painful swollen joints. In this case the cause was unknown (idiopathic). A 9-month-old was diagnosed with type 1 diabetes.

## ■ Generally well being

The majority of *Unique* families describe their child's general state of health as "healthy" or "very healthy". Several children were prone to colds and other respiratory infections, particularly as babies, and had trouble clearing their lungs. There is a report at *Unique* of a child with relapsing pain, fatigue and skin symptoms.

## ■ Other medical concerns

Missing gallbladder (Dutly 1998)

Umbilical & inguinal hernia (Henriques-Coelho 2005; Dutly 1998; Eggermann 1998; Cavalcanti 1985; *Unique*)

Tracheomalacia, the cartilage that supports the trachea (windpipe) is soft meaning that the trachea partly collapses, especially during increased airflow (*Unique*)

Blocked or absent tear ducts (*Unique*)

Anaemia (*Unique*)

### Seen in non-mosaic form only:

Under-developed lungs, possibly due to diminished fetal movement, sometimes with unusual lobe pattern and bronchopulmonary dysplasia

(Henriques-Coelho 2005; Deurloo 2004; Dhanda 2002; Park 1995; van Hove 1994; Shaefer 1991)

Malrotation of part of the intestine (Dhanda 2002; Park 1995; van Hove 1994)

Diaphragmatic hernia (Henriques-Coelho 2005; Wisniewski 1978)

Underdeveloped bladder (Dhanda 2002)

Biliary atresia (Henriques-Coelho 2005) Inflammation of bile duct to the liver, causing blockage of the flow of bile and jaundice. The condition is treated through an operation called Kasai-portoenterostomy, in which a loop of bowel is used to form a duct to drain bile from the liver.

## Puberty

The information we have relating to puberty in children with tetrasomy 9p is limited, but we do know that for five *Unique* children, two experienced puberty at the expected age and three went through puberty later than is typical. For most it seems that puberty proceeded as expected with no cause for concern, but one girl found it difficult to cope with menstruating and had a hormonal intrauterine device (IUD) fitted to stop her periods.

## Adulthood

The evidence from *Unique* is that some people with tetrasomy 9p may become independent enough to live in a sheltered setting or independently. Several adults have undertaken work, either in paid employment or in a voluntary or work experience setting (Unique).

“J wakes around 6:30 and can shower herself but needs help with the taps. She chooses her own clothes and dresses herself and catches transport to her post-school program three times a week. When she is home she likes to swim in the pool, dig in the sand tray or draw on her paper. One day a week she goes to drama and then has afternoon tea with her friends. J generally goes out to dinner on Friday night and has a dance where there is a band playing. J has had work experience in a shop and a cafe and lives part-time with a carer in her own home and part-time with me in my home.” - Age 29

“E attended Special School from age two to 19 and a residential special needs college from age 19 to 22. This was the best decision we made as he has made significant progress in all areas and gained in confidence, enabling him to live life to his full potential.

E is now living in a small residential care home with four other lads of a similar age with 24/7, one-to-one care. He is always busy and happy to go

back after home visits. E enjoys life to the full. ” - Age 28

“ On a school day M gets ready for school by herself. Sometimes once she is in school she has a rough time with anxiety and needs me to pick her up, but for the most part she does okay at school. She does not like change and doesn't like to try to do new activities as they tend to make her anxiety problem rise. For the most part M has more good days than bad days since she started taking medicine for her depression. At times she claims she is an adult but she acts like she doesn't want to be an adult.” - Age 19

## **What do children and adults with tetrasomy 9p enjoy?**

There has been no formal study of this, but in *Unique's* experience children with tetrasomy 9p particularly enjoy social and sporting activities, especially when family is involved.

“ She enjoys going to the park, to music and gymnastic class, to her preschool, playing with play doh, stickers, her play kitchen and toy food, watching Peppa Pig, spending time with friends and family, colouring/art-making, reading books...she enjoys a lot of activities. ” - Age 4

“ Playing ANY sport..... loves sports! ” - Age 9

“ He obsesses with hockey, would watch it or play it non-stop if he could. He doesn't enjoy school because it's hard for him and he doesn't socialize well and would prefer to be at home. ” - Age 12

“ Likes physical activities: horse riding, swimming, football, play-fighting, walking, interacting with other people, TV, music. Does not like arts and craft-type activities. ” - Age 28

“ She likes rolling around on the floor with her brothers; being around her brothers is often the only time she makes sounds. She plays a game of taking people's glasses and hats off, or grabbing their nose, when they hold her, which makes her smile. ” - Age 1

“ He does not like loud noises or things that are unfamiliar. He loves anything his big brother does. He also loves bubbles, motorcycles, and water. ” - Age 3

“ Climbing! He loves to climb! ” - Age 1

“ She is a loving, giving girl and very interested in people and their lives. She loves to go shopping and swimming and bowling. ” - Age 29

## What is the outlook? One adult's story



J is now 26-years-old and continues to make progress, though we as parents do not necessarily see all the steps. Supported by Real Employment, a local scheme for adults with learning disabilities, he now has a part-time job at the Co-op supermarket in a village nearby. He started on two shifts a week unpaid and has worked his way up to 9 hours a week, fully paid. He has joined the company pension scheme and really enjoys his job and feels that he is a valued member of the team. His colleagues are friendly and he is included in social events such as meals out at Christmas. His duties

are to unload the deliveries and work in the stock room. He also works in the shop, shelf-filling and checking for items which are past their sell-by date and in this regard he is very thorough! He even comes home and checks through my cupboards. He was delighted to receive a £5 voucher from the manager recently, in recognition of his customer service skills: he had assisted a lady who was struggling with her toddler and her shopping by helping her to the till and then taking her shopping to the car. He needs time to accustom himself to a new challenge, but with support soon grows in confidence. He is 100% reliable and always punctual. He was so proud when he received his uniform and in particular his company name badge. The development of his self esteem, the acquisition of new skills and the opportunity to meet new people in a safe environment have been real positives from this workplace opportunity. It is so important to meet people beyond the family unit. Real Employment has recently approached him and the Co-op to make a short film to raise aspirations in young people in respect of gaining employment. We were delighted that he had the confidence to agree. In terms of hobbies, he is an avid Sheffield Wednesday fan, and can tell you all the latest football news. He watches a lot of television and is interested in sport, quiz shows, and "Top Gear". He keeps up with the news and weather, local and national, via the television and the internet, which he also uses to keep up-to-date with sports news, especially football. We have also taught him to ski: much patience was required! He does not have the best technique in the world, but he is a strong young man with a very strong snow plough, who happily skis the full mountain on red runs!!

On the negative side, we are experiencing some difficulties with him leading a healthy lifestyle. The word moderation is not on his radar in terms of food and drink. He will eat a pound of cheese rather than make a sandwich, snack on four pork pies and he drinks more alcohol than is good for him. We were trying to promote some financial independence, but have had to go back to fully managing his money and giving him small amounts of cash. He is frustrated by the lack of a girlfriend and the fact that he can't lead the same independent life as his 21-year-old sister.

# Inform Network Support



Understanding Chromosome & Gene Disorders

## Rare Chromosome Disorder Support Group

The Stables, Station Road West, Oxted, Surrey RH8 9EE, United Kingdom

Tel: +44(0)1883 723356

info@rarechromo.org | [www.rarechromo.org](http://www.rarechromo.org)

### Join Unique for family links, information and support.

Unique is a charity without government funding, existing entirely on donations and grants. If you can, please make a donation via our website at [www.rarechromo.org](http://www.rarechromo.org) Please help us to help you!

## Facebook

Tetrasomy 9p [www.facebook.com/groups/230460943817836](https://www.facebook.com/groups/230460943817836)

Tetrasomy 9p & 9q [www.facebook.com/groups/Tetrasomy9p](https://www.facebook.com/groups/Tetrasomy9p)

Speak for Yourself FB group [www.facebook.com/groups/273873326092019/](https://www.facebook.com/groups/273873326092019/)  
& [www.speakforyourself.org/](http://www.speakforyourself.org/)

*Unique* mentions other websites to help families looking for information. This does not imply that we endorse their content or have any responsibility for it.

This information guide is not a substitute for personal medical advice. Families should consult a medically qualified clinician in all matters relating to genetic diagnosis, management and health. Information on genetic changes is a very fast-moving field and while the information in this guide is believed to be the best available at the time of publication, some facts may later change. *Unique* does its best to keep abreast of changing information and to review its published guides as needed. It was compiled by *Unique* and reviewed by Professor Fionnuala McAuliffe, University College Dublin and National Maternity Hospital, Republic of Ireland and by *Unique's* chief medical advisor, Professor Maj Hultén BSc PhD MD FRCPATH, Professor of Reproductive Genetics, University of Warwick, UK. 2007 (PM). Revised by *Unique* and reviewed by Dr Laïla El Khattabi, Cochin Institute, Paris, France in 2015 (PM/CA) (V2) & 2018 (CA) (V3.2).

**Copyright © Unique 2018**

Rare Chromosome Disorder Support Group Charity Number 1110661

Registered in England and Wales Company Number 5460413