



Understanding Chromosome & Gene Disorders

# 8p inverted duplication & deletion



rarechromo.org

## Inverted duplication & deletion of 8p

Inverted duplication and deletion of 8p, known as **inv dup del 8p**, is a rare genetic condition that is estimated to occur once in every 10,000-30,000 births. In people with inv dup del 8p, there is both an extra copy (**duplication**) of part of the genetic material that makes up one of the body's chromosomes - chromosome 8 - and a missing copy (**deletion**) of another part of chromosome 8.

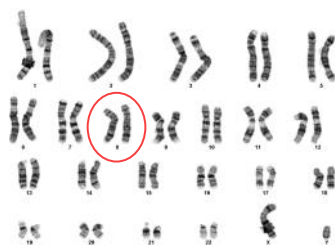As with other chromosome disorders, having an extra piece and missing piece of genetic material may cause birth defects, affect the development and intellectual abilities of a child and be associated with a range of other individual features, to a varying degree. The majority of cases of inv dup del 8p have not been associated with any life-threatening conditions (García-Santiago 2015; Akkurt 2017).

## Background on chromosomes

Our bodies are made up of trillions of cells. Most of these cells contain a set of around 20,000 different **genes** that carry the instructions that tell the body how to develop, grow and function.

Genes are carried on structures called **chromosomes**, which consist of a complex chemical called **DNA**. Chromosomes (and hence genes) usually come in pairs with one member of each chromosome pair inherited from each parent.

A normal cell in the body has 46 chromosomes. Of the 46 chromosomes, two are a pair of sex chromosomes: two Xs for a girl and an X and a Y for a boy. The remaining 44 chromosomes are grouped into 22 pairs and are numbered 1 to 22, approximately from largest to smallest.

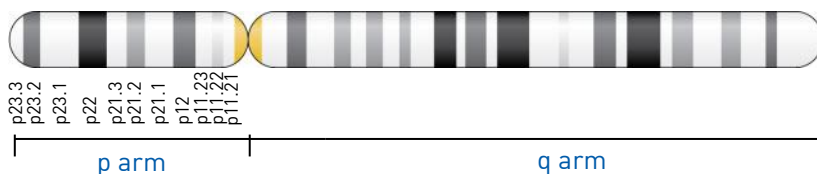

Chromosome pairs 1-22,  
X and Y (male)

Chromosome 8 pair circled in red

## Looking at chromosome 8

Chromosomes can't be seen with the naked eye, but if you stain them and magnify them under a microscope, you can see that each one has a distinctive pattern of **light** and **dark** bands. You can see the banding pattern for chromosome 8 in the image below.



Each chromosome has a short (**p**) arm (from *petit*, the French for small) and a long (**q**) arm. Bands are numbered outwards starting from the point where the short and long arms meet (the **centromere** (marked in yellow)). A low number such as p12 is close to the centromere. Material closer to the centromere is called **proximal**. A higher number such as p23 that is further from the centromere and closer to the tip of the chromosome is said to be in a **distal** region. The term **cen** is used to indicate a location that is very close to the centromere, while **ter** (for terminal) indicates a location that is very close to the end of the p or q arm.

## Chromosomal changes

Changes to the structure of chromosomes such as inv dup del 8p occur most often during the **cell divisions** that lead to the creation of egg or sperm cells. During this process, each arm of each of the 46 chromosomes first splits lengthwise into two strands that are held together at the centromere. The chromosomes then arrange themselves in 23 pairs, with pairs lying alongside each other, apart from the sex chromosomes X and Y which attach to each other at one end. Segments of DNA are then exchanged in a process known as crossing-over (**recombination**) and the chromosome strands are held together at the crossing points (known as **chiasmata**). The chromosome pairs 'recognise' each other because they are similar. However, where the DNA of the chromosome is repeated at close intervals, the repeat may pair with its partner on the same chromosome, instead of the repeat on the other chromosome, and "mistakes" may occur, leading to parts of a chromosome (s) being lost, duplicated and/or becoming rearranged.

Chromosomal rearrangements like this involving chromosome 8p are relatively common due to the presence of two olfactory receptor gene clusters (copies of genes involved in perceiving smell). Most of the DNA that makes up chromosome 8p is present as a unique sequence, but the presence of these gene clusters results in two sections where the DNA sequence is repeated at close intervals. These repeated sections are in a proximal part of 8p23.1 called **REPP** and a more distal part of 8p23.1 called **REPD** (see diagram on page 4) and can act as weak points in the chromosome meaning it is more likely to break there. The presence of REPP and REPD also means the replication machinery is more likely to "trip up" during the production of the sperm or egg cell resulting in complicated chromosomal

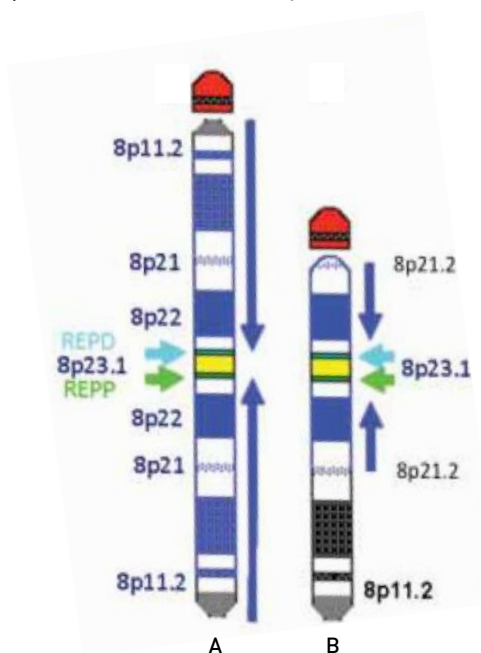
## Sources

The information in this booklet is drawn from the published medical literature and information from *Unique* members. The first-named author and publication date from articles in the medical literature are given to allow you to look for the abstracts or original articles on the internet in PubMed (<http://www.ncbi.nlm.nih.gov/pubmed>). If you wish, you can obtain most articles from *Unique*. Thirty-three *Unique* members completed a detailed survey in 2017/18. In addition to this, information has also been drawn from the database records of other members where possible.

rearrangements like inv dup del 8p.

Individuals with inv dup del 8p have one normal chromosome 8, but the other chromosome 8 has undergone one such complex rearrangement. In this rearrangement, a small bit of the tip of 8p is deleted, almost always from REPD to the end chromosome 8p (pter) (red section in the diagram below), and a relatively large bit is duplicated (blue section in the diagram below), usually extending from REPP towards the centromere to 8p11, although the size can vary (see [Can the size of the duplicated region vary?](#)).

The extra duplicated part runs in the opposite direction to normal and is therefore termed inverted (*inv* for short). See how the bands in the top blue section on the inv dup del(8) are the mirror image of those below the yellow band. The duplicated segments are separated by most of band 8p23.1 which remains neither duplicated nor deleted (in yellow).



## Can the size of the duplicated region vary?

Yes. The size of the duplicated (blue) section is not the same in all people with inv dup del 8p. In some it may be larger and in some smaller, depending on where the chromosome breaks to form the inv dup del 8 chromosome. Diagram A (above) illustrates a more common large form of the duplication with a breakpoint in band 8p11.2. In some people, however, the breakpoint is further down towards the centromere e.g. in band 8p11.21, and the

duplication is a bit larger. The breakpoint may also be further up e.g. in band p12 or p21 (Diagram B), and the duplication is correspondingly smaller, to a varying degree (in this diagram the breakpoint is in band 8p21.2).

Note: throughout the guide the breakpoint will be referred to in brackets e.g. inv dup del 8p (p11) refers to a duplication where the breakpoint is in 8p11.

In 2018, *Unique* had 58 members with a confirmed diagnosis of inv dup del 8p with a breakpoint in 8p11; 10 members with a breakpoint in 8p12; 12 members with a breakpoint in 8p21; and one member with a breakpoint in 8p22.

The deletion *typically* seen in inv dup del 8p leaves most of the 8p23 band as a single copy joining the duplicated regions, meaning that critical genes in this region are present in the normal copy number.

For some people with inv dup del 8p, only the extra duplicated material is reported and not the small deletion. This may be due to an incomplete diagnosis, perhaps by karyotyping alone, where the chromosomes are examined under a microscope. The duplication is large enough to be easily detected but the technique used was not sensitive enough to pick up the tiny deletion. However, it is believed that the great majority of people with inverted duplications of 8p have the small deletion as well (Guo 1995). The 2017/18 survey of *Unique* members included only those with a confirmed diagnosis of inv dup del 8p.

## Is the size and location of the duplication significant?

The precise effects of gaining material from a chromosome varies depending on a number of factors, which we are only just beginning to understand. These include: how large the duplication is, how many genes the duplication contains and what those genes do. The same principle applies to deletions.

The effects may not be limited to the genes within a duplicated or deleted piece of chromosome because these genes may interact with other genes on the same or other chromosomes. For instance, so-called “modifier genes” located across the genome can influence the expression of another gene(s) that may play a role in the development of a particular feature. The cumulative effects of the variation in the DNA sequence across a person’s whole genome and the influence of environmental factors (both internal and external) will also have an impact.

For these reasons, even individuals with the same or very similar duplications and deletions can show variation in the range and severity of features, including those with inv dup del 8p. Duplications and deletions that result in the gain or loss of a group of genes that are located adjacent to each other can lead to multiple unrelated features, contributing to the broad

range of features observed for a particular rare chromosome disorder. Equally, a particular duplication/deletion may disrupt a gene or genes in a way that a similar but slightly different duplication/deletion does not, leading to the development of a specific feature(s).

There is some evidence of a link between the size of the duplicated region in people with inv dup del 8p and the range and severity of certain features, with the suggestion that those with larger duplications are likely to be more severely affected, but the experiences of *Unique* families suggest there is considerable variability regardless of the size of the duplication (Hand 2010; García-Santiago 2015; Unique).

## Mosaicism

In a few people, the cells containing the inv dup del 8p chromosome material exist alongside cells with a normal chromosome number and arrangement or with a different variant of chromosome 8, for instance a terminal deletion of 8p alone. This situation, known as **mosaicism**, typically arises after fertilisation. In 2018, *Unique* had one member with confirmed inv dup del 8p mosaicism.

Mosaicism is rare but where it has been reported in the medical literature the outcome of the condition was in some cases a lot milder. The proportion of inv dup del 8p cells in the different tissue types that make up the body can vary, which will influence the outcome. The degree of mosaicism isn't easy to determine as tissues that may be particularly important to development, such as the brain, cannot be easily investigated, unlike blood cells or cells in the saliva that are usually used for testing (Vermeesch 2003; Hand 2010).

## Why did this happen? Can it happen again?

To answer this question, the parents' and affected child's chromosomes need to be tested. What is certain is that, as a father or mother, there is nothing you did to cause the inv dup del 8p and nothing you could have done which would have prevented it. Chromosome rearrangements affect children from all parts of the world and from all types of background. They also happen naturally in plants and animals. It is no one's fault.

Inv dup del 8p can occur when there are no rearrangements in the parents' chromosomes and tests have shown that the parents' chromosomes are normal. This is referred to as "*de novo*" (dn) by geneticists, meaning the duplication and deletion have occurred as a new event in the child. While the cause of the inv dup del 8p is not known, it will almost certainly have occurred as an accident while the sperm or egg cells were being made. In these cases, the chances of having another affected child are usually no higher than for anyone else in the population (Ergun 2010; Unique).

The presence of the repeated REPP and REPD sections of DNA on chromosome 8p that are believed to underlie the occurrence of rare inv dup del 8p is also thought to be responsible for an extremely common inversion of 8p in the general population, which is found in 39% of the typical Japanese population and 26% of Europeans, and involves the same 8p23.1 segment that remains neither duplicated nor deleted in people with inv dup del 8p. This does not affect their health or development and there is no reason why they should know about it unless they have a baby with a chromosome disorder.

This inversion has been found in many of the small number of mothers of inv dup del 8p children tested for it, including several *Unique* members (Giglio 2001; García-Santiago 2015; Unique; Dr Fe García Santiago, personal communication). The presence of this common inversion can be shown by chromosome tests on the parents and means that in theory if you have had a child with inv dup del 8p you could be at risk of having another. However, the sequence of events that leads to the rearranged chromosome is still extremely rare, even if the harmless inversion on chromosome 8 is common. Any concerns should be discussed with your Clinical Genetics Service and it is important to remember that no environmental, dietary or lifestyle factors are known to cause these chromosome changes and neither parent is responsible (Floridia 1996; Giglio 2001; Kostiner 2002; Shimokawa 2004; García-Santiago 2015).

## Diagnosis

While some cases of inv dup del 8p have been diagnosed prenatally due to signs picked up by ultrasound, including too much amniotic fluid (polyhydramnios), slow or abnormal development of the heart, structural brain abnormalities and club foot, the majority received a diagnosis at birth or during childhood, usually as the result of so-called “dysmorphic” (unusual) features or a delay in reaching developmental milestones (de Die-Smulders 1995; Macmillin 2000; Soler 2003, Pramparo 2004; Hand 2010; Sireteanu 2013; Chen 2016; Akkurt 2017; Unique).

“ Our daughter was nearly one when we eventually got the results. We were not offered one but as we already had a daughter I knew that she was not developing the same, for example she didn't reach her developmental milestones. The doctors agreed to carry out a blood test at 9 months when she had her operation to repair her cleft. ” - inv dup del 8p (p11)

“ We took her in for testing at aged four, several months after the onset of seizures, believing the seizures to be linked to a specific disorder. We had not sought out genetic testing prior to that time, but were aware that our daughter had significant developmental delays, both physically and cognitively. ” - inv dup del 8p (p12)

“ She was tested at 18 months due to global developmental delay. ” - inv dup del 8p (p21)

## Test results

Depending how long ago your child received a diagnosis, the test results are likely to look like one these examples:

[46,XY,ish del\(8\)\(p23.1p23.3\) inv dup\(8\)\(p12p23\)dn](#) This result shows that the expected number of chromosomes (46) were found, and there was an X and a Y chromosome, so this is a boy or man. The test used the FISH technique (.ish) and this showed that DNA was missing from chromosome 8 (del(8)) between p23.1 and p23.3, at the end of the p arm. dup(8) means there is a duplication of chromosome 8. (p12p23) shows the bands that are duplicated; in this case, there is a gain of a chromosome segment from band p12 to band p23 and the duplication is inverted (inv). dn means that the parents' chromosomes have been checked, and this chromosome change is a new occurrence (*de novo*) and has not been inherited from either the father or the mother.

[46,XX,del\(8\)\(p23.1p23.2\) inv dup\(8\)\(p21.3p23.1\)](#) This result shows that the expected number of chromosomes (46) were observed. It also shows that two X chromosomes were found, so this is a girl or a woman. Inv dup(8) (p21.3p23.1) means there is an inverted duplication of chromosome 8p from p21.3 to p23.1. There is also missing DNA from bands 8p23.1 to p23.2 (del(8)(p23.1p23.2)).

[arr\[GRCh37\] 8p23.1p11.22\(12580132\\_39258953\)x3, 8p23.3p23.1\(190822\\_6735381\)x1](#) This result shows that the analysis used microarray technology (arr). GRCh37 tells you which version of the human genome was used for comparison (see [Genome Assemblies](#) (blue box)). The analysis revealed two DNA anomalies. One involves bands 8p23.1 to p11.22. The DNA anomaly is identified by its base pair numbers (the points where the chromosomal change has occurred). In this example, the DNA anomaly lies between base pairs 12580132 and 39258953 (by taking the first number from the second, you can work out that this is 26,678,821 base pairs, or 26.7 Mb). There is an extra copy (x3; the normal copy number is two) so it is a duplication. The second anomaly involves bands 8p23.3 to p23.1 and the DNA that lies between base pairs 190822 and 6735381 (6,544,559 base pairs, or 6.5 Mb). There is one copy missing (x1) (the normal copy number is two) so it is a deletion.

[46,XX,del\(8\)\(p23.1pter\)dup\(8\)\(p23p21.1\)\[8\]/46,XX\[12\]](#) This is an example of mosaicism, meaning that different cells in this individual have different numbers or arrangements of chromosomes. This is a girl or woman (XX). Twenty cells have been tested. Eight ([8]) cells had material missing (del) from chromosome 8 (8) from band p23.1 to the end of the p arm (pter), and a duplication (dup) of material from chromosome 8 ([8]) involving material

from band p23 to p21.1. Twelve ([12]) cells showed a normal karyotype for a girl or woman (46,XX).

## Genome Assemblies

The human genome project, an international effort to sequence the entire human genome and map all of its genes, was announced complete in 2003.

However, there were many gaps in the sequence and mapping data, and scientists have since been working continuously to identify the missing information. When new sequence information is identified, the base pair numbers of each chromosome change slightly and hence the numbers for individual genes and duplications can shift.

Each new version of the genome is often referred to as an 'assembly'. Every few years a new assembly is released. The genetic information you are given will be based on the Genome Reference Consortium (GRC) human (h) genome assembly that was the most up-to-date at the time the test was carried out. Therefore, you may see the DNA sequence referred to as hg19 (human genome 19) (on your child's genetic report it may also be referred to as GRCh37), which was released in 2009, or hg 18, which was released in 2006. The lower the hg number, the earlier the release. The most recent assembly is named GRCh38/hg38 and was released in 2014.

## Most common features

Each person with inv dup del 8p is unique and will have different developmental and medical concerns, but the most likely features and/or those that are the most likely to make a difference to a child's health or development are:

- Some degree of developmental delay
- Some degree of learning disability
- Speech and language delay or absence of speech
- Low muscle tone (hypotonia)
- Structural anomalies of the brain
- A heart condition, which often resolves naturally
- Feeding difficulties
- A recognisable "look" to the head and face

Features that are not usually obvious at birth but may develop during childhood include:

- Spinal curvature
- Contracted joints, making movement difficult

## Other features

Many other features have been noted in the medical literature and among *Unique* members. Some are known to be generally more common in children with chromosome disorders; others may in fact be unconnected with the chromosome disorder. All the same, because they have occurred in other people with inv dup del 8p, you can expect your child's paediatric specialists to be especially alert to them. These include:

- A high/arched palate
- Unusual dental development
- Anomalies of the eyes
- Anomalies of the arms, legs, hands or feet, including club foot (talipes)
- Hernias in the groin or the umbilicus
- Unusually positioned intestines
- Anomalies of the kidneys, urinary system and bladder
- Dislocated hips or hips that dislocate easily
- Early fusion of the bone plates of the skull
- Precocious (early) puberty
- Eosinophilic oesophagitis
- Autistic and hyperactive behaviours
- Excessive drooling

(Feldman 1993; de Die-Smulders 1995; Guo 1995; Tonk 2001; Fisch 2011; García-Santiago 2015; Akkurt 2017; Unique)

## Pregnancy & Birth

While many pregnancies proceeded without complication, around half of *Unique* members reported having concerns during pregnancy (including 16/30 members who responded to this question in the 2017/18 survey).

Most common were reports of unusual findings during ultrasound scans and reduced growth in the womb (intrauterine growth restriction (IUGR)). Several mothers told us that they experienced bleeding during pregnancy; others reported that their babies didn't move as much as expected (reduced foetal movement). A few mothers carried an unusually large (polyhydramnios) or small (oligohydramnios) amount of amniotic fluid and several members reported an umbilical cord with only two blood vessels, instead of the usual three. There were a few cases of high blood pressure or preeclampsia. One *Unique* mother had a partial abruption (separation of the placenta from the wall of the womb).

“ Completely normal and healthy pregnancy. She was breach until 38 weeks, so thought we might run into problems there, but she turned at the end. ” - inv dup del 8p (p11)

“ [Scans throughout the pregnancy showed] fluid on the brain, Dandy Walker Syndrome (DWS), absent corpus callosum, an enlarged heart and hydrops fetalis. It felt like they were finding something new at every scan. We were prepared for our daughter to need a shunt fitted shortly after birth, but when she was born she had no fluid on the brain and no sign of DWS. ” - inv dup del 8p (p11)

“ Low movement, low amniotic fluid, reverse diastolic flow in the umbilical cord. She was no longer growing. ” - inv dup del 8p (p21)

“ Nothing unusual about the pregnancy. ” - inv dup del 8p (p21)

In the *Unique* series, 14/44 mothers who told us about the duration of their pregnancy went into premature labour between 32 and 36 weeks. Several mothers also said that their labour progressed extremely quickly - there is a case in the literature to support this (Chen 2016).

A caesarean section was needed to deliver a third of babies (2017/18 survey), often because of a previous history of c-section deliveries or due to positioning, but sometimes because of complications such as preeclampsia or concerns due to IUGR.

## New-born babies

Most babies showed some signs of difficulty at birth. Twelve *Unique* babies experienced breathing difficulties and many needed immediate, temporary ventilation; four experienced apnoea events (periods where breathing stops, often during sleep).



Other notable difficulties included fourteen babies who were jaundiced, which was often described as severe and required phototherapy. There is also a report of a baby boy with severe jaundice that did not resolve until four to six months of age (Santiago 2014; *Unique*).

Twelve *Unique* parents described their new-born babies as “unusually inactive and placid”, a feature that may alert doctors to an under-lying condition.

Feeding difficulties were also particularly common (see [Feeding](#)).

“ The jaundice was mild. The breathing difficulties rapidly developed and after an apnoea event he was intubated at three-days-old. ” - inv dup del 8p (p11)

“ Slight jaundice. Otherwise tiny but healthy. ” - inv dup del 8p (p11)

“ He had mild jaundice, which didn't require treatment. I had a natural delivery and his Apgar scores were 10 at 1 min and 5 min. He was put in special care baby unit (SCBU) to be kept warm, monitor his sugar levels and make sure he was digesting properly. He spent almost three days in SCBU then came home. ” - inv dup del 8p (p11)

“ Was not as active and seemed really laid back and calm. ” - inv dup del 8p (p11)

“ When he was born his cry was almost inaudible. Mum had to keep him in a bassinet right next to her bed in order to hear him. She often watched him breath and noticed he would stop breathing and then gasp for air. ” - inv dup del 8p (p12)

“ Jaundice was very bad. She was on the light machines at home for almost two weeks. ” - inv dup del 8p (p21)

## Growth

Most babies are of normal or slightly low birth weight.

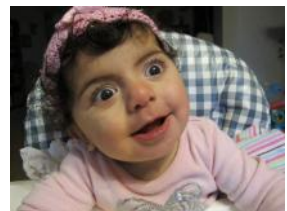The average birth weight of *Unique* babies with inv dup del 8p was 6lb 7oz (2.92kg), with a range of 3lb 2oz (1.42kg) to 9lb 4oz (4.2kg). The smallest babies were those born prematurely.

Feeding difficulties in the early months can lead to a slowing of weight gain relative to length. Roughly two thirds of *Unique* children (17/29 survey) were described by parents as having growth delay, which was usually mild to moderate. Children are often slightly short and underweight for their height; a few children are tall and above average weight for their age (Taylor 1977; Mitchell 1994; de Die-Smulders 1995; Masuda 2002; Vermeesch 2003; Hand 2010; Unique).

## Feeding

Early feeding difficulties were near-universal in the *Unique* series.

Often these difficulties were mild and temporary, but sometimes they were long-lasting, required treatment and could be severe. Concerns should be acted on early and skilled specialist feeding support sought.



Many mothers attempted breastfeeding but usually their baby could not latch on, was too sleepy, tired quickly, had no sucking reflex or was not yet able to co-ordinate sucking, swallowing and breathing. Some mothers were able to breastfeed, but weight gain tended to be disappointing. At least 15 *Unique* babies needed to be fed through a naso-gastric (NG) tube, which is passed through the nose into the stomach (in one case after initially being fed via an

orogastric (OG) tube, where the tube passes from the mouth to the stomach) and six children had a temporary period of being fed direct into the stomach through a gastrostomy tube. One baby was fed by a gastrojejunostomy (GJ) button (a tube is placed into the stomach as with a gastrostomy tube but food by-passes the stomach and passes via a small tube directly into the small intestine). Sometimes tube-feeding was required for a longer period of time, and for a few children remained in place as a more permanent measure.

Most babies fed from a bottle, although a few babies with tongue-tie (where the tongue is attached to the floor of the mouth by a bridge of tissue) or a cleft/arched palate needed an adapted feeder e.g. a Haberman feeder, and at least one baby found it is easier to breastfeed. Choking, coughing and spluttering can make even bottle-feeding a trying experience. Typically, children graduated late from a bottle to a cup with a soft spout or a spoon using thickened liquids, and many did not achieve this until mid-childhood.

Many babies suffered from reflux, where feeds frequently and forcefully return up the food pipe from the stomach, which was sometimes severe enough to warrant a diagnosis of gastro-oesophageal reflux disease (GERD/GORD). Babies may be at risk of inhaling fluid, food and saliva into their airway or lungs (aspiration). In some babies, reflux was severe enough to halt weight gain for many months. There are many simple measures to control reflux, including positioning semi-upright for feeds and using a cot with a raised head end; your doctor can prescribe feed thickeners and medication to help feeds stay down and counteract any effect of acidity on the food pipe. If this is not enough, a surgical operation called a fundoplication can improve the action of the valve, as was the case for three *Unique* babies. This procedure involves wrapping the top of the stomach around the bottom of the oesophagus and stitching it in place. At the same time the hole in the diaphragm through which the oesophagus passes is tightened.

Some *Unique* children received a diagnosis of eosinophilic oesophagitis, the symptoms of which resemble reflux but there is no response to reflux medication (*see Eosinophilic oesophagitis*).

“ He has had a NG tube since birth. He also had GERD and is still on small doses of the medication. They considered a PEG but decided it was too dangerous a surgery for him given his other issues. ” - inv dup del 8p (p11), 15 years

“ He struggled to latch on for breastfeeding but did so with nipple shields. He was initially fed via a NG tube for the first four days so that he didn't have to expend any energy to get the calories in, but once he was feeding well both from bottle and breast, the tube was removed. He had to be fed frequently as he was so small and weight gain in the first year was slow. ” - inv dup del 8p (p11), 2 years

“ She nursed like a champ - exclusively breastfed for six months. ” - inv dup del 8p (p11), 3 years

“ More successful with breastfeeding than a bottle. We were followed a few times by a lactation consultant who would weigh him during feedings, which had to last 45 minutes in order for him to get at least 2-3 oz because he was so easily fatigued. He was able to nurse successfully and did so until he was 20 months, at which point we were discouraged from continuing to breastfeed by a gastroenterology specialist whom we were seeing as he struggled with acid reflux and slow weight gain. It is my opinion that this was not the best decision for him, as he continues to have feeding difficulties with both liquids and solids. ” - inv dup del 8p (p11)



19 months

“ Had reflux in the early months as tried to increase the volume of feeds. At six months had half of feeds by pump overnight, which helped a lot, and started to put on weight. By five years one month she had a Nissen fundoplication, which worked very well. Mum wishes she had had it done a long time ago. At 10 years is still gastrostomy fed three bolus feeds per day. Can drink when she wants to but her coordination is very poor. ” - inv dup del 8p (p11)

“ As a baby, she had severe problems swallowing and sucking. She also had bad reflux and a stomach blockage (pyloric stenosis) that was preventing her stomach from emptying into the intestines quickly enough to keep up with her feeding rate. Three times she aspirated fluids badly (twice by mouth and once with the NG tube) and choked and stopped breathing. She required CPR and has minor brain damage (possibly from oxygen loss). At two months, she had surgery for G tube placement, Nissen fundoplication and pyloromyotomy. That fixed the reflux and choking issue. The G tube was removed when she was three-years-old. At five years, she doesn't chew food; eats purees only and drinks from a sippy cup. ” - inv dup del 8p (p11)

“ At first he appeared a very normal baby. After four days he was hospitalised because he couldn't eat and was very weak. During the first five weeks he was fed via a NG tube. One morning he surprised his parents by pulling the tube out and started drinking like a typical baby. He drinks special milk. At 16 months he is not yet eating solid foods but does like to put his fingers and thumbs into his mouth. Is to visit a feeding specialist. ” - inv dup del 8p (p12)

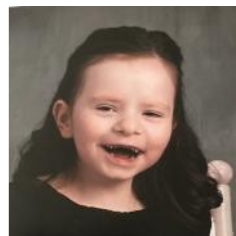“ She had colic and reflux and weaning was very difficult. She would choke on pureed food and vomit until over a year old. We didn't require any tubes. Treated with Gaviscon and cranial osteopathy. ” - inv dup del 8p (p21) - 4 years

Most children found chewing difficult and avoided hard and lumpy foods. Regardless of age, many needed to have food pureed or mashed. Families should be offered occupational or speech therapy to address these problems but it is likely that the diet will remain mostly soft. A few older children and adults preferred to finger-feed and use a spoon with support.

Feeding for babies without a chromosome disorder is usually a pleasurable experience. For babies with early feeding difficulties, it can become stressful and some children who have overcome their difficulties with swallowing, reflux or chewing nonetheless become food-averse. Ask your GP, health visitor, speech therapist or paediatrician about specialist feeding clinics to help with the 'can eat, won't eat' scenario that can then develop.

Constipation is a common problem in children with chromosome disorders, exacerbated by children's low muscle tone, relative inactivity and their small food and fluid intake. With a few exceptions, there was no evidence of underlying abnormalities of the bowel but most children in the *Unique* series regularly took medication to soften faeces, such as Movicol, and/or stimulate bowel action, such as Lactulose and Senna. Adapting your child's diet may also provide some relief and children may benefit from enemas if symptoms are particularly severe.

“ Seeing a nutritionist helped a lot. Constipation is managed through diet now. She eats only purees but we have added ground fibre-rich foods to help her maintain daily bowel movements and it has made an enormous difference to her overall health and sleeping habits. She eats homemade food that we puree. She also takes a laxative daily. Reflux was managed surgically. ” - inv dup del 8p (p11), 5 years



7 yrs

“ She can't chew so will choke on food if it is not chopped up, and also cannot really bite well. Now she is older, she will not eat certain foods and refuses them. No concerns as she is adapting to the situation herself, but still get stressed when she does choke. There are neurological issues between the brain and bowel: lacks the necessary nerve stimuli to evacuate her bowels, so has to have suppositories. ” - inv dup del 8p (p21), 16 years

## Appearance

Parents may notice similarities between their child and others with inv dup del 8p.

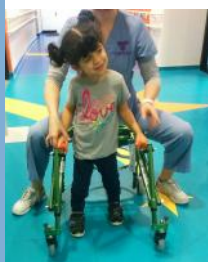All children are individuals and any dysmorphic (unusual) features may be subtle, but typical facial features include: a high, rounded, prominent forehead; a round or square face; an upturned nose; a thin upper lip and somewhat 'pouting' lower lip; a small lower jaw, which in a few children may

be unusually small (micrognathia) and/or receding (retrognathia); a pointed chin; and large ears with an unusual shape. Some children have widely-spaced eyes and may have skinfolds across the inner corner of the eye (epicanthic folds). Some of these typical facial features may not be obvious at birth but develop during the first year of life. Among adults they often become less pronounced.

Many children also have dry, curly hair that appears to recede from the temples. Some parents mention that their child has highly-sensitive skin and a few have excessive localised body hair.

Children typically also have a short neck; a long upper body; slender arms and legs; and small hands with long, tapering fingers. There is some evidence that these features may be less common in those with mosaic inv dup del 8p (Barber 1994; de Die-Smulders 1995; Vermeesch 2003; Hand 2010; Unique).

## Development: sitting, moving, walking (gross motor skills)



A delay in reaching developmental milestones, such as holding the head up and sitting, is to be expected, although there is a wide range of eventual ability (see testimonies below).

While all the children of *Unique* families who completed the survey (29/29) experienced some degree of delay, with support most children have walked short distances in early- to mid-childhood, although they often needed aids such as splints, support boots or a walker, and many relied on a wheelchair outdoors and later on as adults. A hand rail may help with tackling stairs and at least one girl wore a lycra compression suit to help with mobility.

Typically, *Unique* children had a poor sense of balance and co-ordination and their upper body control stopped them from crawling. Their muscle tone tended to fluctuate and many found it difficult to maintain either unsupported sitting or standing for a long time. A similar picture was recorded in *Unique's* database of families affected by inv dup del 8p and in the medical literature (Guo 1995; Vermeesch 2003; García-Santiago 2015; Unique).

The *Unique* series showed that children usually smiled between one and six months; rolled between two months and three years; sat between 9 months and three-and-a-half years; shuffled or crawled between 9 months and three years; often preferred to bum shuffle or roll and never



9 yrs

crawled; and walked, usually with support, between 18 months and five years. It should be noted that children may not reach some or all of these milestones or may achieve them much later.

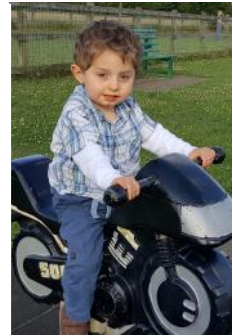Underlying this limited mobility is a mixed picture of weakness/floppiness (hypotonia) and excessive tautness of the skeletal muscles. Hypotonia seems to particularly affect the upper body from the waist in children with inv dup del 8p, causing difficulties with trunk and abdominal stability. Hypotonia generally improves by late childhood but does not usually disappear. Over time, children may also develop progressively increased muscle tone (hypertonia) in the legs and tightly contracted joints and many need regular physiotherapy, sometimes in water (aquatic physiotherapy), and passive stretching to keep as flexible as possible. Several parents also mentioned that the services of a chiropractor were beneficial.

Roughly one quarter of *Unique* parents told us that their child experienced involuntary muscle movements (spasms). Spasms are caused by increased muscle tone. In at least once case they had grown worse with age. Minor spasms affecting a 20-year-old woman were controlled with medication.

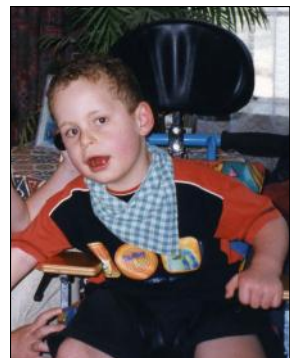Some children have tight heel cords and hamstrings and need a minor surgical operation to release them, although the experience of adults does suggest that the problem may persist despite surgery. Some older children experienced regression in their mobility (Gorinati 1991; Barber 1994; de Die-Smulders 1995; Masuda 2002; García-Santiago 2015, *Unique*).

“ She can sit for very short periods of time (one minute max) if placed into a sitting position but cannot get herself into a sitting position. She can roll onto her side but not right over. She has gone onto her front a few times but then gets stuck and is unable to get back without assistance. She has had PT from a few weeks old and OT from six months. She still receives both of these now in school. ” - inv dup del 8p (p11), 8 years

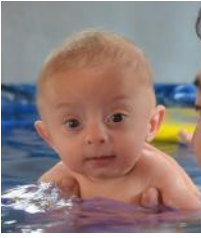“ She could roll and sit by herself at 9 months, and took her first steps at 21 months. She never liked to crawl. After a lot of professional training she could get up from the floor by herself when she was four-years-old. Now she can go hiking, including in mountain terrain. She can also run, but her running style is not perfect. She is very strong. ” - inv dup del 8p (p11), 9 years



2 yrs 5 mths



Age 6



“ She started to sit at about four years, but only for a short time due to poor muscle control, and will only roll from side to side. ” - inv dup del 8p (p11), 8 years

“ He rarely moved his legs from birth to three months and never kicked or raised them. He went from his tummy to sitting at 15 months, crawling at 18 months and walking at 30 months and preferred to crawl when his legs hurt. Although he can walk he tires quickly and

easily and has a poor sense of balance. He often walks on his toes, especially when over-stimulated. His right side is much weaker than his left and so his right side sags and drags. There has been a weakening with age (similar to MS) or fatigue and he struggles with his gait. He has hypotonia in the upper body (his shoulders, arms and trunk seem really loose) and he is hypertonic in his feet, ankles and knees. He receives PT privately once a week, as well as at school twice a week, and did hypnotherapy from 9 months to 10 years, which had the most positive impact on his walking, speech, and sensory needs. ” - inv dup del 8p (p12), 13 years

“ She was 15-months-old when she first walked, but at six years she runs, jumps on her trampoline, ascends and descends stairs without a problem and is very active, although progress is slow. ” - inv dup del 8p (p12), 6 years

“ Our daughter has had plenty of setbacks, from her heart condition to a seizure that left her with moderate brain damage. She has had to start over so many times. She never stops fighting and can now sit up unassisted. She has OT and PT daily. ” - inv dup del 8p (p21), 8 years

“ Independent walking is delayed but she can walk holding one finger and is crawling. ” - inv dup del 8p (p21), 2 years

“ At 11 years he loved swimming and dancing but couldn't cycle or play ball games and had poor balance. ” - inv dup del 8p (p21)

“ Her mobility has always been an issue. She rolled a six months, was able to sit at 10 months, crawled at 14 months and walked at 20 months. Seeing a chiropractor made a phenomenal difference - she went from a floppy baby to walking in 14 weeks. Stamina is a big issue. After a maximum of five to 10 minutes she is exhausted and falls over a lot. ” - inv dup del 8p (p21)

“ She has been able to ride a tricycle since three-and-a-half years. At 9 years she rode an adult-sized tricycle and, although her balance had improved, she still fell on a regular basis. ” - inv dup del 8p (mosaic)

## Development: hand use and coordination (fine motor skills)

A delay in the development of hand use and hand-eye coordination was

observed in most children.

These skills are essential for tasks such as holding a bottle, using cutlery, playing with toys and fastening clothes. A significant number of parents noted that their child had difficulties holding on to objects for an extended period of time and some children showed a reluctance to use their hands or a preference for a pincer grip. Parents suggest that hypermobile joints in the fingers and thumbs, hypotonia and anomalies of the hands often contributed to difficulties (see [Hands and Feet](#)). These factors can make holding a bottle and, later, cutlery difficult and contributed to babies and children needing help with feeding for extended periods of time.



Fine motor skills may improve with age, but children, teenagers and adults usually need help to carry out daily personal care tasks. Early intervention with occupational therapy to stimulate hand use may prove beneficial (Unique).

“ She can pick up large toys and move them from one hand to another. Her grasp is good but she struggles to release objects. Her co-ordination is very poor. ” - inv dup del 8p (p11), 8 years

“ Her fine motor skills are affected. Hypermobility means her hands are clenched and fingers curled. Her hands face down easily but not up. ” - inv dup del 8p (p11), 5 years

“ At kindergarten they taught her to eat with a fork/knife and spoon. She eats all by herself, but we always slice bread, meats and so on into smaller pieces [to prevent choking]. ” - inv dup del 8p (p11), 9 years

“ Fine motor skills are getting better but still unable to write letters. Can draw shapes and write some letters but the scale is large. Still working on using scissors. ” - inv dup del 8p (p11), 5 years

“ At 21 months can clap hands and reaches for toys. Uses both sides of body equally and simultaneously. ” - inv dup del 8p (p11)

“ At 18 months has very good hand control and uses the pincer grip very well. ” - inv dup del 8p (p11), 18 months

“ Struggles to hold pencils and cutlery. Some is due to spasticity; some is due to muscle weakness. ” - inv dup del 8p (p12), 13 years

“ Struggles with fine motor skills. She cannot write, do buttons or zips or play with fiddly objects. ” - inv dup del 8p (p21), 4 years



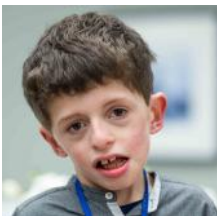“ She can hold and throw things but can’t do things like drawing. ” - inv dup del 8p (p21), 8 years

“ Claps hands, splashes in the bath, reaches for objects and transfers them from hand to hand. ” - inv dup del 8p (p21), 22 months

## Ability to learn

Children with inv dup del 8p will typically need support with their learning and in many cases this may be considerable.

While there are children who have only a mild learning disability, they seem to be the exception and many have a severe to profound disability. There is some evidence to suggest that those with a smaller duplication or mosaicism may be less severely affected than those with larger duplications (Fisch 2011; García-Santiago 2015; Unique).



A few *Unique* children learned to count, draw, read, use a switch or keyboard, or operate an iPad; one seven-year-old girl began to learn to write simple words using adaptive technology. For others, acquiring most or all of these skills has not proved possible or relevant. Almost universally parents also mentioned that their child is often reticent to acquire new skills. Many felt their child’s ability to learn had improved with age, although

others felt the ability to learn reached a certain level and then plateaued or, occasionally, regressed.

Some children attended a mainstream (regular) nursery/day care setting prior to starting school, sometimes with early intervention programmes. The information we have for *Unique* families suggests that once they started their formal education, most children did best with special education, either within a unit or with 1:1 support in a mainstream school or in a special school. A few children subsequently transferred back from a special school to a mainstream school. A few children were home-schooled.

Some parents particularly stressed that their child relished the social side of attending school. Interactions with their peers and teachers were deemed to be extremely beneficial. Some felt that their child benefitted significantly from interacting with their “typical” peers or siblings in a mainstream setting, at least for some of the timetable or during break times, although this won’t be possible for all.

Families reported similar strengths in their children: their sociability, ability to engage with other people, sense of humour, curiosity and



11 yrs

determination all helped them to learn. As a group they were more interested in interacting with people than with objects. Some children were musical and especially good at singing, so that music therapy was helpful. One severely affected child sang in a choir.

Early intervention was important to improve responsiveness and alertness, and consistency and regular daily or weekly practice was needed so that skills were retained. In the UK, a tailored education, health and care (EHC) plan can be issued after a child has undergone an EHC needs assessment. This legally-binding document ensures that the educational, health and social provisions deemed necessary to support a child's needs are delivered (previously, a statement of special educational needs was issued to children with learning difficulties). *Unique* has a dedicated guide to “[Education](#)” in the practical guides for families section of our website (Nevin 1990; Yenamendra 1999; Masuda 2002; Hand 2010; Vermeesch 2003; Fisch 2011; García-Santiago 2015; Unique).

“ Our daughter has severe learning difficulties. She attended a special nursery and primary school before going on to a mainstream secondary school, although it took a lot of negotiation. We found inclusion in mainstream school with support a very positive experience - it's certainly helped her mental health. She was also exposed to a much wider curriculum and it helped develop her vocabulary and musical ability. Post 16, we home educated with an individual budget and a person-centred curriculum. This has helped her transition into adult life. She has now finished her EHC plan and has transitioned to adult services. ” - inv dup del 8p (p11), 22 years, UK

“ Our son is 11-years-old with an approximate cognitive age of two years. He has always had a full time 1:1 support teacher. He went to a mainstream nursery and in Reception year he spent two days at our local mainstream school and three days at a special school focusing on physical disabilities, with the same 1:1 with him all week in both settings. In Year 2 he reduced his mainstream days down to one per week and by Year 6 he reduced his mainstream time to two hours per week (attending for assembly and PE). The mainstream school were very good at scheduling their timetable so the non-academic subjects were on the day that he attended. My advice would be to get the best EHC Plan you can get, be very specific, use legal help. Be open-minded about schools. A split placement has given our son local friends and our family some normality within a mainstream school, and he could go to school with his brothers. The special school has led on education and supported the mainstream school. Although he made good progress initially, this has plateaued since age five or so. There's been no significant progress since then, although I would say his personality has grown. Physiotherapy has been good but sensory integration occupational therapy has been the stand out therapy cognitively. ” - inv dup del 8p (p11), 11 years, UK

## One family's experience of the education system in the US.....

“ Our daughter “L” has been educated exclusively in special education classrooms, until this year when she began to go to the regular (mainstream) kindergarten class for part of the day for maths and literacy instruction. She is an auditory learner, so all testing and teaching needs to be presented auditorily. She does less well when she needs her vision to learn something new. She loves tasks that involve reading/writing/numbers/letters, but hates to work on fine motor skills and playing with toys. She is also very motivated when the task is going to help someone she cares about.

We live in the US and it was not difficult to get an IEP; however, it has been a challenge to make the IEP contain academic goals as well as functional goals, and to get L in a programme that would challenge her. She is cognitively more advanced than she is physically able. She does very well when accommodations are made for her disabilities (both sensory and motor impairments) and since she got a communication system, we have realized her cognition is much more advanced than we thought. Although L cannot use her hands to write/draw she has been using an alternative pencil to write (beginning a week after she turned seven). Her first time using it, she spelled her name. Now, she can spell her name, mom/dad and several sight words; she is also able to recognize days of the week, colour words, sight words and numbers/letters. She also requests songs she wants to listen to by choosing the first letter of that song.

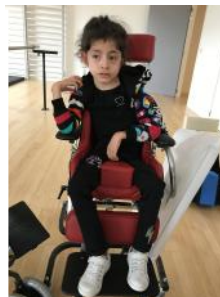We pushed really hard to get the teachers to use her communication system in the class. We also worked really hard with private therapists on finding assistive technology supports that would enable L to participate in regular educational activities. It has made a huge difference that she can communicate now. She needs a 1:1 support for school, to communicate and to keep her safe and help her with activities necessary for daily living.

L's ability to learn has improved with time. When she was a baby, she seemed to zone out. That doesn't happen anymore. We also had a lot of trouble being able to measure what she understood or was learning before she began communicating with her Pragmatic Organisation Dynamic Display (PODD). Also, until she got her G-tube she was underweight. We saw huge academic progress once she had over a year of good nutrition without any surgeries, learned to walk really well and began focusing on other things. Additionally, her teachers have been great. She is currently going through a learning growth spurt with huge progress in every area. I think it is a combination of us finally figuring out how she learns best, her being able to communicate with us and also being physically well.

She is very sociable and gets distracted by medical issues affecting others in her classroom. We are hoping that when she starts at her new school where the children are not as medically fragile, she will be able to focus better.

Physiotherapy (from four months to present) helped significantly with strengthening and teaching her how to use her body correctly. She was very motivated to keep up with her brothers and I believe her determination led to her being able to walk. Highly recommend working with a vision teacher to identify the right colour/contrast/size etc. for presenting educational material. These interventions since she was 11-months-old have improved her vision dramatically. She could not track objects or find things before; now she sees things she is interested in very well. Occupational therapy is L's most challenging area. It is just not of interest to her and she does not work as hard to get better. The OT has had to find unorthodox ways to get her to learn skills because she refuses to play with toys. Music has also been very helpful in aiding her academic learning and making connections between different skills. ” - inv dup del 8 [p11] - 7 yrs

“ The last year she has gone to a mainstream school together with her siblings. She learns a lot from being with other children. Slowly, step by step our daughter’s learning is improving in every aspect of her life. It was very important for her to go to a special kindergarten/school in the first years: they taught her skills such as language and the ability to eat and drink all by herself. The last year she has gone to a mainstream school.



10 yrs

Two teachers work with her and another boy with autism. She really enjoys going to the same school as her brother and sister - she runs up to them when she sees them in the school yard. Her siblings also enjoy being at the same school as her and she learnt a lot being with the other children. She is together with children her own age in sports, art and music. I think the combination has been very good. ” - inv dup del 8p (p11), 9 years, Europe

“ Our son has a cognitive age of about five years at 13 years. He can read simple sight words and seems to enjoy reading simple texts, but struggles tremendously with maths and has not achieved any of the other milestones. He has an individual education plan (IEP), which was very difficult to get initially. We also wanted a 1:1 aid for him, which we had to fight to get. He was in an early childhood program from ages three to five years and had early intervention at Kindergarten for two years. He has been in a Life Skills Programme from Grade one to present (Grade 7) and will continue in this programme through high school. He has had a 1:1 aid in each of these settings. These programmes are held in a self-contained classroom within the public (state) school setting. His learning abilities have stayed the same over time. He has had a range of therapies, including hypnotherapy, which was amazing and positively impacted his speech, walking and sensory needs. ” - inv dup del 8p (p12), 13 years, US

“ Her learning difficulty is severe: her cognitive age would be roughly that of a six-year-old, but she is still on P levels [a set of descriptions for recording the achievement of pupils with special educational needs (SEN)] so her abilities may be younger in places and she has an emotional age of approximately five years. She cannot draw, read or write, but she can follow straight lines with her pencil. She could touch switches when she was about five to turn on and off. Obtaining a Statement (then EHCP) went well but I understood the process so ensured all went as planned. I am also very clear and individualised in the assessments and not generic. Initially she attended a mainstream nursery but as her needs were beyond their understanding, she went to a specialist nursery and through the ranks in specialist provision. She is just about to embark on post-16 education in a specialist setting. She can learn everything but at a slower pace; as long as the environment is right, and she is in a "good place" internally she can move

forward in her learning. Now that her needs are recognised, and she is comfortable in herself, she remembers much more. She is quite sharp and has good long-term memory. It is more a communication difficulty that slows her learning progress at times.” - inv dup del 8p (p21), 16 years, UK

## Speech and Communication

Speech and language are specifically delayed or absent in children with inv dup del 8p, but communication is typically good.

For some children first words appeared between the ages of two and three years, while for others a more significant delay was observed, and many remain non-verbal. This pattern is reflected in both the medical literature and *Unique* children (Guo 1995; Hand 2010; Fisch 2011; García-Santiago 2015; Akkurt 2017; Unique).

Where speech does develop, children typically use individual words, two- or three-word phrases and occasionally longer sentences, or a combination depending on circumstance. Parents told us that their child’s speech was affected by a number of factors, including their emotional state and difficulties with processing information and composing a response. Children often find it difficult to make clearly intelligible speech sounds, which can make communication with strangers particularly challenging. One *Unique* family told us that their child had severe speech apraxia (also referred to as developmental verbal dyspraxia (DVD)), where an individual has trouble saying what s/he wants to say correctly and consistently.

Almost universally, parents believed that their child could understand a lot more than they could express. Even those children who developed more sophisticated speech still experienced difficulties expressing themselves on occasion, which could result in frustration and temper tantrums. Where individuals have no speech or very few words, communication may be enhanced through augmentative/alternative communication (AAC) e.g. Makaton, signing, gesture, facial expression, Picture Exchange Communication System (PECS) and iPad communication, which can reduce frustrations. Many *Unique* children favoured pushing/pulling gestures but a few used Makaton, sign language, PECs or an iPad, with varying degrees of success.

Children with inv dup del 8p therefore present a paradox of being typically highly communicative but non-verbal. Many families commented that their child learned through nursery rhymes and singing and, at the age of 11, one child in the *Unique* series could hum more than 50 tunes, but had almost no words.

An assessment by a speech and language therapist can identify your child’s specific difficulties. This will allow the therapist to identify the best ways to support speech and language development, through regular therapy sessions with your family, which have proved beneficial to many families.

“ She can say a few words but not always in the right context. ” - inv dup del 8p (p11), 5 years

“ She is non-verbal; however, she is very good at making sounds and changing her tone when excited or sad. She has her own type of singing that’s getting louder as she gets older. She is starting to use her eye gaze for choice making and knows a few Canaan Barrie signs (on the body signing). She understands a lot more than I think people realise; you can tell by her facial expressions. ” - inv dup del 8p (p11), 8 years

“ At two years five months she babbled to anyone or just to herself. At two years 9 months, responded well to physical prompts alongside verbal cues. Eye contact was better and she vocalised pleasure or interest; stilled in response to her name; shouted or cried to gain attention, with different cries for different needs; mimicked tones; copied intonation pattern of hello and own name. At five years one month still loved music and could carry a tune beautifully, even though she had no language. At 10 years she uses three BSL signs properly but occasionally. ” - inv dup del 8p (p11)

“ She is non-verbal but we use symbols, objects of reference, pictures and switches. She’s currently trying out the eye gaze. ” - inv dup del 8p (p11), 8 years

“ She has had a speech delay that has led to some excessive shyness. She can make sentences but I think it’s difficult for anyone outside of the immediate family to understand what she is saying. We are trying to develop alternative ways of communication for her to help build up her confidence so that she can feel like she’s being heard. She started using single words maybe around two-and-a-half to three-years-old. Certain sounds that require the specific use of the tongue or the use of the muscles of the oropharynx can sometimes be difficult. The lips can sometimes be a hindrance because they don’t move as well. Uses a mixture of both single words and long complex sentences, but the complex sentences can be difficult to understand because they get mumbled. She appears to understand but sometimes there seems to be a delay in the understanding process. ” - inv dup del 8p (p11), 5 years

“ She definitely understands more than she can express. Her current communication book contains over 1600 words, but she understands far more than that. She has the whole thing memorised and can navigate complex communication pathways (accessed via partner-assisted scanning). She can communicate very complex thoughts (talk to me, not around me), emotions (love you, miss you, hurt feelings), wants, questions, something’s wrong etc. ” - inv dup del 8p (p11), 7 years

“ He started speaking single words around age four and spoke only two words at a time up until about age 10. He is now speaking two words phrases

mixed with some very nice sentences at times and is beginning to hold a conversation with another person rather than just giving information about himself. I feel that he takes in a lot of information and understands the world around him but has profound difficulty expressing what he knows.” - inv dup del 8p (p12), 13 years



2 yrs 8 mths

“ Significant speech delay at six years. She understands most of what is said to her and responds with words but not necessarily complete sentences. She can follow instructions. In her responses she tends to babble a little before saying the one word she is trying to get across, as if she is trying to form the complete sentence but she can't really structure it. She has trouble with certain sounds. Her word for Mom is still Baba.” - inv dup del 8p (p12)

“ Babbled from around 18 months. Single words at four-and-a-half years. Most words are word approximations; she struggles with pronunciation. Understanding is significantly better than ability to communicate.” - inv dup del 8p (p21), 4 years

“ We sang a great deal in the beginning as this was easier for her to do as it is a different part of the brain that controls this. It took until she was about four-years-old to form understandable words but we continued with techniques that helped her to articulate. At six years she has limited vocabulary and even now some of her words sound like babble because she is trying too hard to speak and has to slow down and relax; this is due to her brain not processing properly. When we articulate the words that she is trying to convey back to her, she practises and will endeavour to say them properly. This works well for her. At times she uses long sentences but at other times says only single words (again this is due to her brain processing difficulties and also her emotional response or her overall wellbeing). When good she can have a good conversation, for example: "Granddad, tomorrow can we go to the garden centre to see Father Christmas?", but no matter what the answer is she repeats the same question over and over. The more excited she gets the more confused the sentence becomes. She understands so much more than she can express and her memory of events is fantastic. I feel frustrated that although she is confused, deep down she is trying to say what she knows.” - inv dup del 8p (p21), 16 years

“ She laughs constantly but speech is trickier. She can say single words e.g. no, yes, done, Mom, Dad, bro bro, hi, what, but she only says them if she wants to and there is no persuading her otherwise. "My mom." is probably her longest sentence; she usually says it when I pick her up from school.” - inv dup del 8p (p21), 8 years

## Personality

The personality of children with inv dup del 8p is reported to be one of their areas of strength.

Families consistently described a child with a happy, loving, charming, contented and upbeat outlook. Parents told us about empathetic and tactile children who were extremely sociable, sometimes preferring the company of older children or adults. Children particularly enjoyed sensory activities involving music, dance, lights and noise. Many also enjoyed being pushed on a swing; a few loved to swim. A 20-year-old was able to ski using an adapted bi-ski and relished the feeling of going fast.



Against this usually sunny disposition, difficulties in communicating needs or completing tasks could lead to frustration, outbursts of temper and “challenging behaviours”. Families of some children have noticed a risk of over-stimulation, when their child can become hard to manage. In a social situation, children may sometimes grab unpredictably at people or objects within their reach. Tantrums were common in younger children, usually born of frustration, sensory issues or of having their wishes thwarted. Some families remarked on a strong oral tendency, with children sucking fingers or biting for much longer than other children. Some parents were concerned that their child could be overly-friendly with strangers. Very rarely, children could demonstrate aggressive or self-injurious behaviours, such as biting or hair-pulling (Unique).

“ She is a very happy, cheeky, lively little girl. Everyone who meets her falls in love with her and she knows it. She has a fantastic sense of humour and loves being around people. At times she can get very frustrated; however, it is easy to calm her down. ” - inv dup del 8p (p11), 8 years

“ She has a great personality, is very sociable and caring, and makes friends easily. She loves to be around other people and she is very sensitive to the needs of others: she can always tell when someone is unhappy or not feeling well and tries to cheer them up by giving hugs/pats, asking to have a dance party, or teasing them. She has a great sense of humour. She loves to tease us, both with gestures and with her communication book. She has also become a little sassy the past couple of months, crossing her arms and telling us no when she doesn't want to do something. She used to bite her hands and throw tantrums when we couldn't figure out what was wrong. This has improved significantly since she learned how to communicate. ” - inv dup del 8p (p11), 7 years

“ She is a very happy (unusually so) and sociable person who loves her younger sister and loves to “sing”. Never unhappy, even when in pain she tries to engage. She has had quite an oral fixation and loved to have her hands or a towel or toy in her mouth. She has no safety awareness e.g. overly

friendly with strangers and would touch anything hot or sharp.” - inv dup del 8p (p12), 20 years

“ He is extremely happy most of the time. He loves to touch, hug and kiss (and has been taught who and when, appropriately). Melt downs are intense and it can be hard to get him back on track. He loves to be active and also to watch sports. He is persistent and positive and teaches us that no matter what your ability, there is joy in life. He has a smile on his face every day. ” - inv dup del 8p (p12), 13 years

“ A wonderful, happy, interested and joyful girl. She has major anxiety issues, which leave her insular towards people, but when she is relaxed with them she is very friendly, warm and chatty. She finds it hard to play with people and much prefers adult company. She enjoys being involved in conversation about simple things, such as nails painting, as she recognises and understands what is being said. ” - inv dup del 8p (p21), 16 years

## Social, emotional & anxiety disorders

An association between inv dup del 8p and autism spectrum disorders (ASDs) and attention deficit hyperactivity disorder (ADHD) has been suggested in the medical literature, although only one child in the *Unique* survey had a diagnosis of autistic tendencies. ASDs include autism and Asperger’s disorder and are associated with impaired social skills; problems with communicating; and a need to carry out repetitive and restrictive behaviours, interests and activities, from which an individual derives comfort. Children with ADHD demonstrate a range of behaviours including hyperactivity, inattentiveness and impulsiveness, which make it difficult for children to concentrate and control their actions and speech. Children are often described as “restless”, are easily distracted and may talk or interrupt a lot. A number of genes in this region of chromosome 8p have been linked to social, emotional and anxiety disorders, including *MCPH1*, *DPYSL2* and *STMN4*, which are either deleted (*MCPH1*) or duplicated (*DPYSL2* and *STMN4*) in most cases of inv dup del 8p (Fisch 2011; Tabarés-Seisdedos 2009; García-Santiago 2015; Unique).

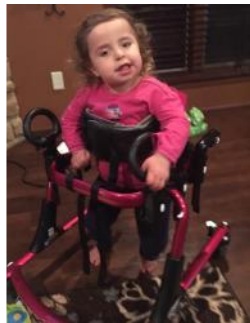## Sleep

Two thirds of *Unique* members remarked that at some point sleep has been a problem.

Some babies and children had problems getting to sleep or staying asleep; others tired easily and needed a lot of sleep compared to their peers. Health concerns, including the side-effects of epilepsy and epilepsy medications and gastrointestinal (GI) problems, sometimes contributed to sleeping difficulties. There is an indication in some cases that sleep problems improved with age.

Where sleep has been particularly challenging, some families have favoured the use of prescribed medicines, including the naturally-occurring hormone melatonin, with varying degrees of success. Such treatments should only be undertaken after consultation with a medical professional.

Five *Unique* members had experienced sleep apnoea, a sleep disorder that causes breathing to become shallow or stop completely during sleep. A CPAP (continuous positive airway pressure) machine may be recommended at night, usually just for a period of time. One teenager wasn't able to tolerate the CPAP mask and instead wore a pulse oximeter sensor around his toe at night, which was monitored by a nurse.



It can be challenging for all the family when a child does not settle well to sleep or is not getting enough good quality sleep. Our "[Sleep problems in children with chromosome disorders](#)" guide, in the practical guides for families section of our website, has further information.

## Toilet training

The evidence from *Unique* suggests that a significant delay in toilet training is to be expected, and may not be achieved by all. A few parents with children aged between five and 14 years felt that their child was close to being toilet trained, but for two adults in their twenties toilet training was not possible.

“ She is pretty much toilet trained, but we keep the pull ups on just in case. She still has occasional accidents because she is unable to use the toilet by herself and she isn't always able to get our attention in time to help her. ” - inv dup del 8p (p11), 7 years

“ He does prefer to go on the potty or toilet, but has no way to tell you. ” - inv dup del 8p (p11), 5 years

“ Until 13 and a half years old, she was in nappies day and night, but suddenly it just clicked and we got into a toileting routine during the day. It took over a year and then she was dry at night, as I stopped her drinking past a certain time and made sure she went to the loo before bed. Required constant repetition; very frustrating but well worth it. She still has accidents both day and night due to a neurological issue, but these are becoming less frequent. Routine and the consistency of all involved is key. ” - inv dup del 8p (p21), 16 years

## Medical concerns

### ■ General wellbeing

The picture in terms of general wellbeing is extremely mixed. On the one hand many parents described their child's general health as "good" or "very good", but a roughly equal number said their child was "fragile", prone to illness and took longer than expected to recover from colds and other childhood illnesses, although the situation often improved as childhood progressed (Unique).

Some children have on-going health conditions, including recurrent chest infections, seizures, spinal curvature and gastrointestinal problems (these will be covered in later sections) (Unique).

“ She used to be a very poorly baby, in and out of hospital every other week; however, she is now generally well. She does not suffer from many colds or sickness bugs. ” - inv dup del 8p (p11)

“ No known medical problems at six months, apart from congenital problems. Still in good health at five years. ” - inv dup del 8p (p11)

“ He gets sick frequently; his immune system is quite weak and he has numerous vitamin and iron deficiencies that we have to treat with supplements. ” - inv dup del 8p (p11)

“ As a baby she had a lot of health concerns due to aspiration and GI problems (gas pain and constipation), until we were able to manage these problems with a better diet. Real food instead of formula helped. She has some trouble recovering when she gets sick. Today, as a five-year-old, she is typically very healthy. ” - inv dup del 8p (p11)

“ The early teen years were a time where she was very medically fragile, but she is more stable now. Most of the surgeries are over, so that has helped. ” - inv dup del 8p (p12)

“ Other than epilepsy, she is in great health. She eats and sleeps well and is managing winters far better than previous years. The first three years of her life she was very poorly due to respiratory infections and seizures. ” - inv dup del 8p (p21)

### ■ Respiratory infections

Upper respiratory tract infections, chest infections and other respiratory difficulties, such as asthma and apnoea (stopping breathing), often affect babies and children with RCDs more than their "typical" siblings and peers. This is also the case for those with inv dup del 8p, although the incidence (10/29 in the *Unique* survey) was no higher than in other children with RCDs. Some children also experienced periods of apnoea, although this was often something they grew out of. A few children suffered from asthma.

A few *Unique* children have long-term respiratory conditions, including a 15-year-old boy with chronic lung disease and an 8-year-old girl who was on long-term antibiotics for recurrent respiratory infections. Otherwise, no other children seem to have experienced permanent lung damage or defects, and most conditions improved with age.

“ No asthma or respiratory infections, just obstructive and central sleep apnoea. ” - inv dup del 8p (p11), 14 years

“ When younger she had more frequent upper airway issues and sinus issues but have lessened with age. ” - inv dup del 8p (p11), 5 years

“ He suffers from sleep apnoea and breath-holding during the day. ” - inv dup del 8p (p11), 20 years

“ Aspiration pneumonias and swallowing issues led to her being nil by mouth. Apnoea only found in late 2016 but has been intermittent: went through 10 days of severe apnoea, 24 hours a day, then stopped. ” - inv dup del 8p (p12), 20 years

“ Recurrent chest infections and bronchiolitis. ” - inv dup del 8p (p21), 4 years

“ Partly formed lung, possibly due to pneumonia at 8 weeks, and was on oxygen from six to 9 months. Lung seems to be fine now. ” - inv dup del 8p (p21), 5 years

## ■ Seizures

Seizures are caused by a change in electrical activity in the brain. Depending on the part(s) of the brain affected symptoms vary, but include temporary confusion, uncontrollable jerking movements and loss of consciousness or awareness.

Seizure disorders, including epilepsy, were common among *Unique* members with inv dup del 8p, affecting 15/29 *Unique* members who completed the survey and a further 14 members in the *Unique* database.

Electroencephalograph (EEG) and video telemetry (video EEG) are medical tests that can be used to measure and record the electrical activity of the brain, and are tools that, when used alongside other tests, can help diagnose the type of seizure experienced, although many parents reported that the type of seizure(s) experienced remained undiagnosed. Seizures are often associated with a brain anomaly, including a missing corpus callosum (agenesis of corpus callosum (ACC)) (*see* [Head and Brain](#)), but can occur in children where a brain scan has found nothing unusual.

Seizures may be focal (partial) (limited to one part of the brain) or generalised (affecting both sides of the brain). The *Unique* series suggests no particular type of seizure is typical, and an individual may experience more

## Types of seizure

**Absence seizure:** A change in behaviour as if the child 'switches off', sometimes with staring, eyelid flickering or lip smacking. Absences are very brief, often lasting less than half a minute.

**Generalised tonic-clonic:** At the onset of a seizure, the abnormal electrical activity involves both sides of the brain. The seizure involves a phase of stiffening followed by jerking.

**Myoclonic:** Generalised seizure involving jerky or shock-like contraction of different muscles anywhere in the body but usually the arms or legs. Each myoclonic seizure lasts for a fraction of a second or a second at most.

**Myotonic:** Seizure involving stiffening of the muscles.

**Myoclonic-atonic:** Seizure involving jerky or shock-like contraction of muscles, followed by a loss of tone so someone standing up falls to the ground.

**Lennox-Gastaut syndrome:** An uncommon form of epilepsy that is particularly difficult to treat, with seizures usually starting between three and five years. The seizure-type experienced varies, but includes atonic ("drop attack"), absences, tonic-clonic and myoclonic seizures.

**Infantile spasm:** Type of seizure usually occurring in clusters in babies aged between three and 10 months. Seen most often when a baby wakes; may be obvious or subtle.

**Neonatal seizures:** Seizures (convulsions) that happen between birth and 28 days after the baby is born.

**Febrile seizure:** Episodes only occur when the child has a high temperature.

**Hypoglycaemic seizures:** Seizures resulting from severe low blood sugar

### One family's story.....

“ Until our daughter “F” was five-years-old, she had a lot of small seizures, from one to 11 a day and lasting 20-40 seconds, almost every week. There was no epileptic activity between the seizures. F had two very serious seizures before we knew that she had epilepsy, and the doctors were slow to see that she had epilepsy.

When she was two-years-old we went to the US to find out more about her syndrome. We met experts from the fields of Genetics and Epilepsy and we also spent several hours at the Developmental Department. The doctors concluded that F had epilepsy and started with medicines the next day.

We continued to have a lot of problems until she was five-years-old. After trying several medicines for three years we finally found a combination that worked very well! Trileptal (975 mg morning and evening) and Frisium (Clobazam 10 mg morning and evening). Her weight now is 36 kg, and she has just a few small seizures per year and has not needed Stesolid (Diastat) for the last four years. ” - inv dup del 8 (p11) - 9 years

than one type, with the first seizure occurring anywhere from the neonatal period to later in childhood (*see Types of seizure*).

Cases of tonic-clonic (grand mal) seizures (six cases); absence seizures (four cases); febrile convulsions (three cases); and individual cases of Lennox-Gastaut syndrome and hypoglycaemic seizures, were reported by families. In many other cases the type of seizure was unspecified.

Any evidence of seizures should be acted on promptly. Where necessary, treatment options, including the use of anti-convulsants such as valproate acid, sult(h)iamine and Keppra, have often been successfully used to help reduce the frequency and severity of seizures, although on a few occasions they have proved difficult to control (Unique).

“ She has had a few seizure incidents, the first of which was a grand mal seizure lasting 15 minutes that occurred without sickness or warning. She has since had complex febrile seizures. We carry Diastat for emergencies and give Klonopin (Clonazepam) during sickness to prevent seizures. She is followed by neurology. ” - inv dup del 8p (p11), 7 years

“ Only one two-minute seizure witnessed at two-weeks-old. ” - inv dup del 8p (p11), 14 years

“ Had a seizure in the first week in NICU. Neurologist ordered a host of tests. Treatment with Phenobarbital and Dilantin (Phenytoin) brought the seizures under control. ” - inv dup del 8p (p11)

“ She has Lennox-Gastaut epilepsy, and has been treated with a variety of different medications since the onset of seizures in 2012. She has been on the ketogenic diet since 2016, and has a VNS (vagus nerve stimulator) implant. In addition to the diet and implant, she is currently taking two medications: Lamotrigine and Onfi (Clobazam). The combination of diet, medication and VNS have helped decrease her seizures, but have not eliminated them entirely. She still has three-10 seizures weekly. ” - inv dup del 8p (p12), 9 years

“ She has tonic clonic seizures that go in to status seizures, drop seizures, absence seizures and myoclonic jerks. In the past she has also had febrile convulsions. She takes Keppra twice daily and has Epistatus, paraldehyde and Diazepam (a benzodiazepine) as rescue meds for status seizures. She requires oxygen with prolonged seizures, and needed ventilation and an induced coma for five days as a result of one febrile convulsion, due to aspiration of stomach contents. No extra, lasting damage due to prolonged seizures. Now carry Midazolam at all times to stop prolonged seizures. ” - inv dup del 8p (p21), 4 years

“ At two days, fitted constantly but no longer suffers from these at 19 months. EEG showed abnormal activity. ” - inv dup del 8p (p21)

“ By 21 months she has had two seizures; an EEG and MRI were normal. ” - inv dup del 8p (p21)

## ■ Head & Brain

A few babies were born with a very large soft spot (fontanelle) or wide spaces between the bony plates of the skull. While occasionally the front fontanelle was also slow to close, in a few babies the bony plates closed too soon (craniosynostosis) (Unique). Additionally, around half of babies had an unusual head shape or size. Most often baby's head was flat at the back (brachycephaly) or on one side (plagiocephaly); often corrected by helmet therapy to reshape the skull. Some babies also had an usually small (microcephaly) or large (macrocephaly) head.

“ He had plagiocephaly, at first with a 24mm deviation, but after wearing a prosthetic helmet this was reduced to ~7 mm. ” - inv dup del 8p (p12)

“ She had pronounced macrocephaly as an infant/toddler, but it has become less pronounced as she's grown. ” - inv dup del 8p (p12), 9 years

Magnetic resonance imaging (MRI) scans of the brain may be normal, but reports in the medical literature suggest that ~80% of babies with inv dup del 8p have a structural anomaly of the brain, a figure supported by the data provided by *Unique* members (24/28 babies and children in the *Unique* survey and a further 25 cases in the *Unique* database (DB)) (García-Santiago 2015; Unique). Your child's neurologist or paediatrician is best placed to explain to you the possible implications of any unusual findings and possible treatments that may be needed.

By far the most common anomaly recorded in both the medical literature and among *Unique* members was absence or underdevelopment of the corpus callosum (12/28 survey; 23 cases DB). The corpus callosum is a band of nerve fibres joining the left and right sides of the brain. It can be missing altogether (agenesis) (ACC), or it can be thin, short and underdeveloped (hypoplastic) (HCC). The effects vary, but both intellectual and physical development may be impaired, although the first indication of ACC is often the onset of seizures (*see Seizures*). There is no standard treatment for ACC but any symptoms that may develop will be treated.

Other reported structural anomalies included: larger than expected ventricles (fluid-filled spaces) (8/28 survey); underdevelopment of the cerebellum (the part of the brain that controls balance and movement) (2/28 survey; 1 case DB); colpocephaly (the occipital horns of the brain are larger than normal) (3/28 survey); periventricular leukomalacia (damage (softening) of the white matter (inner part of the brain) (1/28 survey; 1 case DB)); hydrocephalus (a build-up of cerebrospinal fluid in the brain that can lead to a build-up of pressure in the brain and may require surgery to introduce a shunt (a thin tube that is implanted in the brain and drains away excess

fluid)) (2/28 survey); the Dandy Walker anomaly (a cyst in the balance-control part of the brain (cerebellum)) (1/28 survey; 1 case DB); and cysts in the pineal region of her brain (2/28 survey; one case in DB).

A wide range of individual cases of further brain anomalies were reported by *Unique* families, including: an enlarged Cisterna Magna; polymicrogyria (where the 'hills' in the brain's surface are many and small); and an underdeveloped frontal lobe.

“ ACC was found when she was six-months-old; required no medication. ” - inv dup del 8p (p11), 10 years

“ ACC detected in first weeks after birth. ” - inv dup del 8p (p11)

“ The back, right of her head is flat and appears oval-shaped from above, as seen on CT. It was more noticeable when she was younger, and made wearing glasses hard as the distance from the side of the eye to the ear was different on the two sides. Hair helps cover it now. She also has colpocephaly and ACC. No treatment required. ” - inv dup del 8p (p12), 20 years

“ She has two cysts in the pineal region of her brain, which are asymptomatic and not a cause for concern. ” - inv dup del 8p (p21), 4 years

“ She had a CT scan that showed enlarged ventricles. She also has a little more fluid around the brain but no effects and no treatment needed. ” - inv dup del 8p (p21), 16 years

## ■ Heart conditions

A congenital heart defect was reported in about 25% of cases in the medical literature. The incidence of heart conditions appears to be higher among *Unique* members, with 14/29 (~50%) babies affected in the survey and a further 18 cases recorded in the *Unique* database. Some babies were affected by more than one condition (García-Santiago 2015; Unique).

One or more holes between the upper chambers (atrial septal defect (ASD)) or lower chambers (ventricular septal defect (VSD)) of the heart, were the most commonly reported conditions. In some babies there was a narrowing of the artery and valve that takes the blood to the lungs (pulmonary stenosis). ASD, VSD and pulmonary stenosis can form part of a more complex heart anomaly called Tetralogy of Fallot, which was discovered in a few inv dup del 8p babies.

A heart murmur was recorded for 9/29 babies in the *Unique* survey. Heart murmurs may be associated with an underlying heart problem, such as an ASD, but often there is no cause at all. Often a heart murmur is “innocent” and no treatment is required.

There are also a few reports of conditions associated with persisting features of foetal circulation after birth. These include patent ductus arteriosus (PDA), where a channel between the aorta and the pulmonary artery that takes

blood to the lungs, and which usually closes shortly after birth, stays open and the lungs receive more blood than they should. This means the heart has to work too hard and was seen in a few babies. A patent foramen ovale (PFO), where an opening between the two upper chambers of the heart does not close in the first year of life allowing extra blood to pass from the left to the right side of the heart, was reported by a few *Unique* parents.

A further heart anomaly that has been found in one or two children with inv dup del 8p is dextrocardia, where the heart is in a mirror image of its normal position. In itself, this usually poses no risk to health. It may occur in combination with situs inversus, where the appendix and liver lie to the left of the abdomen and the stomach lies to the right. Several babies were born with a bicuspid aortic valve.

Treatment of these heart conditions is decided on an individual basis but can include monitoring to see whether they resolve naturally, as was the case in the majority of cases. If need be, medication or surgical correction may be recommended (Guo 1995; de Die-Smulders 1995; Kostiner 2002; Masuda 2002; Sanitago 2014, García-Santiago 2015; Unique).

“ [Born with] ASD and PDA, which resolved within six weeks of birth. VSD remains but does not require surgical intervention at this time. ” - inv dup del 8p (p11), 5 years

“ She has a small PFO in her heart. Nothing that the cardiologist is concerned about - he thinks it'll close on its own by the time she's five years old. ” - inv dup del 8p (p11), 3 years

“ He was born with a bicuspid aortic valve and he had one small hole in the upper side of his heart, which resolved spontaneously. ” - inv dup del 8p (p12)

“ She had a small hole in the heart and consequently a murmur. It was checked but as it was small no treatment was given and were told it would close as she grew. Had her heart listened to recently and told no murmur. ” - inv dup del 8p (p21), 16 years

“ Atrioventricular septal defect (AVSD) and tetralogy of Fallot discovered at one-week-old and corrected surgically at seven months. Will require additional surgery to replace her pulmonary valve in the future. ” - inv dup del 8p (p21), 8 years

“ ASD repaired at 9 months and is fine at six-and-a-half years. ” - inv dup del 8p (mosaic)

## ■ Skeletal anomalies

Skeletal anomalies such as scoliosis (a sideways curve of the spine), kyphosis (an outward curve resulting in a hump) and kyphoscoliosis (a combination of kyphosis and scoliosis) have been reported in around six in

ten people in the medical literature (Feldman 1993; Guo 1995; de Die-Smulders 1995; Devriendt 1999; García-Santiago 2015). This closely matched *Unique's* experience: scoliosis was the most common condition reported (12 cases), but cases of kyphosis (one case); kyphoscoliosis (four cases); a tethered cord (the bottom of the spinal cord is usually free within the spinal column but occasionally it becomes attached (tethered) to one of the surrounding structures) (two cases); a sacral dimple (a dimple or hole in the skin just above the crease between the buttocks) (one case); and spina bifida (there is a gap in the spine as the baby's spine and spinal cord don't develop properly in the womb) (one case), which is a common cause of a tethered cord, were also seen.

Underlying the curvature of the spine may be abnormalities of muscle tone, and in some cases the bones of the spine (vertebrae) may be fused together or incorrectly formed. Curvatures of the spine often develop or worsen with age and should be monitored carefully.

The curvature can be treated with physiotherapy and exercises, or a support brace may be needed. If the curve becomes marked it may be necessary to undergo spinal fusion surgery and straighten the spine using rods, as was the experience of some *Unique* members.

A tethered cord can be treated with rest, physiotherapy and medications to help relieve symptoms, but untethering surgery may be the only permanent, successful treatment for more severe cases.

“ We have used a back brace, but our current orthopaedist believes that the curve is still too small to warrant it. Her curve is somewhat flexible and is related to low muscle tone (it can be straightened to 9 degrees, but if she is tired and standing it can be as big as 30 degrees). ” - inv dup del 8p (p11), 7 years

“ At six years her spine is being monitored for scoliosis - slight curve seen on X-ray that is not visible by eye. ” - inv dup del 8p (p11), 6 years

“ Our daughter has functional scoliosis and has a back brace/compression vest to help. We also do exercises/stretchers to help. ” - inv dup del 8p (p11), 3 years

“ Tethered spinal cord, which was repaired successfully at five months. ” - inv dup del 8p (p11)

“ Slight scoliosis at top and bottom of spine. No treatment as of yet. ” - inv dup del 8p (p12), 13 years

“ A spinal curvature is only now showing: she has a slight curve, which is worsening, and we are waiting for an appointment. ” - inv dup del 8p (p21), 16 years

## ■ Joint problems

Among *Unique* members, joint problems were common, including 20/28 children surveyed in 2017/18.

Problems with loose or unstable joints (also known as hypermobility) were particularly prevalent. While this condition may cause no problems, hypermobility is sometimes associated with pain and stiffness in the joints and muscles; injuries, including sprains; and joints that dislocate (come out of position) easily. Dislocation of the hip was experienced by many *Unique* children.

As children with inv dup del 8p get older, the medical literature and the experiences of *Unique* members suggests a marked tendency for them to develop progressive hypertonia (increased muscle tone) in the legs which, if untreated, can lead to contracted joints. This is an important reason for encouraging children to be as mobile as possible and for stimulating passive movement by stretching and physiotherapy. Among *Unique's* members, the contractions have been noted from babyhood. More than half the children over seven had developed joint contractures in the legs and hips, which limited normal activity and movement. The upper body appears to be unaffected by the increased tone, and arm and shoulder joints remained unusually flexible, although one *Unique* child had tightness of the right elbow.

Several children were described as having feet that were curved and angled inwards in a typical position for talipes equinovarus (club foot) (*see Hands & Feet*). A boy had a condition called patella alta, where unusual development of the knee cap means that it sits above its usual position and out of the joint, and required surgery.

Treatment options vary depending on the condition, but several children benefited from ankle-foot orthotics (AFOs) to aid ankle and foot positioning or to improve standing or walking. One boy had injections of Botox as a treatment for his tight calf muscles.

Seven *Unique* children had surgery for hamstring and adductor release, with varying *success* (see comments below) (Hongell 1978; Jensen 1982; Fryns 1985; Kleczkowska 1987; Barber 1994; de Die-Smulders 1995; *Unique*).

### Adductor release

The adductor muscles are responsible for bringing the legs together. They attach to the inside of the pelvis and the upper thigh bone. If they are too tight your child will scissor when (s)he stands so their legs cross over, or their hip may come partly out of joint (sublux) or completely dislocate. In adductor release surgery, the tendons that join the muscles to the pelvic bone are lengthened. After surgery children usually wear a cast for some weeks and a splint for some months.

## Hamstring release

The hamstring muscles connect the pelvis to the back of the knee. If these muscles become too tight a child will not be able to stand up straight. In surgery, the tendons between the pelvis and the back of the knee are lengthened or cut. After surgery, the child is usually in a cast for some weeks and after that splints at night and when resting for some months.

“ I do feel her hamstrings are getting tighter now and knee contraction has started. She can get very stiff at night and appears to 'lock' her legs at times, especially after standing in her standing frame. ” - inv dup del 8p (p11), 8 years

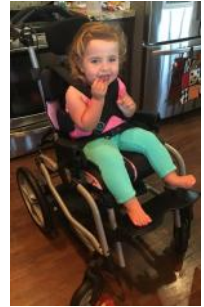“ Tight hamstrings, surgery for tendon release and tendon relocation on left foot and ankle. Legs are very weak and skinny. ” - inv dup del 8p (p11), 5 years

“ He has day and night splints to preserve the length of his calf muscles, whilst he continues to learn to walk. The day splints also help with stability. These are to prevent future issues and to address the slight stiffness found in his ankle joints. ” - inv dup del 8p (p11), 2 years

“ She has had Achilles' tendons release and right hip osteotomy and ostectomy three times as the hip was always out of joint. Would sit and pop her knees into and out of their joints when bored around ages three to four years. ” - inv dup del 8p (p12), 20 years

“ Her ankles are very stiff and don't bend up or down well. Quite often, her right leg turns outwards when walking. Hypermobility joints. ” - inv dup del 8p (p21), 16 years

“ Very tight behind the knees and around the ankles. ” - inv dup del 8p (p21)



2 yrs

## ■ Hands & Feet

Some parents notice unusual features of the hands and feet.

The hands may be unusually small with tapering fingers. Sometimes the fingers are curved (clinodactyly) and the fingernails may be underdeveloped (hypoplastic). Some babies and children have deep lines on the palms (and on the soles of the feet). Several *Unique* children and a child in the medical literature had anomalies of the thumb, including two children with an extra thumb (either whole or part). One child had the extra thumb removed in an outpatient hospital procedure.

Among *Unique* children, roughly half had flat feet (pes planus). A few were described as having feet that were curved and angled inwards in a typical position for club foot (talipes equinovarus). Sometimes the toes were

unusually short (brachydactyly), curved, over-lapping, webbed or had a wide gap between the big toe and second toe (sandal gap) and some had thinning or ridged nails (Vermeesch 2003; García-Santiago 2015; Unique).

Children are often only mildly affected, and any deformity may not require treatment, although children with flat feet may benefit from insoles to correct the foot position. Others, such as those with club foot, may also benefit from massage, physiotherapy and sometimes splinting to help correct incurved feet. This may reduce the need for corrective surgery and plaster casting. Treatment is tailored to the individual child and in some cases surgical correction will best enhance eventual mobility.

“ She has very small hands for her age and very small narrow feet that do not grow - they have been the same size for four years. Her feet are very pronated and the big toe of her right foot now curves to the right (we use a toe strap in AFOs to correct this). Her left foot had an amniotic band, removing part of the middle toes and part of the big toe. The big toenail is malformed as a result and the middle three toes have no nail. She also has webbed toes (all but the big toe) to the first joint, skin only. ” - inv dup del 8p (p11), 7 years

“ Long nail beds and very slim and long (pianist) fingers. Narrow palm width; the palm measured wrist to finger base is very short but fingers are very long, so the ratio is off. Very thick brittle nails. One foot is now very swollen permanently and, due to contractures, her toes curl down tightly on both feet. ” - inv dup del 8p (p12), 20 years

“ Her hands are extremely small and still have physical features of a baby. They do grow but extremely slowly. At 8-years-old she wears a size 8 in toddler shoes. ” - inv dup del 8p (p21), 8 years

“ She does have small hands and feet, but not to the point that she has any problems. She has been to hospital only once, as an outpatient, to remove her extra thumb. ” - inv dup del 8p (p21)

## ■ Kidneys & urinary tract infections

Minor anomalies of the kidneys, including several cases of an enlarged (dilated) kidney(s) (hydronephrosis) due to a build-up of urine inside, were reported. In a few cases the kidneys were smaller than is typical or were horseshoe-shaped (where the bottom points of the two usually separate kidneys are joined, creating a U (horseshoe) shape). Anomalies of the bladder are very occasionally noted, including an unusual Christmas tree-shaped bladder and a bladder that was three times the normal size. Usually these conditions were mild and required monitoring but no treatment.

Some babies and children experienced recurrent urinary tract infections (UTIs), even where no anomalies were picked up on an MRI. These may be treated with antibiotics or, very occasionally, a catheter may need to be

inserted to remove the build-up of urine and prevent damage to the kidneys (Unique).

## ■ Hearing

Although hearing problems are not a key feature of inv dup del 8p, some babies and children have a temporary hearing loss caused by glue ear; others, much less commonly, have a moderate to serious sensorineural hearing loss in one or both ears.

Some parents mentioned that their child had failed the new-born hearing test, but by the age of two-and-a-half years hearing was fine.

Temporary fluctuating hearing loss caused by glue ear can often be relieved by the insertion of tubes (grommets) to reduce pressure in the middle ear, although treatment is not always successful. Where the hearing loss is permanent, hearing aids may help as a temporary or longer-lasting measure, although this appears to be uncommon (Guo 1995; Unique).

Some children are also particularly prone to ear infections, which can be very painful and debilitating. Treatment with antibiotics and/or grommets may be necessary.

As children are at risk of speech delay, parental concerns regarding hearing should be acted on early and home- or school-based therapy provided.

“ Before three years, she had hearing problems due to fluid in the ears that required a tympanostomy tube (grommet) in both ears. Hearing normal after treatment. ” - inv dup del 8p (p11), 7 years

“ Had tubes placed at one year due to chronic ear infections. She has moderate-severe hearing loss in the left ear and wears a hearing aid in that ear, and mild-moderate hearing loss in the right ear. It is believed she is missing the hair cells in her cochlea and she will need amplification in both ears in the next few years. ” - inv dup del 8p (p11), 3 years

“ She had a severe ear infection at 12 months. At four years she didn't pass her hearing test at school so she will be seen by ENT to assess her hearing properly. At five years she still has problems with her ears, even with tubes in. ” - inv dup del 8p (p21)

“ He has some hearing impairment, some of which may be due to glue ear, and permanent hearing loss in his left ear. Grommets fitted in his right ear and he wears a hearing aid in his left ear. ” - inv dup del 8p (p21)



8 yrs

## ■ Eyes & eyesight

Vision problems and structural eye anomalies were reported by about half of *Unique* families.

Most often children were short-sighted (myopia) (7/29 survey; five cases in DB), but a few were long-sighted (hyperopia) (2/29 survey; one case in DB) and four children had a cortical visual impairment, where the visual impairment is due to a problem with the brain, rather than the eye. One child was registered as legally blind, although her parents felt she *could* see but didn't use her vision well. A few children had astigmatism, where the eyeball is rugby ball-shaped rather than round like a football, leading to blurred vision. Children often benefit from glasses, although some parents mention that their child was reluctant to wear them.

One third of children in the *Unique* survey had a squint (strabismus), where one eye or both turns inward, outward, up or down. Strabismus may be constant or it can occur intermittently, especially when tired. Among *Unique* members interventions like patching, exercises or glasses generally worked well to correct the squint, but for some strabismus was only corrected following a surgical operation. At least one child developed a "lazy eye" (amblyopia), which can be a consequence of a constant squint in one eye.

Other problems noted in the medical literature and by *Unique* families, included six *Unique* children with nystagmus (uncontrolled eye movements) and two children with Duane syndrome (a problem with turning the eye). Rare cases of iris coloboma, a developmental defect of the coloured part of the eye that gives it a 'keyhole' appearance; microphthalmia (the eye is abnormally small); damage to the optic nerve; developmental defects of the retina at the back of the eye; cataracts; ptosis (drooping of the upper eyelid so the eye is not fully open); and lagophthalmos (difficulty closing the eyelids completely), have also be reported (Guo 1995; García-Santiago 2015; Unique).

“ She has cortical visual impairment. She prefers looking at faces rather than objects, has a lot of trouble visually attending to tasks and uses peripheral vision to observe movement. Does best with multi-sensory approaches. We patched for many years, which helped significantly with exotropia (a type of strabismus). She also had eye muscle surgery at one year. She uses her eyes together now. Her vision was last measured at 20/260 [poor vision]. ” - inv dup del 8p (p11), 7 years

“ He wears glasses with a tint to help with sensory issues and had surgery on his right eye for amblyopia and strabismus. He is unable to track horizontally after a certain range and is unable to moves his eyes up past a certain degree. ” - inv dup del 8p (p12), 13 years

“ Cortical visual impairment. She has no depth perception and spatial

awareness difficulties. She has limited rapid eye movement and cannot follow objects without turning her head. Poor vision.” - inv dup del 8p (p21), 16 years

“ Poor vision in one eye, a slight squint and myopia in right eye and astigmatism in left eye. Wears glasses. The left eye was patched for one hour per day at almost four years. By five years is no longer patched.” - inv dup del 8p (p21)

## ■ Palate

A high/arched palate was common among individuals with inv dup del 8p; very rarely babies had a cleft lip or palate. Anomalies of the palate, particularly clefting, can cause difficulties in feeding, hearing, teething and speech production. As well as helping aesthetically, surgical repair eases these problems and may even eliminate them altogether (García-Santiago 2015; Unique).

“ She has a bisected uvula, which may indicate that she has a cleft palate that is covered by skin. She has consistent feeding problems and is nonverbal. No surgery.” - inv dup del 8p (p11), 5 years

“ Has a very high palate that impacts his eating. The orthodontist plans to improve the palate with an orthodontic device.” - inv dup del 8p (p12), 13 years

“ She has a very high palate and cannot chew food. She does not bite and swallows food whole. We had a lot of choking episodes before we fully understood the problem. Now, we give her softer food and chop it up. We peel apples and pears and chop them up as she does not enjoy biting and will give up quickly.” - inv dup del 8p (p21), 13 years

## ■ Minor anomalies of the genitals

Minor anomalies of the genitals are sometimes seen in boys with inv dup del 8p, but girls are much less likely to be affected. Within the *Unique* series, five boys were born with undescended testicles (cryptorchidism). The testicles begin their descent from the abdomen during foetal life and have usually arrived in the scrotum by birth. In a significant number of boys without any chromosome abnormality, that journey is not complete by birth but is completed within the next few months. When descent does not occur, the testicles can be brought down in a surgical operation (orchidopexy) and anchored in the scrotum. Two boys had a hydrocele (an accumulation of watery fluid in a sac around the testes), which may require draining. Small genitals have also been described in the medical literature and in one *Unique* boy. One girl was born with two uteri and two vaginas. Many of these minor anomalies can also be seen in children without an RCD and are not of major concern (Kleczkowska 1987; Unique).

## ■ Hypersalivation and drooling

A significant number of *Unique* parents (13/29) mentioned that their child had experienced excessive saliva production (hypersalivation) and/or drooling (sialorrhea) to a greater or lesser extent, which in one case occurred before the onset of a seizure. Drooling can happen without excessive saliva production if there is difficulty keeping the mouth closed or there is an inadequate mechanism or rate of swallowing, as is sometimes the case with neurological conditions such as cerebral palsy and intellectual disability. Various treatment options are available and medication may be prescribed if necessary, such as hyoscine patches, although there can be side effects. Some parents mentioned that the degree of drooling improved with time (Unique).

“She experienced excessive drooling until about 10-years-old, but this slowly stopped. She will sometimes drool at the sides of her mouth, but it is not as drastic as it was.” - inv dup del 8p (p21), 16 years

## ■ Hernias

Hernias were found in some children, affecting the groin (inguinal) and/or the belly button (umbilicus). They have also been noted in the medical literature. If necessary, hernias can be corrected with surgery (Kleczkowska 1987; Goa 1995; Unique).

## ■ Eosinophilic Oesophagitis

When asked, almost half of *Unique* parents (13/29 survey) said that their child had a diagnosis of eosinophilic oesophagitis (EO), although there is no mention of an association with inv dup del 8p in the medical literature. The oesophagus (food pipe) connects the mouth to the stomach. When it becomes inflamed this is known as oesophagitis. Sometimes inflammation of the oesophagus is caused by a particular type of white blood cell, called eosinophils, accumulating in large numbers in the lining of the oesophagus. Symptoms vary depending on age and there is overlap with those associated with acid reflux (GERD): children may refuse food, feel sick, vomit and fail to gain weight as expected; teenagers may complain of stomach or chest pain, accompanied by vomiting; and adults may find it difficult to swallow food and experience the feeling of food being stuck in their food pipe. Changes to diet and treatment with steroids can be used to control the condition, but may need to be long-term to prevent symptoms returning. In teenagers and adults, surgery to stretch the oesophagus may be recommended (Furuta 2015; Unique).

“At 9 years our son was diagnosed with EO. It started about two to three years before the diagnosis when he was vomiting in the night once every couple of weeks. His paediatrician said it wasn't frequent enough to be significant, but it then gradually happened more often until we were having

to take him into A&E regularly with recurrent vomiting that could only be controlled by Ondansetron medication, with limited success, or a drip. They diagnosed EO via an endoscope and biopsies, then prescribed Lansoprazole (used to treat GERD), but he had repeated episodes which led to him being admitted to hospital for five days. Since then he's been on a wheat-, dairy-, egg- and soya-free diet and hasn't been sick. His latest scope shows his oesophagus healing and the number of eosinophils is reducing. He's finally putting on weight and seems much happier. Over this time, his learning plateaued and I wonder whether there is a correlation. ” - inv dup del 8p (p11), 11 years

## ■ Teeth

Dental problems are very common in children with chromosome disorders, including among *Unique* members with inv dup del 8p (28/28 *Unique* survey).

The most common condition, affecting roughly two thirds of children, was tooth grinding (bruxism), which can lead to premature wearing down of the enamel. Two researchers noted missing or very small teeth in the upper jaw in children with inv dup del 8p. This was reflected in the *Unique* series where roughly one quarter of children had unusually small teeth. A similar number had milk teeth that emerged late, and were sometimes extremely late to fall out and be replaced by adult teeth. Occasionally the enamel was abnormally thin and weak (enamel hypoplasia), and some children were prone to dental decay (caries). Individually, some parents reported a fused tooth, extra teeth, large teeth, early teething, additional sets of adult teeth and thick gums.

A high standard of dental care is extremely important to minimise damage by decay and erosion. Children and adults may also benefit from specialist hospital dental services - dental work was one of the commonest reasons for hospital admission (Gorinati 1991; Mitchell 1994; García-Santiago 2015; *Unique*).

“ There are huge spaces between her teeth and severe grinding, especially when in pain. At 20-years-old she still has three baby teeth but has never had cavities (caries). ” - inv dup del 8p (p12), 20 years

“ Her teeth are stained from her medications and need professional cleaning regularly. ” - inv dup del 8p (p21), 8 years

## ■ Other medical concerns (*Unique* members)

Hypoglycaemia (low blood sugar): two cases (one linked to seizures)

Blocked tear ducts: four cases



14 yrs

Tracheomalacia and/or laryngomalacia: two cases

IgA blood deficiency: one case

Ulcerative Colitis: one case

Eczema: four cases

Highly-sensitive skin: three cases

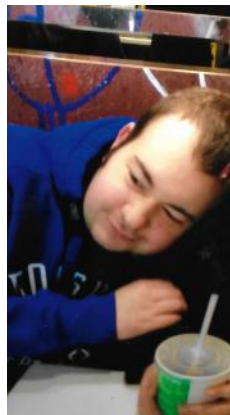Poor circulation: three cases (including one case of Raynaud's syndrome)

## Puberty

Puberty can be a challenging time for any family. The information we have relating to puberty and inv dup del 8p is limited, but among *Unique* families five members (including boys and girls) began puberty at the expected age, two girls were late to enter puberty and one girl is believed to have gone through puberty early (precocious puberty). One girl in the medical literature was also documented to have experienced precocious puberty. For most it seems that puberty proceeded as expected with no real cause for concern, although mood swings were common (Guo 1995; Unique).

“ We are in the midst of puberty now. Perhaps some of his behavioural outbursts have been related to hormone changes but we are not sure. Puberty has not seemed to be too difficult yet, but time will tell. ” - inv dup del 8p (p12), 13 years

“ Luckily puberty is taking a long time and is erratic, which has given us plenty of time for training. We (home and school) have worked together on this. She has weekly Well Woman sessions where her body's challenges are explained to her. We have set up specific routines, for example she has a specific toilet bag that is used during these times. This is a visual reminder for everyone concerned just in case communication fails. She copes well but her periods are heavy and painful when she gets them, so she is happy to take medication as a precaution on the first days. She is doing really well both emotionally and physically. ” - inv dup del 8p (p21), 16 years



## Adulthood & Independence

The evidence from *Unique* and the medical literature is limited but suggests that the great majority of people with inv dup del 8p will need considerable support throughout their lives, and only a limited measure of independence will be possible. Continence is the exception rather than the rule and feeding usually remains supervised even among the oldest children. Even the oldest people in our membership have needed full 1:1 support with daily living tasks

and finances.

Three adult *Unique* members lived at home, although one was in the process of moving into supported living. These members enjoyed a range of activities from singing and shopping to participating in sports. While work experience and vocational training were not possible for these members, at least one enjoyed attending a day centre.

There is limited evidence that one adult member may be experiencing some of the signs of premature ageing (Guo 1995; Unique).

“ Our daughter lives at home with our family. She has just finished her EHC plan and transitioned to adult services. She needs to be treated as an adult; an individual budget helps and we have found it helpful for her to get to know as many people in the community where she lives as possible - she’s much safer that way. Unless she is frightened or in pain, her behaviour is good. She enjoys singing, drama, swimming and cooking. ” - inv dup del 8p (p11), 22 years

“ Our daughter is 20-years-old and lives at home with us. She is happy to be with her family and around other people; she is very sociable, happy, engaging and fun. She enjoys skiing, camping and shopping and used to love to go out to eat and people-watch. Vocational training or work experience are not appropriate for her as she is more disabled than most. She shows the signs of premature ageing: she had her first grey hairs at 8-years-old and is very grey now, her skin is thinning and drying and there has been a definite regression in her physical abilities. She is never unhappy; even when in pain she tries to engage. She sleeps a lot: 12 hours a night most of her life! Life exhausts her. ” - inv dup del 8p (p12), 20 years

“ At 16 years she understands that she is growing up and wants to be “an independent woman”. She knows she is disabled and has carers. She is content with this and enjoys having a young carer who shows her about teenage things such as phones and apps. She has a beautician who does her make-up and nails and she loves these sessions. She loves anything girlie such as massages and tanning and is getting into the clothes concept. She loves swimming, and is very good, and also riding a bike; she cannot pedal so uses an adapted bike.

She does not want to be the same as other teenagers but enjoys having one-to-one girlie sessions instead. She is interested in boys and watches YouTube videos with young men in (supervised of course), but hey we all have hormones. She is having a good teenage experience and we try to ensure she does teenage things. She goes adapted cycling and swimming and loves them. She also goes shopping but only enjoys it if we are buying things for her as she loves the fuss of trying things on. It is hard work changing her in the changing room, so I send her carers with her to buy trendy clothes. ” - inv dup del 8p (p21), 16 years

“ Our son is 25-years old and we are just in the process of getting him into supported living: a bungalow with three other boys. I can't say I'm ready for the move, but we both need a life. For his 21st birthday we bought him an iPad, which was the best thing ever - he's great on it, very fast and is able to get hold of everything he wants to see. He still doesn't talk, get dressed or undressed, but he can feed himself. He doesn't sleep through; he is up early and is very demanding. He is usually a very happy young man, but his behaviour can be challenging. We are still smiling. ” - inv dup del 8p (p21), 25 years

## Genes

There are many genes located on chromosome 8p that may play a role in the features associated with inv dup del 8p. Some of these candidate genes are listed below. While identifying the gene(s) responsible for certain features associated with inv dup del 8p is valuable and may help guide future studies, it does not lead directly to immediate improved treatment. Also, even if the supposed responsible gene is duplicated or deleted, it does not always mean that the associated feature(s) will be present; other genetic and environmental factors play a role.

### ■ **STMN4**

The *STMN4* gene in band [8p21.2](#) is duplicated in most cases of inv dup del 8p and may be associated with behaviour and autistic spectrum disorders (Ozgen 2009).

### ■ **DPYSL2**

The *DPYSL2* gene in band [8p21.2](#) is also duplicated in most cases of inv dup del 8p and may be involved with self-harm as a related gene on the X chromosome is known to be associated with self-harm in children with Lesch-Nyhan syndrome (Ozgen 2009).

### ■ **NRG1**

Overexpression of the *NRG1* gene ([8p12](#)) has been suggested as a possible candidate gene for the severe hypotonia that is often associated with inv dup del 8p (García-Santiago 2015).

### ■ **FGF gene family**

Overexpression of genes in the FGF family e.g. *FGF17* ([8p21.3](#)), *FGF20* ([8p22](#)) and *FGFR1* ([8p11](#)), may play a role in limb malformations and dysmorphic facial features (García-Santiago 2015).

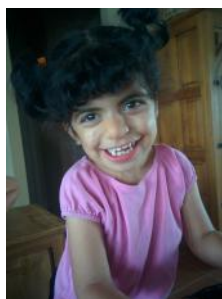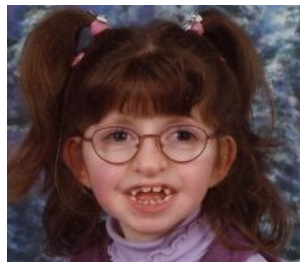### ■ **CDMD1**

The *CSMD1* gene in band [8p23.2](#) (deleted in inv dup del 8p) is associated with development of the central nervous system (García-Santiago 2015).

## What families say...

“ It was difficult at first getting used to a new routine, but over time it’s just become natural. Our daughter’s three older siblings love her to bits: they are always looking for her, wanting to play and are very protective of her. As her mum I have been inspired to train to become an occupational therapist after working with one! As a family we are very close, we go out regularly together and do what any other family would do.

Sometimes there are added challenges, but we find ways around these and our daughter is always fully included. She does have a PA we use to give her a break from us and us some time with her older siblings to spoil them a bit. We feel this is very important for them. Physically, things are getting harder and we have just had hoists fitted to help with this. Mum and dad do have sleepless nights but we share this task as much as possible to give us both a break. Being around other families is such a great resource for information and support. We have made some fantastic friends this way. Local parent carer groups are always worth joining, as well as national charities. ”



“ Take it one day at a time, take care of yourself too, talk openly with other children about how they feel and what they notice, expect the best of the child with the chromosome disorder because they will surprise you with all they will be able to do. Getting a communication system is critical. Live in the moment. Find other families to connect with (they don’t have to have the same diagnosis). Good therapists are really important. If you do not feel good about something, get a second opinion, or a third. You will not be able to do everything every one suggests. Do the best you can. Join online groups and ask questions. Learn about resources. The online support can be so informative. You will

never be like everyone else, but that doesn’t have to be a bad thing. I love our family just the way it is and our daughter has changed my husband and me for the better and taught me so much about love. We are better people, better parents. She has gifts that are hers alone. Look for your child’s gifts. ”

“ Your child will teach you so much and although the diagnosis will change your family, it can change you for the better. Try not to think any farther than six months in advance because beyond that it gets overwhelming. Your child can still have a wonderful life with a disability. Be gentle with yourself as you accept the diagnosis and take time for yourself when you can, too. ”

“ Our kids have their own timetable. They will do what they will do when it’s their time. There is no rushing it, no changing it. You just have to go with it. ”

“ My advice to other parents would be to accept that your child is unique, and in being so, do not compare their abilities, or lack thereof, to other children. Be as strong as you can for the sake of your child, but never hesitate to ask for and seek help. ”

“ While we see our son as a blessing, as he gets older, his





limitations have become very challenging for us as a family. At times, life is very lonely and feels very confining. It is essential to get support for yourself mentally and take care of your body physically. Build a good support system with friends and family if possible. Most of all, take breaks for yourself. ”

“ Kids with inv dup del 8p write their own rule book and defy everything ever written about them. They are sassy, smart, funny and utterly adorable. They always strive to be the best versions of themselves they can be. We were told

she would never walk or talk by her geneticist but she proved them wrong! ”

“ My advice is to join Facebook support groups to share milestones with people who understand how big those milestones are. ”

“ There is a huge spectrum with this diagnosis, particularly if your child has been diagnosed young. No one has a crystal ball to tell you what your child will be able to do in the future whether that is short-, medium- or long-term. Follow the advice that works for you e.g. putting your child in nursery to allow the chance to develop skills through copying, but also know that saying 'this doesn't work for us' is also OK. For us the important thing has been to make sure we don't limit our son's world by assuming that he can't or won't do things, but instead to give him all the opportunities for development we can and accept help with that too. It can be exhausting so allowing professionals and other agencies to help is really important. ”

“ Get a lot of help from family: we weren't good at asking for help for the first years and it led to us getting stressed at times. I also suggest getting into mindfulness. I recommend an app called 10% happier by Dan Harris. Lots of advice/wisdom from leading figures who have been doing mindfulness for many years. I have started to live more in the now, less in the past and future. Just like our daughter! We are very lucky to have a child like her and everything is possible! ”

“ It is a tough journey at times but never lose sight that they have the opportunity for a full and happy life, just at their level. The early years are the hardest as you are getting to understand them, but it does get easier and you will have so much fun. You will meet some wonderful people and learn so much about yourselves. There will be some very hard times and some tough decisions; you will be pushed to your limits at times but you will get through it and from that your coping abilities will grow. You are in for the long haul but the good times will be epic and the sheer joy you feel at them reaching milestones are unquantifiable. Work hard, keep trying, listen to advice and ignore some of it. They are yours and you are their champion and most importantly time will go very fast on this journey. Make sure you take the time to enjoy them because beneath all of this, when the door is shut at home they are your child and perfect. ”



## Facebook Groups

Chromosome 8p Disorder Parent Support Community (644) - <https://www.facebook.com/groups/8ptherapy/>

Chromosome 8 Disorders (402) - [https://www.facebook.com/groups/717458371707183/?ref=br\\_rs](https://www.facebook.com/groups/717458371707183/?ref=br_rs)

8p23.1 Deletion/Duplication Syndrome. Rare Chromosome Disorder (473) - <https://www.facebook.com/groups/939907672688019/>

8p deletion/duplication Research Group (283) - associated with 8p research project (Number of members as at August 2019 in brackets)

## YouTube videos

"Chromosome 8 disorders - What is a chromosomal abnormality"

<https://www.youtube.com/watch?v=nWhxzaiNqjE&t=1s>

"Inversion Deletion Duplication of Chromosome 8p" (a video by families for Rare Disease Day that explains the condition briefly and shows several children with the condition)

<https://www.youtube.com/watch?v=nzZEYlqYyA0>

"What are chromosome abnormalities? A simple to understand guide for families"

<https://www.youtube.com/watch?v=aeAnKkqcPIs&t=20s>

## Websites/blogs

<https://patient.info> - information on medical conditions and terms

<https://www.nhs.uk/conditions/> - easy to understand explanations of medical conditions and procedures

<https://hannahmeandinvdupdel8p.com/> - blog by 8p mum and public speaker

[chromosome8.org](http://chromosome8.org)

[specialbaby.org](http://specialbaby.org)

## Not-for-profit organisation

<https://www.project8p.org/> - Project 8p Foundation is a 501(c)(3) non-profit organisation that advocates for people with a chromosome 8p condition and everyone connected to someone with this condition.

## Books

"Chromosome Kids Like Me", by Annette Fournier (children's book by mother of inv dup del parent); "Redefine Special" by Melanie Gomez (spiritual devotional by mother of inv dup del 8p adult); "Playing in the Mud" by Annette Fournier (Humorous memoir about life with a special needs child, by mother of inv dup del 8p child)

# Inform Network Support



Understanding Chromosome & Gene Disorders

Rare Chromosome Disorder Support Group

The Stables, Station Road West, Oxted, Surrey RH8 9EE,  
United Kingdom

Tel: +44(0)1883 723356

[info@rarechromo.org](mailto:info@rarechromo.org) | [www.rarechromo.org](http://www.rarechromo.org)

Join Unique for family links, information and support.

Unique is a charity without government funding, existing entirely on donations and grants. If you can, please make a donation via our website at [www.rarechromo.org/donate](http://www.rarechromo.org/donate) Please help us to help you!

## Websites, Facebook groups and other links:

Project 8p: Join

Project 8p: Patient Navigator



This leaflet was made possible by a contribution from  
The Boshier-Hinton Foundation

Unique mentions other organisations' message boards and websites to help families looking for information. This does not imply that we endorse their content or have any responsibility for it.

This information guide is not a substitute for personal medical advice. Families should consult a medically qualified clinician in all matters relating to genetic diagnosis, management and health. Information on genetic changes is a very fast-moving field and while the information in this guide is believed to be the best available at the time of publication, some facts may later change. Unique does its best to keep abreast of changing information and to review its published guides as needed.

This booklet was first compiled by Unique (PM) in 2009 and reviewed by Dr John Barber, Wessex Clinical Genetics Service and by Professor Maj Hultén, BSc, PhD, MD, FRCPath, Professor of Medical Genetics, University of Warwick, 2009.

A major revision was made by Unique (CA) and reviewed by Dr Fe García Santiago, Institute of Medical and Molecular Genetics, Hospital Universitario La Paz, Madrid, Spain and by Dr Wendy Chung and Dr Haluk Kavus, Division of Molecular Genetics, Columbia University, New York, USA, 2019.

2019 Version 2.1 [CA]

2026 Version 2.2 [NM]

Copyright © Unique 2026

Rare Chromosome Disorder Support Group Charity Number 1110661

Registered in England and Wales Company Number 5460413