

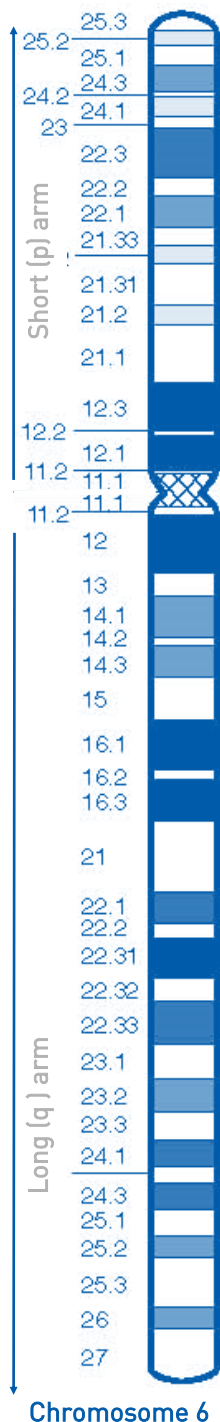


Understanding Chromosome & Gene Disorders

6p: Deletions from 6p25 and the end of the chromosome



rarechromo.org



Deletions from the end of the short arm of chromosome 6

A deletion from the end of the short arm of chromosome 6 is a genetic condition that occurs when there is a small piece of genetic material (DNA) missing from the end of one of the 46 chromosomes – chromosome 6. The genetic change usually affects development and sometimes health as well. But how much it affects individuals, and the ways in which it affects them, can vary a lot.

Genes and chromosomes

Our bodies are made up of trillions of cells. Most of the cells contain a set of around 20,000 different genes; this genetic information tells the body how to develop, grow and function. Genes are carried on structures called chromosomes.

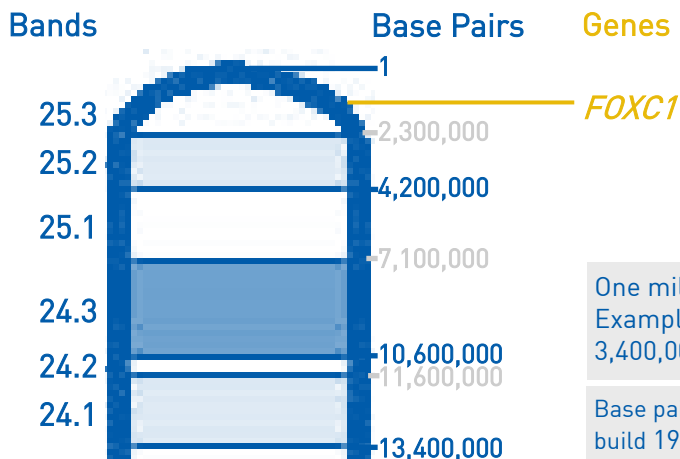
Chromosomes usually come in pairs, one chromosome from each parent. Of the 46 chromosomes, two are a pair of sex chromosomes: two Xs for a girl and an X and a Y for a boy. The remaining 44 chromosomes are grouped into 22 pairs and are numbered 1 to 22, approximately from largest to smallest. Each chromosome has a short (p) arm (from petit, the French for small) and a long (q) arm (see diagram left).

In general, the right amount of genetic material is needed for correct development – not too little and not too much. How an individual develops, his/her personality, needs and achievements are influenced both by the genetic material he or she has and the environment in which he or she lives.

Looking at the end of chromosome 6p

Chromosomes can't be seen with the naked eye, but if they are stained and magnified under a microscope, each one has a distinctive pattern of light and dark bands. In the diagrams on this page and on page 3, you can see the chromosome bands are numbered outwards from the point where the long arm meets the short arm. You will find bands 6p24 and 6p25 at the top, each divided into three further bands – light blue (24.1), white (24.2) and mid-blue (24.3); then white (25.1), blue (25.2) and white (25.3). Each band contains millions of base pairs of DNA. Base pairs are the chemicals in DNA that form the ends of the 'rungs' of its ladder-like structure. In all, bands 6p24 and 6p25 have about 13.4 million base pairs. This sounds a lot, but is actually quite small: the DNA in 6p25 on chromosome 6 is about 0.24 per cent of the total in each cell. On the right of the diagram at the top of page 3, you can see how the base pair numbers relate to the chromosome bands.

The top tip of the short arm of chromosome 6



One million base pairs = 1 Mb
Examples: 7,100,000 = 7.1 Mb
3,400,000 = 3.4 Mb

Base pair numbers follow hg19,
build 19 of the human genome.

6p subtelomere deletion syndrome

When a particular set of features occurs as a result of a single cause in a recognisable and consistent pattern in enough people, the condition is called a syndrome. The main features of a deletion from the end of 6p can occur in this way, and when they do, the condition is known as the **6p subtelomere deletion syndrome** or **6p25 deletion syndrome**. People with terminal deletions from 6p24 and even as far as 6p21 can have a similar pattern of features (Le Caignec 2005; Lin 2005; Maclean 2005; DeScipio 2007; Unique).

Has everyone with a deletion from the end of the short arm of chromosome 6 lost the same amount of DNA and the same genes?

No: everyone is different. So far as we know, there are no especially fragile places near the tip of the short arm of chromosome 6 where it is likely to break. Some people have lost a lot of DNA, others only a tiny amount. Some people have lost DNA from the end of chromosome 6 (a **terminal** deletion) with a break in the 6p25 band, others in 6p24, or even further along the short arm of chromosome 6. Other people have two breaks in the chromosome and have lost the DNA between them (an **interstitial** or **segmental** deletion). Typically, people with a deletion from the end of the chromosome have lost a gene known as *FOXCI* (see **Genes**, page 30), but they will usually have lost more DNA and other genes as well. A lot is known about the *FOXCI* gene, but the other genes near the tip of chromosome 6p have not yet been so thoroughly investigated.

I wish I had known ...

... how much different specialists can vary. Instead of having to wait to find out, I could have found my son a good one from the start.

The different missing DNA and genes explain many of the differences between people who all have a 6p deletion, but not all of them. Some people with very similar missing amounts of DNA and genes are affected much more mildly than others. Some of these differences can be explained by the DNA on the other, intact chromosome 6. Other differences are not yet fully understood. People with smaller and larger deletions often have a similar pattern of problems, suggesting that there is a 'critical region' of the short arm of chromosome 6 that must be lost for these features to appear. This has been narrowed down to the top 1.3 Mb stretch of the chromosome (DeScipio 2005; DeScipio 2007).

Sources

The information in this guide is drawn partly from key articles reporting 70 people with a 6p25 deletion in the medical literature (Jalal 1989; Zurcher 1990; Palmer 1991; Plaja 1994; Law 1998; Davies 1999; Topping 2002; Anderlid 2003; de Vries 2003; Chen 2004; Gould 2004; Mirza 2004; DeScipio 2005; Koolen 2005; Le Caignec 2005; Lin 2005; Maclean 2005; Caluseriu 2006; Kannu 2006; Suzuki 2006; van der Knaap 2006; DeScipio 2007; Martinez-Glez 2007; Martinet 2008; Aldinger 2009; Chen 2009; Bedoyan 2011; Piccione 2011; Tonoki 2011; Beby 2012; Cellini 2012; Delahaye 2012; Vernon 2013). The oldest patient reported is 41 years old. The first-named author and publication date are given to allow you to look for the abstracts or original articles on the internet in PubMed (www.ncbi.nlm.nih.gov/pubmed/). If you wish, you can obtain most articles from Unique. In addition, this guide draws on information from the Decipher database (<https://decipher.sanger.ac.uk>) and on a survey of members of Unique conducted in 2013, referenced Unique. When this guide was compiled, Unique had 24 members with a pure deletion from the end of 6p involving no other chromosome change. They ranged in age from 5-34 years.

Genetic testing

Looking at chromosomes under a microscope, it may be possible to see the missing genetic material, if the piece is large enough. If the missing piece is very small, the chromosomes may look normal under a microscope. Changes smaller than 5 Mb are very hard to identify, and sometimes larger changes as big as 10 Mb can be hard to see. A very small deletion is often called a [microdeletion](#). Molecular DNA technology gives a more precise understanding of the size and position of the deletion. This is important as scientists identify genes and pinpoint their location on chromosomes.

A person's chromosome make up is called his/ her karyotype. Someone with a deletion from near the end of 6p might have a karyotype that looks like one of these three examples:

[arr \[hg19\] 6p25.3 \[1366661-1861054\]x1dn](#) This result tells you that array comparative genomic hybridization ([arr](#)) showed that only one copy of part of the band known as [6p25.3](#) was found [[x1](#)]. The normal number of copies is two.

hg19 tells you which version of the human genome was used to make these measurements. At present, hg19 is the latest version. The first base pair missing is 1366661 and the last is 1861054. By taking the first number from the second, you can work out that there are 494,393 missing base pairs, or about 0.5 Mb of missing material. **dn** de novo (Latin for 'from the beginning') means that the chromosome change has not been inherited but has arisen 'anew'.

46,XX,del(6)(p23p25).ish 6pter(6pTEL48 x2) This result tells you that the expected number of chromosomes [46] were found. It shows that two **X** chromosomes were found, so this is a girl or woman. **del(6)** means there is a deletion from chromosome 6. **(p23p25)** shows the bands in the chromosome where breaks were found. This means that DNA between band 23 and 25 is missing. **.ish** shows that there was an analysis by FISH. **6pTEL48 x2** shows that the normal number of two copies of a marker for the tip of the chromosome were found. This means the deletion is segmental (interstitial) and not terminal.

46,XY,del(6)(p25) This result shows that the expected number of chromosomes [46] were found. It also shows that one **X** and one **Y** chromosome were found, so this is a boy or man. **del(6)** means there is a deletion from chromosome 6. **p25** shows the band in the chromosome where the break was found. Only one break is noted, so the DNA from the break to the end of the chromosome is missing.

Main features

- Developmental delay and/ or a need for learning support
- Speech delay or difficulty
- Hearing loss
- Eye problems
- Heart problems
- Brain anomalies
- Unusual facial features

Other features are described on pages 14-18.

[DeScipio 2007; Delahaye 2012].



Boy with 6p25
microdeletion,
5 years

First signs

First signs are usually picked up at birth, but can go undetected into adulthood

Among 45 babies, children and adults reported in the medical literature, concerns were most often raised when the baby was born. Nineteen babies were noted to have unusual facial features. In thirteen babies, an anomaly in the structure of the eyes was found at birth or as a young baby. Twelve

babies had an anomaly of the brain, most often enlarged fluid-filled spaces leading to hydrocephalus; in three babies the anomaly was first detected on an ultrasound scan, in one case as early as 17 weeks of pregnancy. Ten babies had a heart murmur or were diagnosed with a structural heart problem. Six babies were reported to have an obvious anomaly of one or both feet, including an unusual pattern of creases on the feet. Six babies had an unusual formation of the palate (roof of the mouth), ranging from a high palate to a split in both the upper lip and the palate. Four babies had a hearing loss, but this was not always noted at birth. Two babies had displaced hips. A range of other unusual findings have been noted, including a blockage of the windpipe (tracheal stenosis); a narrowing of the nasal passages; mild enlargement of the central part of the kidneys, and in one child, a single kidney; a blocked anus; a hollowed chest (pectus excavatum); eczema; and minor genital anomalies. Growth was affected in two children, with one baby of 32 weeks noted to be small for gestational age. Babies who were not identified at birth most often presented in their first year of life with concerns over their development and sometimes low muscle tone. In some cases, there were also concerns about hearing and sometimes vision. A small minority of children were not investigated until late childhood, or even adulthood. One child was first identified when she developed a limp at the age of 9. An adult was only identified at the age of 41 when her stubborn migraines and unusual brain MRI images were investigated (Palmer 1991; Plaja 1994; Law 1998; Davies 1999; Topping 2002; Anderlid 2003; Chen 2004; Mirza 2004; Koolen 2005; Le Caignec 2005; Lin 2005; Maclean 2005; Caluseriu 2006; Kannu 2006; Suzuki 2006; van der Knaap 2006; Martinez-Glez 2007; Martinet 2008; Bedoyan 2011; Tonoki 2011; Beby 2012; Delahaye 2012; Vernon 2013).

Among Unique members, first signs were quite diverse and were picked up at quite different ages. One baby had enlarged kidneys while still in the womb (see also [Pregnancy](#)), and another had increased nuchal translucency (thickness at the back of an unborn baby's neck) at 12 weeks of pregnancy. Three babies needed help with breathing at birth, and one of them was floppy, but with stiff limbs; while another had blue fingers and toes, a large head, couldn't feed, and was found to have heart problems, successfully corrected with surgery at 10 weeks. Another baby boy had a buried penis, but was only investigated when he

We wish we'd known ...

... that there is scope for normality. We didn't know that a parent and child with the same microdeletion might display different signs. The son is affected, but Dad is employed professionally. When we discovered this, it gave us hope and opened up our world.

did not crawl at 8 months. One five month old baby starting having a type of epileptic seizure known as infantile spasms, which generally come in clusters, often on waking. Another baby, being examined for a curved spine at 15 months, was noted to have unusually wide set eyes (Unique).

Pregnancy

Most pregnancies are trouble-free

In the great majority of cases reported in the medical literature, pregnancy was trouble-free and babies grew well. Vaginal bleeding, which is common in pregnancy, occurred in two pregnancies in the first and second trimesters and one mother experienced severe morning sickness with repeated bleeding. Premature delivery occurred in 5 out of 37 pregnancies (14 per cent), compared with a rate of 8 per cent for chromosomally unaffected pregnancies. One baby had slightly enlarged kidneys (hydronephrosis), but this concern resolved without any intervention; this was also seen in one Unique baby, and the mother had pre-eclampsia. One mother had too much amniotic fluid (polyhydramnios). Some babies with changes in the brain or heart problems were identified on a mid-pregnancy ultrasound scan (Zurcher 1990; Davies 1999; Topping 2002; DeScipio 2005; Le Caignec 2005; Lin 2005; Caluseriu 2006; Beby 2012; Delahaye 2012; Unique).

[“Tough, long pregnancy with severe sickness throughout, and a ‘clicking’ noise from mother’s abdomen heard regularly.” – 6p25 interstitial deletion](#)

New babies

Most babies reported in the medical literature were born a good weight and size. Babies are usually a good weight and size at birth. The range of weights around term among babies reported in the medical literature and at Unique is 2.2kg to 4.7kg [4lb 14oz to 10lb 6oz], with an average birth weight of 3.4kg [7lb 8oz], which compares well with birth weights for babies without a chromosomal disorder. One baby with an interstitial deletion between 6p23 and 6p25 was found to be small for gestational age at 32 weeks; one other baby was reported to have a low birth weight.

Many babies reported in the medical literature do have something unusual about them at birth. In around half, the head was an unusual shape or size, most often flat from front to back (brachycephalic) or noticeably flat at the back. Two Unique babies had a buried penis, needing corrective surgery. Most babies also have subtly unusual facial features, particularly the eyes, which are usually set further apart than in other babies and may slant downwards. There is usually no sign of any structural eye problem, but in a few babies there is something odd about the coloured part of the eye.

The feet and hands may also draw attention; in around 2/3 babies there is something unusual. This may be obvious, such as holding one or both feet in an odd position, or subtle, such as an unusual pattern of creases on the sole. A few babies have a more serious anomaly: around 1:10 babies is born with a cleft lip and/or palate (a split in the upper lip and/ or the roof of the mouth).

Although serious health problems are common in babies with a 6p25 deletion – more than half have a structural brain problem and around half have a heart problem – this may not always be obvious at birth or in the newborn period. A minority of these babies will be distinctly unwell, and a small number have marked respiratory distress at birth. Occasionally, babies with a 6p25 deletion are very seriously ill at birth and need early treatment and possibly surgery (Palmer 1991; Davies 1999; Lin 2005; DeScipio 2005; Beby 2012 ; Delahaye 2012; Unique).

“She was one of twins, born a good weight (2.66kg /5lb 14oz), but had some blue - purple discoloration around her mouth and spent a few days in the neonatal intensive care unit for oxygen and observation.” - 6p25 terminal deletion

“He had a large head, later diagnosed as hydrocephalus. He wasn’t feeding or waking, and had difficulty breathing, blue fingers and toes, and was very floppy. Nothing medical was done until he was 6 days old.” - 6p25 deletion

“He needed help to breathe at birth and had some difficulty feeding, but I managed to combine breast feeding as well as bottle. He had to be woken for feeds.” - 6p23p25 deletion

“He had initial difficulty breastfeeding, and gagged and choked, as he couldn’t seem to manage the milk flow. I pumped breast milk and fed it to him by bottle while continuing to try to breastfeed him for 3 months.” - 6p25.3 microdeletion

“She had a clicky hip which wasn’t treated, suspected positional talipes (never confirmed), a dislocated clavicle, and a severe skin rash on her upper body.” - 6p25 interstitial deletion

Growth

Growth is not usually affected

Among 26 children and adults whose growth has been followed up and reported in the medical literature, the great majority are neither unusually short nor unusually tall. Five individuals were unusually short when last measured, but in one case the growth failure was explained by a heart condition and resolved after an atrial septal defect (hole between heart chambers) was repaired, and another baby who failed to thrive, not putting on weight and growing as expected, but eventually grew into an adult of normal height. This evidence, generally supported at Unique, suggests that growth is not normally affected by the 6p25 deletion (Law 1998; Anderlid 2003).

Feeding

Young babies and children may have feeding difficulties

The evidence from Unique is that many babies will have persisting feeding problems and will need some long term support to feed and grow well. However, difficulties are not often severe, they do not affect all babies, and older children and adults are usually enjoying a varied diet of family foods.

Mixed breast and bottle feeding in the early months is common, as many babies find it hard to latch on, and to check the flow of milk from the breast and tend to

gag or choke. Most do meet their own nutritional needs, but a few babies and children are tube fed for some months or years until they can cope with eating. All babies known to Unique have made steady progress with feeding, eventually learning to drink through a teat or a spouted cup. Progress to solids can be delayed and children rely on liquidised, puréed or mashed foods or naturally smooth foods before learning to tolerate lumps. Children given lumps need frequent sips of drink to help food down. Problems noted by individual families include a high palate and lack of oral sensitivity leading to a tendency to overfill the mouth and swallowing difficulties; fussy eating; and poor weight gain.

He loves music, especially Scottish music with accordion and bagpipes, and loves his food. 34 years

Gastro oesophageal reflux (GORD, GERD), where the stomach contents return up the food pipe and may cause choking and vomiting, affected one or two babies. Reflux raises the risk of inhaling food contents and setting up an infection in the lungs known as aspiration pneumonia. Reflux can be eased by careful semi-upright positioning during and after feeds, sleeping in a prescribed sleep chair rather than a bed, raising the head end of the baby's cot and if necessary by prescribed medication that helps to keep the feed within the stomach and counteract any acidity.

Young children are often unable to feed themselves. Some need a specially adapted chair while feeding. Significant constipation can occur but medication is generally successful, and families find that constipation often eases once their child becomes more mobile (Unique).

"After the first three years, he became a very picky eater, and rejected fruit and veg once he was feeding himself. Today he will only eat bread, peanut butter, and vanilla yoghurt as well as some crackers, formula and iron supplements as per the paediatrician and dietician. He still refuses all fruit, vegetables, meat and fish." - 6p25.3 microdeletion, 5½ years

"As a baby she didn't always nurse well – she would nurse a little, then fall asleep. She had reflux with a severe milk/dairy protein allergy and remained at a very low percentile for growth and weight, so was given high-energy drinks several times a day to increase weight. At about 15 months of age, milk and dairy were introduced and she accepted it well. Today she eats everything and is actually a little overweight and likes a variety of foods. She loves to try new foods and eats well." - 6p25 terminal deletion, 6½ years

"He enjoys his food, and when tired or not concentrating can occasionally overfill his mouth. We avoid things like boiled sweets." - 6p23p25 deletion, 10 years

"Until she was about 3½ she would refuse to hold any food and had to be fed. Today she eats normal food in bite-sized chunks but prefers soft or wet foods." - 6p25 interstitial deletion, 10 years

"Tube fed for 2 years, now eats most foods." - 6p24 terminal deletion, 20 years

"He always has a good appetite and takes a small dose of omeprazole to deal with reflux." - 6p21 terminal deletion, 34 years

■ Hearing loss

Hearing loss is extremely common among people with a 6p25 or a 6p terminal deletion. Typically, it is a mixed type of impairment, combining conductive loss, where sounds cannot reach the nerves that communicate with the brain, and sensorineural loss, where there is a problem with the nerves taking sound impulses to the brain or with the brain interpreting the signals. Some babies do pass their newborn hearing test, but impairment can set in within weeks of birth; according to one estimate 94% of people are affected, although at Unique it is closer to 2/3. It is good practice for children to have six-monthly hearing tests, although not all children cooperate with testing. If a conductive hearing loss is identified, treatments include draining the middle ear and inserting tubes (grommets) to aerate the middle ear space. A Unique survey showed a high rate of tympanic (eardrum) perforation (3/5 children), in two children requiring patching of the eardrum. Probably all children will understand better if speech is slowed down and simplified to one or two word phrases spoken directly at them, reinforced by signing. In addition, some children will need hearing aids, if they will comply, and some will need special education for the hearing impaired. The few reports of adults with a 6p25 or 6p terminal deletion that exist show that hearing impairment can get worse with time. This underlines the need for regular hearing checks and early action. There is a report of an adult who is affected on one side only. There have been some reports suggesting a specific pattern of low frequency hearing loss. Scans of the temporal bones at the side of the head have revealed structural anomalies of the inner ear and the cochlea (the hearing part) in some people with hearing impairment (Zurcher 1990; Law 1998; Davies 1999; Anderlid 2003; Chen 2004; Gould 2004; Mirza 2004; DeScipio 2005; Le Caignec 2005; Lin 2005; Caluseriu 2006; Kannu 2006; van der Knaap 2006; DeScipio 2007; Martinez-Glez 2007; Martinet 2008; Bedoyan 2011; Piccione 2011; Tonoki 2011; Delahaye 2012; Vernon 2013; Unique).

“He failed his newborn hearing test, and didn’t respond to his name. Grommets were inserted at 4 years, but they didn’t work. His hearing is now a little better, he doesn’t need his aids so often. He finds it most difficult to hear speech when there is background noise. We do a lot of face to face, and practising phonics.” - 6p25 deletion, 8 years

“I had some mild hearing problems as a child, assumed at the time to be due to otitis media. Around age 20 I had some tinnitus, so went for a hearing test and learned that I had mixed sensory and conductive hearing loss, both low and high frequency, worse in one ear than the other. It was thought that I may have otosclerosis, but we now think that it is probably due to the *FOXC1* deletion. My hearing loss is not bad enough to need a hearing aid, and since then my hearing has been stable.” - adult with 6p25 microdeletion

■ Eye problems

Eye problems are a common feature. This is due to a gene in this region, called *FOXC1* (see [Genes](#), pages 30-31), which plays an important role in eye

development. Chromosome anomalies affecting 6p24-25 often result in abnormalities of the iris (the coloured part of the eye) which may include slightly oddly positioned pupils. Up to half of individuals with such eye changes develop glaucoma, a condition in which the pressure in the eye can become raised, in future years; the rest do not. Those who do develop glaucoma can be treated, usually with eye drops. Everyone with chromosome anomalies affecting 6p24-25 should be examined by an ophthalmologist, to ensure that if treatment is needed, it is started promptly. On request, Unique can put you in touch with an ophthalmologist with a particular interest in this area, who could facilitate local follow-up for you.



Glasses to correct long sight: boy with 6p25 microdeletion, 5 years

Other eye anomalies that are occasionally seen include: grey-blue colouring of eyeball (possibly associated with a loss of chromosome material at 6p24-p25); microphthalmia (smaller eyes); underdevelopment of the optic nerve that connects the eye with the brain; strabismus (squint, where the eyes are convergent or divergent) that may recur after surgery; prominent epicanthic folds (folds of skin across the inner corner of the eye); and refractive errors requiring correction (short or long sightedness, not always affecting both eyes in the same way) (Lehmann 2002; Mirza 2004; DeScipio 2007; Delahaye 2012; Vernon 2013; Unique).

“Glaucoma was first found at 2½ years, but later thought to be a falsely high result, as he was so hysterical during the test. His optic nerves appear healthy with no signs of glaucoma. Beyond this, he is far-sighted, wears glasses, and has a mild astigmatism.” - 6p25.3 microdeletion, 5½ years

“He has an alternating squint and one drooping eyelid. His sight seems normal but he has difficulties with depth perception, which affects his walking.” - 6p23p25 deletion, 10 years

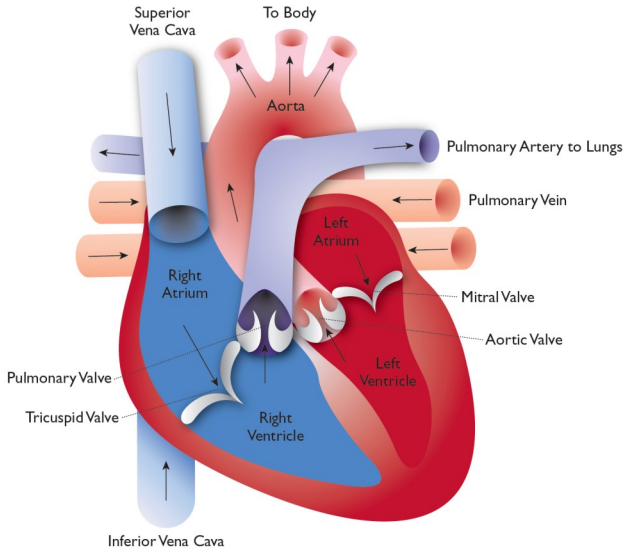
“She has eye checks every 4-6 months, but no glaucoma has been found. She wears glasses for strabismus, to correct her squint and for long-sightedness. She also has issues in particular with depth perception where there are sudden changes in the level, texture, or colour of the ground.” - 6p25 interstitial deletion, 10 years

“Vision good. Annual checks for glaucoma.” - 6p24 terminal deletion, 20 years

“Very short-sighted.” - 6p21 terminal deletion, 34 years

■ Heart problems

Both minor, self healing problems and complex anomalies are found



A normal heart

Some babies with a 6p25 deletion are born with strong, healthy hearts, but many babies, up to two-thirds, have congenital heart disease. Sometimes the problems are quite small and heal on their own in time; or they can be complex or serious problems that need surgical correction.

The most common heart problem is a hole or holes between the upper and lower chambers of the heart (atrial and ventricular septal defects), often in combination with persistent ductus

arteriosus (PDA), where a channel between the aorta and the pulmonary artery that takes blood to the lungs remains open instead of closing shortly after birth. A patent foramen ovale (PFO, an opening in the wall between the two upper heart chambers) which stays open instead of closing in a baby's first year is also common, sometimes in combination with a persistent ductus arteriosus. The heart valves which regulate blood flow in, through and out of the heart, can also be formed so that they do not work efficiently, causing the heart muscle to work harder to pump oxygenated blood around the body. Narrowing of the blood vessel that takes the blood from the heart to the rest of the body (coarctation of aorta) has also been seen. In an adult aged 41, there was no structural heart defect, but evidence of a conduction abnormality was found on an echocardiogram.

A few babies have complex heart conditions, including double outlet right ventricle (DORV), where the aorta and pulmonary artery both arise from the right side of the heart; and tetralogy of Fallot, where the pulmonary valve that regulates blood leaving the heart for the lungs is narrow (pulmonary stenosis) and there is a large hole between the right and left ventricles, the lower pumping chambers. This means that less blood flows through to the lungs and the level of oxygen in the blood is low. One baby had an underdeveloped left side of the heart, and one had an abnormality caused by the foramen ovale closing too early.

The approach to a child's heart problem depends on its severity and can include monitoring, medication and surgical correction. Among more than 20 babies reported in the medical literature, surgical repair was always successful. The only baby who died had a condition known as dilated cardiomyopathy, where the heart becomes weakened and enlarged and cannot pump blood efficiently around the body (Palmer 1991; Plaja 1994; Law 1998; Davies 1999; Topping 2002; Anderlid 2003; de Vries 2003; Gould 2004; Mirza 2004; DeScipio 2005; Lin 2005; Caluseriu 2006; DeScipio 2007; Martinet 2008; Tonoki 2011; Beby 2012; Delahaye 2012; Vernon 2013; Unique).

["He had open heart surgery at 10 weeks to correct his heart problems. Today they don't affect him, and he is generally fit and well."](#) - 6p25 deletion, 8 years

■ Brain anomalies

When the head of a baby or child with a 6p25 or terminal deletion including the *FOXC1* gene (see [Genes](#), page 30) is scanned, normally using magnetic resonance imaging (MRI), some typical changes have been found. These changes have been reported in as many as two-thirds to three-quarters of children reported in the medical literature, but are very much less frequent among Unique members. Most commonly a build-up of fluid within the brain (hydrocephalus) is found, sometimes in association with a type of brain abnormality known as Dandy-Walker malformation. These changes are sometimes detected before birth during the mid-pregnancy anomaly scan, but because they are known to be common, any baby or child who is found to have the 6p deletion will normally be offered an MRI scan.

The Dandy-Walker abnormality is the most common problem affecting the cerebellum, the part of the brain that coordinates movement, and the spaces around it. The central part (the vermis) is missing or very small. The cavity between the brainstem and the cerebellum that allows fluid to flow between the upper and lower parts of the brain and the spinal cord, known as the fourth ventricle enlarges. The part of the brain that contains the cerebellum and the brainstem (the posterior fossa) is abnormally large. These abnormalities can lead to problems with movement, coordination, cognition and other functions of the nervous system.

Hydrocephalus occurs in more than half of children with a Dandy-Walker abnormality. Although the Dandy-Walker abnormality cannot be treated, any build-up of fluid within the brain will be monitored and if it is compressing the brain tissue, excess fluid can be drained off through a shunt.

The corpus callosum that links the two sides of the brain is also sometimes affected, presenting as thin, short or underdeveloped. Other common findings are patchy abnormalities in the white matter that do not change over time; enlarged spaces within the brain; and shrinking of the brain tissue (Davies 1999; Chen 2004; Gould 2004; Caluseriu 2006; van der Knaap 2006; DeScipio 2007; Martinez-Glez 2007; Aldinger 2009; Chen 2009; Beby 2012; Cellini 2012; Delahaye 2012; Vernon 2013; Unique).

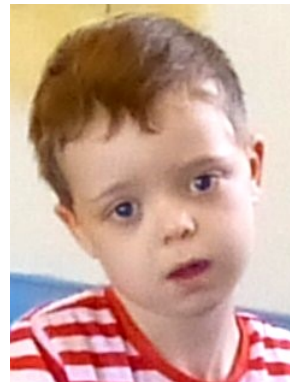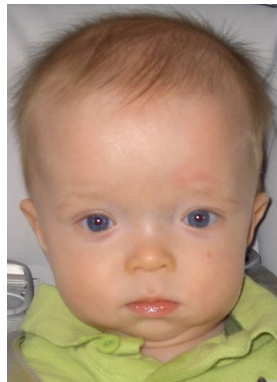
■ Unusual facial features

Babies and children are likely to have some facial features that are different from the rest of their family. Doctors may notice what are known as 'dysmorphic features' which may or may not be obvious to a parent.

Some of the most common features seen include a tall, prominent forehead; relatively underdeveloped cheekbones, upper jaw and eye sockets (midface hypoplasia), sometimes making the eyes appear slightly bulging; widely spaced eyes; small skin folds across the inner corners of the eyes; unusually formed, low set ears; a flat or broad bridge to the nose; a flat or short groove between the nose and upper lip (philtrum); a thin upper lip; and downturned corners, giving the mouth a 'tentled' look. A few children also have a protruding tongue; others have an unusually small lower jaw and chin (micrognathia).

Most of these features are of little or no importance to a baby or child, but a mismatch in jaw sizes can have a functional impact and one adult with a 6p25 deletion had her lower jaw surgically reduced to match the upper jaw better (Caluseriu 2006; DeScipio 2007).

Two boys with a
6p25 microdeletion
Left: 7 months
Right: 5 years



Other issues

■ Unusual features of hands and feet

Minor anomalies of the hands and feet are relatively common in children with chromosome disorders, and have been noticed in 86% of babies with a 6p25 or 6p terminal deletion. These may just be cosmetic or they may make it harder for the child to use their hands and feet normally, and physiotherapy and supports such as orthopaedic footwear may be needed. On both the hands and feet, unusual patterns of creases have been seen and the nails are sometimes underdeveloped, soft or unusually deeply curved.

Some children were born with club feet that needed correction by surgery, strapping, casting or physiotherapy. Others have a less obvious positional anomaly such as metatarsus adductus, an odd foot position in which the front half of the foot turns inwards. Other anomalies include unusually long, short or

broad big toes; one teenager had such long second toes that they were surgically shortened. Flat feet are also common; as is a wide 'sandal gap' between the big toe and the second toe. Two babies had 'rocker bottom' feet, where the sole of the foot curves outwards. Parts of the foot, such as the heel, may be twisted.

The most common features affecting the hands include fingers of an unusual length; incurving little fingers; and fingers that taper towards the tip or are fixed in a bent position. Thumbs may be placed lower down the wrist than normal; they may be unusually broad (Jalal 1989; Palmer 1991; Plaja 1994; Davies 1999; Anderlid 2003; de Vries 2003; Gould 2004; Mirza 2004; DeScipio 2005; Koolen 2005; Le Caignec 2005; Caluseriu 2006; Kannu 2006; DeScipio 2007; Martinez-Glez 2007; Bedoyan 2011; Delahaye 2012; Unique).

"Hyperextensible joints." - 6p25.3 microdeletion, 5½ years

"She has flat feet that roll in at the ankles, made worse by morphoea. This is also known as linear scleroderma and she had it on her right foot and chest. It caused pain in her right foot and ankle, often meaning she was unable to weight bear, but was treated successfully with methotrexate and steroid cream. Post-puberty she will need corrective surgery on her right ankle, when her growth has all but stopped. At present she wears AFOs (ankle foot orthoses, or supports) on both feet to manage this." - 6p25 interstitial deletion, 10 years

■ Epiphyseal dysplasia

In some children with a 6p25 or a 6p terminal deletion there is a defect in the growing ends of the long bones, especially the thigh bones. Normally long bones grow by depositing cartilage at the ends (the epiphyses) and this hardens to become bone. In affected children this process is delayed and the ends of the bones are unusually flattened. This can lead to hip dysplasia and later joint and mobility problems. To prevent this, suggested good practice is for any child found to have a delay in the process of laying down bone in early childhood to be regularly followed up by an orthopaedic surgeon. Physiotherapy can help to strengthen muscles; surgery and possibly joint replacement may be needed to treat a hip abnormality (Gould 2004; Mirza 2004; Maclean 2005; Kannu 2006; Suzuki 2006; Martinez-Glez 2007; Martinet 2008; Bedoyan 2011; Delahaye 2012).

"He doesn't have hip problems, but does have an unusual hip appearance on X-ray according to his orthopaedic surgeon." - 6p25.3 microdeletion, 5½ years

"She had Perthes disease in her hips, leaving the left leg slightly shorter than the right. She had surgery to remove bone from the pelvis to pack into the space at the top of the left leg to knit into the hip area." - 6p25 terminal deletion, 29 years

■ Cleft lip and palate

Five babies reported in the medical literature have been born with a split in the roof of the mouth (a cleft palate), a split in the upper lip (cleft lip) or both, and this has also been seen in two Unique babies. This is caused by an error in

fusion when the fetus is forming. The lip and palate fuse from pieces that start on opposite sides of the head. The lip fuses around weeks 6-7 and the palate at around 12 weeks. A cleft occurs when the pieces come round but do not join. A cleft palate causes difficulties in both feeding and speech production. Surgical repair of the palate eases these difficulties and may eliminate them altogether (Palmer 1991; Topping 2002; Mirza 2004; Lin 2005; Delahaye 2012; Unique).

■ Teeth

Dental disorders appear to be more common among children with a chromosome disorder than among typically developing children. Among children and adults with a 6p25 or 6p terminal deletion, at least 1:3 had a dental problem. Malocclusion (an irregular fit between the top and bottom teeth) is common, as are prominent teeth, abnormal positioning or overcrowded teeth. In some people, there are missing teeth, and others have poor enamel, with multiple caries and need for extensive treatment. Teeth may be unusually formed: two children had cone-shaped teeth; another had a mismatch in shape and size between the two front teeth. The extent and variety of dental problems means that children should have regular dental reviews and access to specialist dental treatment if needed (Jalal 1989; Law 1998; Anderlid 2003; Mirza 2004; DeScipio 2005; Le Caignec 2005; Lin 2005; Martinez-Glez 2007; Martinet 2008; Delahaye 2012; Unique).

“She has most of her adult teeth at 10 years old and some milk teeth remain.” - 6p25 interstitial deletion, 10 years

“He tends to lose and get teeth earlier than normal. Otherwise his teeth are fine.” - 6p23p25 deletion, 10 years

“His teeth eroded severely so he needed capping under a general anaesthetic at the dental hospital. Today he attends a dental clinic for people with special needs quarterly.” - 6p21 terminal deletion, 34 years

■ Kidneys

Kidney anomalies are not common but have been found in 6 babies reported in the medical literature and two at Unique, frequently at the mid-pregnancy ultrasound scan. In three babies, cysts were found on one or both kidneys; in six babies one or both kidneys were enlarged. Sometimes the whole kidney was swollen; in other cases just the part of the kidney in direct contact with the ureter leading to the bladder was swollen. Where information was given, the kidney problem resolved spontaneously (Palmer 1991; Topping 2002; Gould 2004; Mirza 2004; Lin 2005; Unique).

■ Spine

The great majority of babies reported in the medical literature are born with a straight spine. In a small number, there may be a sideways curve (scoliosis); in one child the curve got worse over time (de Vries 2003; Gould 2004; Kannu 2006; Martinet 2008). However, among Unique children there

are six reports of spinal curvature, in three cases progressing until surgery was needed to straighten and fix the spine with fusion or rod insertion (Unique).

"She was diagnosed with lumbar scoliosis at 9 years but has needed no treatment yet, as the curve is fairly subtle, but is being monitored every 6 months." - 6p25 interstitial deletion, 10 years

"By 15 he had developed a spinal curvature and by 20 he had had a spinal rod fitted due to the scoliosis: a great success." - 6p24 terminal deletion, 20 years

We wish we....

...had worried less and enjoyed her more! Constant worries about the future and about what your child is failing to do or missed milestones often mean that you lose focus on what your child is actually doing and achieving! Celebrate the small things, however small they seem.

■ **Genitals**

Minor anomalies of the genitals and reproductive system appear to be somewhat more common among babies and children with a chromosome change than among others, and this is true of those with a 6p25 or 6p terminal deletion. However, most baby girls are born with normal genitals.

Among the anomalies seen in boys are generally small genitals and a small, even buried penis; testes that have not descended into the scrotum and may need to be brought down and fixed with surgery; hypospadias, where the hole usually at the end of the penis is on the underside; and a 'shawl scrotum' arranged over the penis. In addition to a buried penis, one Unique boy had a hydrocele (fluid round the testis) and a left inguinal hernia (in the groin), needing corrective surgery. Altogether 7/9 baby boys reported in the medical literature and 5/16 Unique boys were affected (Jalal 1989; Palmer 1991; Law 1998; de Vries 2003; Gould 2004; Unique).

It is much more unusual for the genitals of girls to be affected by a chromosome change, but this was observed in more than one in 10 baby girls. Usually the lips on either side of the vagina are affected: they may be fused; or underdeveloped; or wrinkled. In two baby girls where the pregnancy was terminated, the ovaries were examined and found to be immature or not properly developed (Plaja 1994; DeScipio 2005; Tonoki 2011; Delahaye 2012).

■ **Eczema and other skin conditions**

Dry skin and eczema are mentioned in both published medical research and by numerous Unique members. Dry skin may develop in early babyhood and require standard emollient treatments and prescription cortisone ointments and creams. Cradle cap has also been seen in a child, and it is possible that children in nappies may need strong barrier care. One Unique member also has psoriasis and one child has had morphoea, a localized form of scleroderma (see [Unusual features of hands and feet](#) Comments) (Law 1998; Davies 1999; Anderlid 2003; Gould 2004; Mirza 2004; Koolen 2005; Unique).

A child with a 6p deletion of Hispanic parents has been described as unusually fair-skinned (Mirza 2004). An adult with an interstitial deletion between 6p25.2 and 6p25.3 reported hair loss starting in her third decade, brittle nails, and poor healing of scars (Vernon 2013).


■ Epilepsy

In the medical literature two children with a 6p deletion have been reported to have seizures (fits). One child of 2 years had around 60 seizures a day, lasting around a minute each; another had 'spasms' but a normal EEG (electroencephalogram, tracing of the electrical activity in the brain) at around 2 months (Mirza 2004; Lin 2005). Among Unique members, one child with an interstitial deletion at 6p25 had infantile spasms at five months; they were controlled with steroid medication and vitamin B6, and at 10 years the child has had no further seizures. Another child has epilepsy-like brain activity while asleep, and has had unexplained faints, but at 8 years no seizures. An adult of 25 had three or four epileptic episodes, controlled with anti-epileptic medication; no seizures have occurred for the past 9 years (Unique). In the UK about 1:30 people have epilepsy at some point in their life.

■ Development

Babies set their own developmental timetable, and delay is common – but the range is very broad

Babies with a 6p25 or 6p terminal deletion generally follow the developmental sequence of other babies, but they set their own pace. Most often, this is somewhat slower than other babies, but with support and stimulation they get there in the end. It has been estimated that 94% of children experience developmental delay (Delahaye 2012). This may be an overestimate because children without delay are not usually referred to genetics. At least two adults without any learning difficulty are known, one with an interstitial deletion measuring 2.54 Mb between 6p25.3 and 6p25.2, and one with a 6p25 microdeletion, as well as a child with average abilities (Anderlid 2003; Vernon 2013; Unique). Others are known with only a mild degree of delay (Lin 2005; Kannu 2006; Unique).



Boy with 6p25 microdeletion, 5 years

Most children have preferred areas of development where they make faster progress, but generally all areas are affected. Families are usually the first to notice any delay, but if it is subtle, it can be hard for a first-time parent to spot. In babies with a 6p25 or 6p terminal deletion, delay was most often noted from 6 months; but in one baby it was obvious by 2 months, while in other children delay was only reported at 18 months to 2 years (Mirza 2004; Lin 2005; Martinet 2008).

The degree of developmental delay varies widely, and depends in part on the size of the deletion with children with smaller deletions typically developing with less delay than those with larger deletions. However, this is not a hard and fast rule, and one child with an interstitial deletion from 6p25 is severely affected. Where it has been formally assessed, a child of 18 months had the development of a 5-6 month old; a child of 2 years had the development of a 15-month-old; one 3 year old had the development of a 14-16 month old, another the development of an 18-24 month old; a 3½ year old child had a developmental quotient of 40; one 5-year-old with a terminal deletion from 6p23 had severe delay, while another with a 6p25.1 terminal deletion was only 1 year behind at the same age; a child of 5 years 9 months had the development of a 2-4 year-old; a 6 year old had a 3 year developmental level (Jalal 1989; Palmer 1991; Plaja 1994; Chen 2004; Mirza 2004; DeScipio 2005; Lin 2005; Unique).

Children's progress is strongly affected by early intervention and the amount of support they receive. Nonetheless, some delay may remain: a child of 11½ was still 2-3 years delayed despite therapies (Bedoyan 2011).

"He is behind on fine and gross motor activities and processing information takes a little longer." - 6p25 microdeletion, 5 years

"Slightly delayed, but she has had physical therapy, occupational therapy and speech therapy since about 18 months of age and attended a special needs preschool at 2 years 9 months." - 6p25 terminal deletion, 6½ years

"In many areas, she is at the level of a 2 year old. She learns best by routine and is very single-minded and determined if she wants something such as a biscuit. She attends a 'Forest School' and loves learning in the great outdoors." - 6p25 interstitial deletion, 10 years

"He is learning disabled but loves music, and has a small accordion, drums, guitars, and a good sense of rhythm." - 6p21 terminal deletion, 34 years

■ Head control, sitting, standing, walking

Babies set their own timetable in learning to sit, stand, move and walk

The sequence in which babies learn to master their bodies is roughly the same in babies with and without a 6p25 or 6p terminal deletion. First head control, then rolling, supported sitting, sitting alone, becoming mobile, standing with support, and so on. The age when they reach each milestone is largely determined by their own developmental clock, but can be influenced by stimulation, exercises, play and physiotherapy, as well as by their good health and even mood. Marked delay in reaching a milestone can be the first sign of a

chromosome disorder. One child with initial motor delays had caught up by 4 years (Anderlid 2003).

It has been estimated that all babies with a 6p terminal deletion have low muscle tone (Delahaye 2012), making their bodies feel limp and floppy and making it especially effortful for them to make movements that are no trouble to babies without hypotonia. Early intervention with physiotherapy and regular exercises can improve low tone and may eliminate it.

Reports in the medical literature show that babies were late to gain steady head control, to sit, move and children started walking between 16 months and 3½ years (Davies 1999; Mirza 2004; Martinet 2008). Once on their feet, some children still faced extra difficulties of endurance, strength and balance,



Boy with 6p25
microdeletion,
8 months

compensating by only walking relatively short distances and relying on a pushchair for longer than other children. Their style of walking could also remain clumsy or wide-based to maintain balance, even as an adult (Palmer 1991; Caluseriu 2006). Some children walked on their toes, resisting putting their heels to the ground (Palmer 1991).

Babies in this group learned to roll over between the ages of 4 and 15 months and were able to sit up between 5 and 22 months. They became mobile between seven months and six years, either by crawling, commando crawling, scooting or bottom shuffling. The earliest walkers were on their feet by 15 months, but others were not walking until 4 or 5 years. Early intervention and physiotherapy are important for children showing significant delay and some children have shown catch up in motor skills (Unique).

“He walks with a slightly abnormal gait but hasn’t needed therapy as his problems are mild. These days he most enjoys biking without trainer wheels, and has normal biking skills for his age.” - 6p25.3 microdeletion, 5½ years

“Severe gross and fine motor delay; being assessed for a power chair, and he uses splints. Favourite activities: bowling, swimming, throw and catch.” - 6p25 deletion, 8 years

“He started to walk with a k-walker at 2 and by 5 was walking unaided. He still needs help at times around obstacles and near traffic for safety reasons. His feet turn in (eversion) and he has a tendency to toe walk, plus he is hypotonic in his arms and legs. His arms, shoulders and hands/fingers are tight but improving but there is very little treatment available. We keep him as active as possible and do ankle stretches daily, mobilising his toes and ‘pulling’ his big toes into correct alignment.” - 6p23p25 deletion, 10 years

“At 2, she was learning with help to walk up and down stairs. At 3 she could walk

up and down stairs independently. At 6 she could run and jump. Now she walks with a gait, tires easily and tends to be clumsy, but most enjoys going to the swimming pool (she doesn't swim unaided) and being in the great outdoors! Her respite centre says she enjoys 'plane spotting' (being outdoors, taking everything in, looking up at the sky!)" - 6p25 interstitial deletion, 10 years
"Very mobile, only uses wheelchair for distances." - 6p24 terminal deletion, 20 years

"She walks with an uneven gait and protruding bottom due to discrepancy in leg length and the outcome of Perthes disease. She cannot walk great distances, and has difficulty running and with sports. She cycles but cannot swim. She has passed her test and drives an automatic car." - 6p25 terminal deletion, 29 years

"He still needs to hold on to a banister or rail going up or down stairs. If he has nothing to hold, he will crawl up or bump down on his bottom." - 6p21 terminal deletion, 34 years

■ Using their hands: fine motor and co-ordination skills; personal care

Extremely varied abilities

Hand and eye co-ordination skills such as holding and playing with small toys and holding implements such as cutlery and writing implements does not necessarily develop in line with gross motor skills. Some children are dexterous and well coordinated; others find gripping and grasping difficult and unrewarding. Children with weak hands or very flexible joints in their hands find holding objects especially difficult. Early intervention with play and occupational therapy to stimulate hand use is almost always very helpful, and parents recommend chunky or triangular pens and pencils, keyboards and toys with lights and music for early skills and stringing beads and cards, and flat/ lightweight cutlery for more advanced development.

Work at the child's level, not the level you wish he was at.

This range of skills impacts on children's ability to feed themselves, to use a spoon and fork, to dress and wash, and later to use an implement such as a pencil for drawing and writing. Children who have mastered play skills well and on time may still need support from occupational therapy for handwriting. Evidence from the medical literature suggests that young children with large terminal deletions from 6p24 have the fine motor skills of a child a year younger, while coordination difficulties can persist into adulthood (Zurcher 1990; Chen 2004; Lin 2005; Caluseriu 2006).

Daily tasks like getting dressed and undressed, washing and brushing teeth will also be difficult, but using stretchy clothes, Velcro fastenings and slip-on shoes helps. Children progress with daily repetition, cues, prompts, reminders, laying out clothes, recognised routine, hand-over-hand techniques and bribery but, as ever, some get very much further than others. Children's ability with personal care directly reflects their fine motor skills and the enjoyment they take in the activity. There is an enormous range of ability, with some children needing little more than gentle reminders, while others are almost totally dependent.

Typically, children use their hands for eating, graduating late to toddler cutlery, and many needing special easy grip implements. Even with these, they may drop food liberally or throw it rather than feed themselves.

"He has fine motor delay; and a weak grip with a pen. The thumb splint from OT has been helpful. He can take off clothes, but needs help dressing and bathing; he can wash and dry his hands independently, but needs help wiping after a bowel movement." - 6p25.3 microdeletion, 5½ years

"She uses pencil grips, and a binder for writing that elevates her wrist while writing." - 6p25 terminal deletion, 6½ years

"He does not have a correct pencil grip yet but, when prompted, does use a knife with his fork for meals. He can dress and undress himself but is unable to open or close buttons or tie shoe laces. He washes his face and hands. He is starting to brush his teeth, but not yet squeezing toothpaste onto the brush. He attempts to comb his hair but the back of his head and around his ears are very sensitive so he does not like combing his hair or having his hair combed or cut. He is starting to have a shower with minimum assistance but is not yet able to completely wash himself. We are working on washing his hair himself during his bath. He can get into and out of the bath unassisted, but supervised. He can get into the shower, close the doors and turn the shower on by himself. We try to keep to a routine so he knows what to expect and what is expected of him, laying clothes out in the order they are put on, and assisting only when necessary." - 6p23p25 deletion, 10 years

"She has trouble with her fine motor skills and never uses a pincer movement ie, thumb and forefinger. She can only hold a pencil or similar with a fist grip. She will hold a spoon but doesn't use a knife or fork yet. She needs assistance with all aspects of her personal care and cannot dress, wash or feed herself independently." - 6p25 interstitial deletion, 10 years

"He needs a lot of support with all aspects of daily life." - 6p24 terminal deletion, 20 years

"He needs help washing and dressing." - 6p21 terminal deletion, 34 years

Toilet training

As for toilet training, it was significantly delayed in all children known to Unique or reported in the medical literature. Day time control was achieved between 3 and 11 years, but an 8-year-old is just starting training, and one 10-year-old is not yet trained. Night time control sometimes follows quickly, but is significantly delayed for many and for some is not possible (DeScipio 2005; Unique).

"Bribery. We gave him a special toy to play with for a day and then rewarded him with it only when he did as asked, eg 'Do bowel motions in toilet.' We also used a gimmicky toilet seat and solid wooden steps with rails to get up on the toilet."

"We use behaviour charts to assist with motivation. She lacks interest in self-care."

■ Communication

Children start speaking late. Hearing loss is common and should be regularly monitored.

Among children with a 6p25 or 6p terminal deletion, delay in communication, speech and language is to be expected, but Unique's experience is that with speech therapy most children do learn to communicate their needs and feelings, and generally learn to use words and phrases. Some children go on to speak fluently, but this is not possible for all.

We wish we'd known ...

... that his language delay might improve as dramatically as it has. He was hardly speaking at diagnosis, at 2½ years, and now can have conversations with us.

- 6p25.3 microdeletion, 5½ years

Because hearing loss is so common, and can be progressive, it is vital that children have regular hearing checks and are treated promptly for any hearing loss (Delahaye 2012). Unique's records show children first starting to babble after getting hearing aids, and in some cases achieving age-appropriate language skills and learning to talk very well with auditory therapy support. One child was educated at a school for the hearing impaired (Law 1998).

Overall, the picture is varied, but some researchers have found universal language impairment (Descipio 2007); certainly, speech delay can exist in the absence of any learning difficulties and can be marked: a 4 year old girl had severe impairment especially in understanding phrases and concepts and difficulties in explaining, relating and in the social interaction of speech and a lack of eye contact (Anderlid 2003). Another child of almost 2 years had severe delay in both understanding and talking and a moderate to severe difficulty with articulation (Lin 2005); and a 5 year old had a severe language delay (Koolen 2005).

A delay in developing speech may be one of the first signs of the 6p deletion, and is frequently the area of most obvious developmental delay (Lin 2005; Unique). Unique records show that children typically understand more than they can express. They typically say their first words at the age of 2 or 3. Reports in the medical literature show that children can have a very limited vocabulary at first (Law 1998; Lin 2005) and even in adolescence can continue to use predominantly single words as well as alternative ways of communicating, including signing (Jalal 1989; Lin 2005). By the ages of 3 or 4, children may be linking words or signs to form phrases (Lin 2005; Bedoyan 2011); constructing simple sentences by the late primary school years (Le Caignec 2005); and some children go on to speak relatively fluently (Le Caignec 2005; Delahaye 2012). Learning to sign is one important step towards learning to speak for most children who also supplement their communication with eye contact, facial expressions, gestures, vocal noises, pushing, patting and pulling, shouting and crying. Older children can be taught to use speech aids, pictures and communication devices. Many children have difficulty articulating speech clearly enough to make

themselves understood, especially outside family and friends, a problem that can extend into adulthood (DeScipio 2005; Le Caignec 2005; Lin 2005; Caluseriu 2006; Martinet 2008; Unique).

Speech therapy is vital for all children with a 6p deletion and communication problems. One family found that confidence therapy was even more useful. Another stressed the importance of talking face-to-face (Unique).

"His speech articulation is not as good as his peers, but he uses 2-3 word phrases and some longer sentences. His receptive language is a little better than his expressive language. What has helped most is lots of therapy, visual prompts, pictures, repetition, and the Hanen It Takes Two to Talk® program." - 6p25 microdeletion, 5 years

"His infant babbling was abnormal. By 3, he had many words and some 2-3 word combinations but a lot of problems with pronunciation. He could not make the sounds *p* or *b* so substituted other sounds. Now his speech is quite good: he speaks in complex sentences, almost normal for his age, but still has articulation problems, and when using long sentences can be harder to understand. He still needs to try harder than average to make his speech intelligible due to oral motor weakness. He also still has difficulty understanding some questions. *Sh* and *ch* sounds are still hard for him, but are improving. Frequent speech therapy has been helpful." - 6p25.3 microdeletion, 5½ years

"She stops at her front teeth and has difficulty making smooth sounds. She has had her frenulum (under the tongue) cut to assist tongue mobility. She learned Baby Signs (which I highly recommend to any parent) at about 16 months and we believe that helped with her communication." - 6p25 terminal deletion, 6½ years

"He can say about 20 words; put 2-3 words together; and understands *a lot* more than he can express. He uses Makaton; and he still has difficulty saying *f* and *s*. We do a lot of face to face; Jolly phonics and Mr Tongue are brilliant." - 6p25 deletion, 8 years

"At 2, she had no speech but had mastered a few Makaton signs. By 3 she was starting to babble and had a few recognisable words - mama, papa, hair, and ball. Now, at 10, close family and friends can recognise her 'words' but others find it extremely difficult to understand her. She finds most speech difficult and often just makes monotone sounds. *D* she finds difficult: she says 'yayee' instead of Daddy. She uses Signalong signing and Makaton to reinforce her speech. We, her school and others feel that she has a higher understanding of things than she can express. She understands basic commands, if expressed in simple, 1-2 word language." - 6p25 interstitial deletion, 10 years

"As a young child, he had sensory issues in this mouth which made the production of sounds difficult for him. He had about 40 signs and some words, but they were difficult to understand. He would vocalise the correct number of syllables, but the sounds were limited. Now that he is 10, his speech has improved but is still difficult to understand. He supplements his speech efforts with actions and pictures from his picture folder. He is constantly trying to

communicate, for example things he has done in school or things that he wants to do or play. At best, he communicates in 2 or 3 word sentences, and tends to have a number of these which he repeats. His understanding is much more advanced than his speech. He picks up familiar words from the radio and from conversations and will attempt to repeat them using actions, signs or pictures to help us understand what he has heard.

"The sounds he finds difficult are *d, f, j, q, s t, x*, and *z*. What helps most is repeating words, and making up songs he can sing along to, with a lot of repetition. One speech therapy approach was associating an action with each sound, such as putting his hand in front of his mouth to feel the blow when he makes the sound *puh*, or feeling his throat when he makes the *guh* sound. These are concrete associations with the sound and work really well. We rarely accept his first attempt at a word when we know he can say it more clearly. We ask him to repeat it and give him the action prompt, as above. Jolly phonics is also useful." - 6p23p25 deletion, 10 years

"Over the years his vocabulary has extended and he has learned to make sentences. Much of his speech is quite hard to understand, but he will spell words. He loves being with others." - 6p24 terminal deletion, 20 years

"Speech therapy did not help but confidence therapy did." - 6p25 terminal deletion, 29 years

"He cannot converse but will cuddle, and high 5 et cetera with everyone. He is very friendly and loves attention." - 6p21 terminal deletion, 34 years

■ Learning

Children will usually need support with their learning

Children with a 6p25 or 6p terminal deletion are very likely to need some support with their learning, although the extent varies widely. Evidence from the medical literature and from Unique families shows a scattered pattern, with great variation in the skills achieved, even among people with apparently very similar chromosome deletions.

There are reports in the medical literature and at Unique of children and adults with no learning difficulties (Anderlid 2003; Chen 2004; Mirza 2004; Lin 2005; Vernon 2013; Unique) and other children and adults with only mild difficulties (Lin 2005; Caluseriu 2006; Kannu 2006; Martinez-Glez 2007; Unique). One 15 year old boy in Unique was the best reader in his class at school, while other children with a very similar 6p deletion had a marked learning disability. A Unique member passed 8 GCSE examinations, which are the national examinations that are taken in the UK at 16, followed by a vocational qualification in child care. Others by contrast have a moderate or even severe level of learning disability (Jalal 1989; Mirza 2004; Koolen 2005; Unique). A child of 11 is 2-3 years behind despite therapeutic support (Bedoyan 2011).

Children attend mainstream schools or special schools for children with learning difficulties or a hearing impairment, and follow individually designed

learning programmes or programmes designed for children within the autistic spectrum (Law 1998; DeScipio 2005; Kannu 2006).

Only one child has a formal IQ test result, with a score of 35-60 at 15 years (Jalal 1989).

"He has a good memory; and wants to please. He enjoys reading books with his parents and can draw lines and some basic letters. Overall we do not know if he will have a specific learning disability and he is achieving at the level of a 4-5 year old." - 6p25 microdeletion, 5 years

"We don't know yet if he has a learning difficulty. He enjoys being read to, and is good at learning material read to him from a book. He can already read some simple sight words, draw simple shapes and write his first name. He attends a private school which is very welcoming of children with special needs, and there are others with special needs in his class. He shares an educational assistant with another child. ABA (Applied Behaviour Analysis) therapy – a type of behaviour modification – helps with his difficulties concentrating." - 6p25.3 microdeletion, 5½ years

"She has to have testing (spelling and math) different from most children and 1:1 with the teacher. Currently she is working at 1st grade level. She has an incredible memory and will try almost anything, but is very easily distracted. She receives a lot of learning support – at school and at home! We would recommend to other parents Handwriting without Tears™ (www.hwtears.com)."- 6p25 terminal deletion, 6½ years

"His learning is helped by him being very strong-willed and knowing what he wants and doesn't want. He has a very good memory. He learns best 1:1 in a quiet environment. Repetition and patience are helpful." - 6p25 deletion, 8 years

"In many areas, she is at the level of a 2 year old. She attends a special school for children with severe and complex needs, and loves learning in the great outdoors. She seems to have a very good memory and learns best by routine!" - 6p25 interstitial deletion, 10 years

"Our son has a moderate learning difficulty. He is in a special class in a mainstream school and has an assistant with him who is trained in the Hanen® technique and signing. He is not interested in number work, but enjoys participating in reading and writing, especially when activities are practical such as making a card for a friend. He can perform very well when the activity is something personal to him: he draws circles, straight lines across, up and down, working on shapes by helping him draw his favourite things such as fire engines and buses etc. He is determined and wants to please, which help his learning as do consistency and repetition." - 6p23p25 deletion, 10 years

■ Behaviour

Children are generally friendly but autism is a recurring diagnosis

Most children and adults with a 6p25 or 6p terminal deletion are pleasant and well-adjusted. However, in the medical literature there are four reports of children diagnosed with an autism spectrum disorder, and one child follows an

education programme for children with autism (Koolen 2005; DeScipio 2005; Tonoki 2011; Delahaye 2012). There are also a few reports of behaviour difficulties, including self injury, temper, and aggression (DeScipio 2005; Le Caignec 2005; Delahaye 2012). One adult has been reported with increasing difficulties in social functioning from the age of 26, increasing irritability and depression and finally a diagnosis at 33 of schizophrenia, which is successfully treated with the anti-schizophrenia medicine clozapine (Caluseriu 2006).

Among Unique members, there is great variety, and no evidence of any particular pattern of behaviour typical for a 6p deletion. Strengths noted by families include happiness; emotional sensitivity; generosity; friendliness; sense of humour; and sociability.

Among the difficulties encountered by families are a short attention span and lack of concentration; being easily overwhelmed, excited or anxious; aggressive reactions, including biting, kicking and shouting; sleep difficulties; and behaving inappropriately or in an over familiar way with people. Below, families mention their management techniques; in addition, some use medication to improve and enhance the good aspects of their child's behaviour.

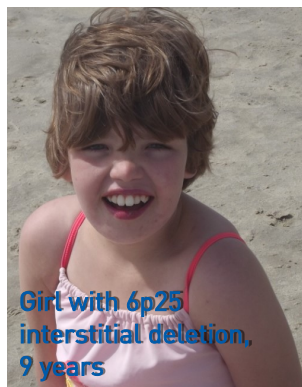
"His behaviour is good. He is shy in some new situations if he is on his own; if with his little brother he finds it easier to engage." - 6p25 microdeletion, 5 years

"He generally behaves well unless he is tired, sick or frustrated by tasks he finds difficult. When fatigued, he becomes hyperactive. He can be quite anxious at times, especially with medical procedures. He still has tantrums on bad days. He was diagnosed with autism at 2 before the diagnosis of the 6p25.3 deletion. He is very social with people he knows and trusts, but can be standoffish with unfamiliar kids and adults." - 6p25.3 microdeletion, 5½ years

"Great, though she lacks confidence and is easily distracted." - 6p25 terminal deletion, 6½ years

"Generally, well behaved, but lack of concentration, flapping, and biting his hand are difficult areas. He has been diagnosed with sensory processing disorder - helps to have pressure therapy on his hand; and taking him to a quiet room. Socially, interacts very well; everyone is his friend." - 6p25 deletion, 8 years

"Difficulties include a short attention span; lack of concentration, especially when tired; needing reminders. What works is being clear in letting him know what is expected of him and following through, as well as patience! He is very clear about who he likes and who he does not like. When he does not like someone he can be quite obsessive about expressing this (to us). With the person he does not like he is usually nervous and not able to express his feelings. Generally he is very sociable and loves being involved in group activities. He loves performing and being listened to and involved." - 6p23p25 deletion, 10 years



“Generally a very happy and good-natured child, but when upset or frustrated displays very challenging behaviour such as head banging and pinching. We attended a course run by the Challenging Behaviour Foundation (www.challengingbehaviour.org.uk) and manage her behaviour by reinforcement with single word commands and a ‘First and then’ board (eg first you must do this, then you can have a drink). She wears a hat and gloves to minimise the harm she can do, but she will now not do anything without the hat and gloves, and it is extremely difficult to get her to remove them. She is also over familiar with people, often greeting people by hitting them or cuddling and sniffing them. She is much more interested in adults than children, although she is increasingly amused by the antics of her younger sister who is a force of nature and a real ray of sunshine in her life.” - 6p25 interstitial deletion, 10 years

“He has the odd bout of frustration. He complains of headaches, but we think he becomes very anxious about anything.” - 6p24 terminal deletion, 20 years

“Has lacked confidence, but now improved. A generous person, quite individual. She is still slowly gaining more confidence.” - 6p25 terminal deletion, 29 years

“Very happy and loves company, copes well with change, no sense of danger, loves music, especially Scottish music with accordion and bagpipes, loves his food! Very friendly and mischievous.” - 6p21 terminal deletion, 34 years

Sleep

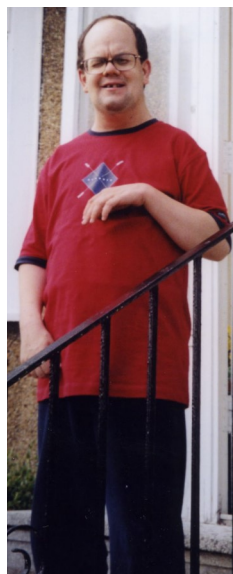Most Unique families do not report that their child has sleep problems. Four families have reported persisting difficulties; their solutions were to follow a strict bedtime routine, declutter the bedroom and give a small dose of melatonin if needed (10 years); to follow sleep training taught by a behaviour nurse (7-10 years); to give a very small dose of chlorpromazine at night to reduce anxiety (34 years).

Outlook

There are great differences in health and wellbeing between individual children and adults with apparently similar deletions from 6p25. Clinical differences explain much of the difference: for example, babies born with serious heart problems in general have a harder time than those born reasonably healthy.

Among adults reported in the medical literature with a 6p25 deletion, a man of 32 worked full time as a machine operator for 10 years, passed his driving test and lived with his parents (Law 1998). A woman of 36 lives in a group home with frequent family contact and enjoys activities in the community such as hairdressing and cooking (Caluseriu 2006). A woman of 41 with no learning difficulties but multiple health problems has an adult son and lives in the community (Vernon 2013).

Adult with 6p
terminal deletion



Among Unique members, a woman of 29 is in fairly good health although she has needed two blood transfusions for anaemia in the past two years; she works as a nursery assistant, and drives herself to work. A man of 34 is in very good health and lives at home with full support and attends a day centre where he follows a varied programme as well as a gym, golf driving range and indoor bowls. A man of 20 is generally in good health and lives at home with his parents and does not work, but attends a youth club and other events with day support services. An adult man with a microdeletion is unaffected and is professionally employed.

Management recommendations

- Eye evaluation
- Heart evaluation
- Brain imaging
- Hearing tests
- Early developmental assessment
- Radiological follow-up aimed at detecting epiphyseal dysplasia (Kannu 2006; DeScipio 2007).

Why did the 6p25 deletion occur? Did my baby get it from me? Was it my fault?

6p25 deletions usually occur out of the blue for no obvious reason. Less often, they can be caused by a change in either the mother's or the father's chromosomes. The only way to be certain is to check the chromosomes of both parents.

If both parents have chromosomes without any relevant changes, the 6p25 deletion is a new occurrence. The genetic term for this is *de novo* (dn). A new 6p25 deletion has been caused by a mistake either when the parents' sperm or egg cells were formed or in the very earliest days after fertilisation. As a parent there is nothing you could have done to change or control this.

In a few families, one parent has a structural rearrangement of their own chromosomes. This is usually balanced so that all the genes and chromosome material are present and the parent is entirely healthy. However, these families have an increased risk of having another affected child.

Occasionally, a small 6p25 deletion can be inherited direct either from the mother or the father.

Whether the deletion is inherited or *de novo*, there is nothing you did as a parent to cause the 6p25 deletion. No environmental, dietary, workplace or lifestyle factors are known to cause these chromosome changes.

Can it happen again?

In families where both parents have been tested and have chromosomes without relevant changes, the risk of having another child with a 6p25 deletion is only minimally higher than anyone else's risk.

If a blood test shows that either parent has a balanced chromosome rearrangement involving 6p25, the possibility of having other affected pregnancies rises considerably. Someone who themselves has a deletion of 6p25 has a theoretical possibility of passing it on of about 50 per cent in each pregnancy and a 50 per cent chance of a pregnancy with normal chromosome 6s.


Your genetics centre should be able to offer counselling before you have another pregnancy and if you already have a child with the 6p25 deletion, prenatal diagnosis will be possible if that is what you choose.

Can my child have children of their own?

It isn't yet known whether the condition affects fertility, but there are both men and women with a 6p25 deletion who themselves have children (Vernon 2013; Unique). Anyone with a 6p25 deletion has around a 1:2 (50 per cent) theoretical chance in each pregnancy of passing it on.

Genes

We don't know yet what most of the genes in the 6p25 region do, but the role of the *FOXC1* gene is increasingly clear. The full name of this gene is Forkhead box C1. It is found in band 6p25.3 between base pairs 1,610,680 and 1,614,131.



This gene provides instructions for making a protein that regulates the activity of other genes. The FOXC1 protein is called a transcription factor and plays a vital role in the early development of an embryo. Having too little FOXC1 protein (or too much) disrupts the regulation of other genes needed for normal development. The right amount of FOXC1 protein is important for the correct development of the front part of the eye, that is, the coloured part of the eye (iris), the black central hole (pupil) and the clear front covering of the eye (cornea) (Lehmann 2003). However, not every person who has lost this gene has structural eye anomalies. Some people with structural eye anomalies have an intact *FOXC1* gene but have lost DNA from near the gene, suggesting that disruptions near the gene can also cause eye problems. When a gene is disrupted in this way, it is called a 'position effect' (Gould 2004).

FOXC1 protein is also important for the correct development of other parts of the body, including the brain and heart.

While identifying the gene(s) responsible for certain features of a 6p deletion is valuable and may help guide future studies, it does not lead directly to immediate improved treatment. Also, even if the supposedly responsible gene is missing, it does not always mean that the associated feature(s) will be present. Other genetic and environmental factors often have a role in determining the presence or absence of a particular feature.

What is special about your child?

A very affectionate, thoughtful child - 6p25 interstitial deletion, 5 years

A generally happy boy who loves spending time with his family. He loves music and dancing and really enjoys reading books with us - 6p25.3 microdeletion, 5½ years

My son has made me realise that worrying about the small stuff is a waste of time and energy. Every day needs to be cherished. He fights everyday to do some of the most normal things we take for granted, and yet he still laughs and smiles - 6p25 deletion, 8 years

He makes people smile. He has grounded me and made me see the world differently - 6p23p25 interstitial deletion, 10 years

She has a great sense of humour and loves to laugh (an almost wicked sense of humour if we're honest!). She has taught us patience and empathy and to have a much greater regard for and understanding of the needs of others than perhaps we had before. She has made us stronger and much more determined to stand up for what we believe in and above all to make sure we get what we need to make her life and our lives easier - 6p25 interstitial deletion, 10 years

A real character and makes everyone laugh. He tries his hardest to achieve everything - 6p24 terminal deletion, 20 years

Very friendly. We talk to many people we would not normally talk to and everyone is kind and makes a fuss of him, which he loves! - 6p21 terminal deletion, 34 years

Support and Information



Understanding Chromosome & Gene Disorders

Rare Chromosome Disorder Support Group,

The Stables, Station Road West, Oxted, Surrey RH8 9EE, UK

Tel: +44(0)1883 723356

info@rarechromo.org | www.rarechromo.org

Join Unique for family links, information and support.

Unique is a charity without government funding, existing entirely on donations and grants. If you can, please make a donation via our website at:

www.rarechromo.org/donate

Please help us to help you!

Chromosome 6 research project

The C6 project works with families to collect detailed information with the aim of linking specific disease characteristics with specific regions of chromosome 6.

<https://www.chromosome6.org/>

Facebook page for chromosome 6

www.facebook.com/groups/chromosome6

Unique lists external message boards and websites in order to be helpful to families looking for information and support. This does not imply that we endorse their content or have any responsibility for it.

This information guide is not a substitute for personal medical advice. Families should consult a medically qualified clinician in all matters relating to genetic diagnosis, management and health. Information on genetic changes is a very fast-moving field and while the information in this guide is believed to be the best available at the time of publication, some facts may later change. Unique does its best to keep abreast of changing information and to review its published guides as needed. The guide was compiled by Unique and reviewed by Professor Ordan Lehmann, Departments of Ophthalmology & Medical Genetics, University of Alberta, Canada; and by Dr Andrée Delahaye-Duriez, Hôpital Jean Verdier, Bondy, France. V1: 2013 V2 2014(PM)

Copyright © Unique 2014