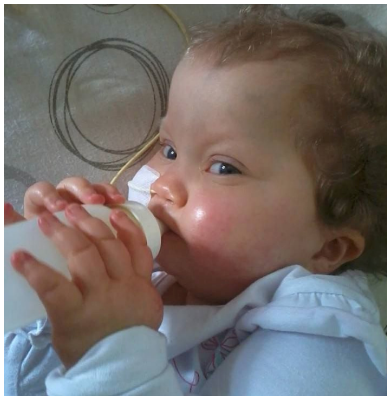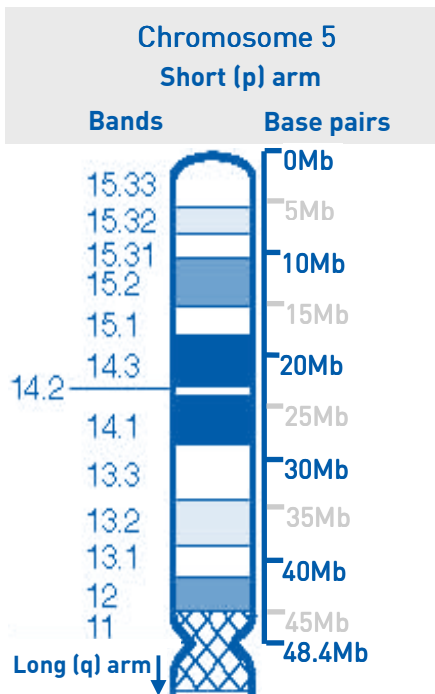


Trisomy 5p: Duplications of the whole 5p arm



Duplications of the whole of the short arm of chromosome 5



A duplication of 5p, also known as **Trisomy 5p**, is a rare genetic condition that occurs when there is an extra copy of part of the genetic material (DNA) in one of the 46 chromosomes – chromosome 5. This extra copy is known as a duplication. People have two chromosome 5s, but the extra DNA is found in only one of them. This usually affects development, and sometimes health and behaviour as well. But how much it affects individuals, and the ways in which it affects them, can vary a lot. The precise effects vary depending on how large the duplication is, how many genes it contains and what those genes do. The effects may not be limited to the genes within the duplicated piece of chromosome because these genes may interact with other genes on chromosome 5 or other chromosomes.

Genes and chromosomes

Our bodies are made up of trillions of cells. Most of the cells contain a set of around 20,000 different genes; the genetic information they carry tells the body how to develop, grow and function. Genes are carried on chromosomes. Chromosomes usually come in pairs, one chromosome from each parent. Of the 46 chromosomes, two are a pair of sex chromosomes: two Xs for a girl and an X and a Y for a boy. The remaining 44 chromosomes are grouped into 22 pairs and are numbered 1 to 22, approximately from largest to smallest, so chromosome 5 is quite a large chromosome. Each chromosome has a short (p) arm (from petit, the French for small) as well as a long (q) arm (*see* Diagram, above).

Sources

Only 9 babies and young children have been described in the medical literature with a whole 5p duplication [Leschot 1979; Carnevale 1982; Orye 1983; Fujita 1994; Zhao 1995; Reichenbach 1999; Velagaleti 2000; Grosso 2002; Reddy 2003]. The first-named author and publication date are given to let you look for the abstracts or original articles on the internet in PubMed (www.ncbi.nlm.nih.gov/pubmed). This guide also draws on a survey of members of Unique conducted in 2014, referenced Unique. Unique has 4 members with a complete 5p duplication, and 3 with a duplication of most of 5p. In 2 of the children, the condition is mosaic, with cells with the extra 5p and cells with normal chromosomes: this usually moderates the effects, but effects can be hard to predict.

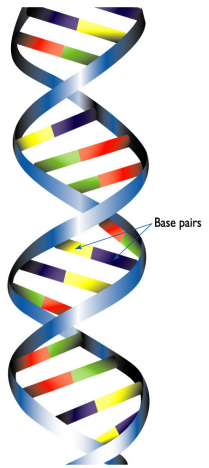
Looking at chromosome 5p

Chromosomes can't be seen with the naked eye, but if they are stained and magnified under a microscope each one has a distinctive pattern of light and dark bands. You can see these bands in the diagram on page 2.

Each band of each chromosome contains millions of base pairs of DNA. Base pairs are the chemicals in DNA that form the ends of the 'rungs' of its ladder-like structure. The whole of chromosome 5 has about 181 million base pairs, shortened to 181Mb; the short p arm has rather more than 48Mb.

The position of each of the 900 or so genes on chromosome 5 is measured in base pairs. On the right of the diagram you can see how the base pair numbers relate to the bands.

Looking at chromosomes under a microscope, it is usually possible to see a piece of extra genetic material as large as a duplication of most or all of 5p which could measure as much as 48Mb. Changes smaller than 5Mb or even 10Mb can be hard to identify. New techniques, particularly one known as array CGH, are better for finding small changes, and are now often used to find the size and position of the extra DNA, helping to identify genes and pinpoint their location on chromosomes.



How did this happen?

Most commonly, the short arm of chromosome 5 has attached to the middle of one of the chromosomes whose short arm can be lost without any apparent harm, that is, 13, 14, 15, 21 or 22. Occasionally there is an extra chromosome made up of two copies of 5p: this is known as an isochromosome.

Genetic test results: two examples

A person's chromosome make-up is called their karyotype. Someone with a very large 5p duplication might have a karyotype that looks like one of these:

46,XX,der(15)t(5;15)(p12;p11)mat

This result tells you that the chromosomes were examined under a microscope.

46 chromosomes were seen, the correct number. The sex chromosomes were two Xs, so this is a girl or woman. der(15) tells you that an abnormal chromosome 15 was found. t(5;15) tells you that chromosome material had switched places (t) between chromosomes 5 and 15.

(p12;p11) tells you that chromosome 5 has broken in the p12 band, and that chromosome 15 has broken in the p11 band. This means that there is an extra copy of the short arm of chromosome 5 starting at band p12 attached to chromosome 15 at p11. mat means that the mother of this girl or woman carries abnormal but balanced chromosomes 5 and 15, and this arrangement has given rise to the daughter's 5p duplication. 'pat' would mean that the father was the carrier. If neither parent was a carrier, the term 'de novo' or its short form 'dn' would be used.

ish der(5)(p15.31p11)(RP11-624LI5++). arr 5p15.31p11(7328941-47934526)x3

This result tells you that the chromosomes were examined using two different techniques. **ish** tells you that a FISH test revealed an abnormal chromosome 5 (**der(5)**). The start point of the extra material was in band **5p15.31** and the end point was in band **p11**, so this is a large duplication. (**RP11-624LI5++**) shows that a clone, or fragment of DNA whose position on the chromosome is known was present in 2 copies (**++**) instead of 1. **arr** shows that a second, microarray, technique was used to confirm and clarify the results of the first test. **5p15.31p11** shows that the starting point was again shown to be 5p15.31 and the end point 5p11. (**7328941-47934526**)x3 shows that three copies of the material between the break points was found (x3). The normal number of copies is 2, so this means there is an extra copy. **7328941-47934526** are the start and end points of the extra copy, measured in base pairs. Take the first long number from the second and you find that there are 40,608,585 extra base pairs. This is about 40.6Mb.

Common features

The most common features are:

- Developmental delay
- Hypotonia
- Normal size at birth, but slow growth after birth
- Large head
- Seizures
- Tracheobronchial/ respiratory involvement
- Club foot, and other foot anomalies including a short first toe
- Unusual facial features including small upslanting eyes, epicanthal folds, low nasal bridge and low set ears

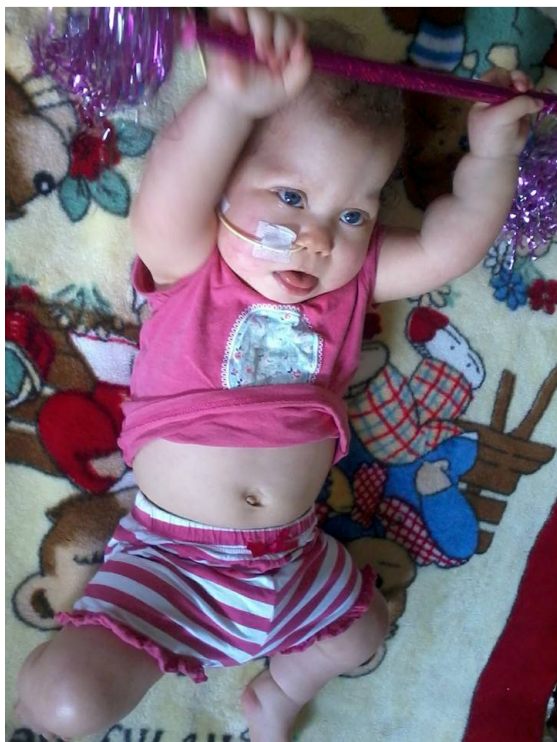(Leschot 1979; Orye 1983; Reichenbach 1999; Velagaleti 2000)

■ Developmental delay and hypotonia

Developmental delay is a consistent feature, and is usually obvious by the time a baby is a few months old. One Unique family, whose child is very delayed, first noticed the delay in their child's voice and grasp reflex, and were unclear whether it was due more to her cognitive problems or her physical difficulties. The range of developmental delay does vary, but appears to be mildest among children with a mosaic form of trisomy 5p. Among others delay is severe. Low muscle tone (hypotonia), making a baby feel floppy to hold, is also consistent and makes it harder for babies to gain physical control of their bodies. Head control, rolling and sitting all come late, especially in babies with a very large head, but one child was sitting by 18 months (Grosso 2002). Standing and walking are particularly delayed among children who were born with club foot. A Unique family points out that the underlying hypotonia is their child's greatest problem and exacerbates everything else, including feeding. At a little over 2 years, she can move by rolling, and is learning to use a walking frame. Hypotonia typically

affects the muscles of the face, affecting dribble (drool) control and the actions of eating.

In terms of learning, the evidence from Unique is mixed, but suggests a significant disability that may be moderated in those with a mosaic form of trisomy 5p. Communication can be lively and sensitive, even when speech develops late or not at all.



“We have stopped estimating her development against average children as we understand she is unique and it doesn’t matter how long it takes for her to do something. Physically, she has progressed significantly – particularly her strength and dexterity. She is enjoying clapping and making a noise slapping parts of her body.

“She communicates through facial expressions, vocal sounds, gestures, body movements (bum thrusting, clapping, thumbing her tongue – all to show she is happy/excited). She understands some things very well if they are meeting her needs. She also understands emotion and tone of voice, happiness and excitement, and can express

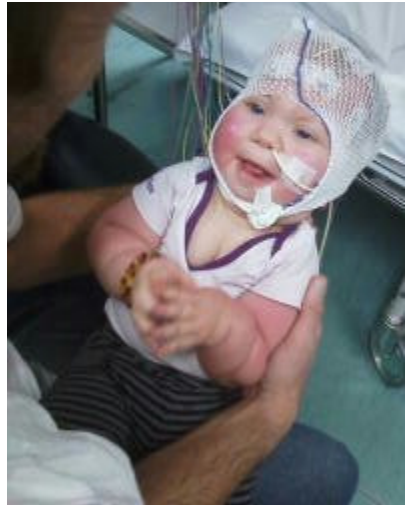these emotions very well. To help with drooling, she has a bib when teething and we keep her mouth busy so she doesn’t leave it open due to hypotonia.” 2 years

■ Normal size at birth, but slow growth after birth

Babies are usually a normal weight at birth. Among 9 new babies born at or near their due date, weights ranged from 2.7kg (5lb 15oz) to 3.53kg (7lb 13oz), and averaged 3.16kg (6lb 15oz), while a baby born at almost 37 weeks weighed 3.095 kg (6lb 13oz), well above the average for that stage of pregnancy (Zhao 1995; Unique). Two babies were born small: one diagnosed with slow growth during pregnancy, at 5 months, and born underweight at 2.85kg (6lb 5oz), and another born weighing less than 2 kg (Carnevale 1982; Grosso 2002). We only know the length of 2 babies, both above average. Although it has been said that babies grow slowly after birth, we have no information to support this.

■ Large head

A distinctive feature in babies and children from before birth is the large size of their head. Typically, at birth the head is large in proportion to the rest of the body, and it may be so large that the baby is diagnosed with macrocephaly, where the measurement round the head is in the top 3 per cent for the population norm. The soft spot on top of the baby's head (anterior fontanelle) is often much bigger than usual, and you may be able to feel it extend towards the back of the top of the head (posterior fontanelle). In due course the skull bones do knit, but it can be years before they do (Carnevale 1982; Orye 1983; Zhao 1995; Reichenbach 1999; Velagaleti 2000; Grosso 2002; Unique).



In some babies, the fluid-filled spaces within the brain (the ventricles) are enlarged, and at least 5 babies had an excessive build-up of fluid within the brain (hydrocephalus), for which shunts were need for drainage (Fujita 1994; Unique).

There is little information on other brain anomalies, but in one child clumps of grey matter were found in the wrong part of the brain (subependymal heterotopias). This causes a range of symptoms which can include seizures, and affects the brain's ability to function at a higher level. In this child the corpus callosum, the band of nerve fibres connecting the two hemispheres of the brain, was also thin and stretched (Grosso 2002).

[“Having macrocephaly makes looking round very difficult.” 18 months](#)

■ Seizures

Seizures have been seen in most babies and children with a whole arm trisomy 5p, while some babies were still too young for this to be known. One baby of 2 years had no seizures, but an abnormal electroencephalogram (EEG) pattern of the electrical activity in the brain. Seizures started at different ages, ranging from 3 months to 7 years, and were of different types: infantile spasms (brief periods of movement of the neck, trunk, or legs that lasts for a few seconds in young babies often when awakening, or going to sleep); myoclonic seizures (jerky muscle contractions usually in the arms and legs and lasting at most for a second); and complex partial seizures, which start in one hemisphere of the brain or in one lobe of a hemisphere, and affect consciousness, so the person having the seizures may look confused or behave oddly. In 3 children, seizures are triggered or made worse by illness. Seizures respond to various anti-epileptic drugs, but can prove hard to control (Reichenbach 1999; Grosso 2002; Unique).

■ Tracheobronchial/ respiratory involvement

Some babies have breathing difficulties, and many are prone to repeated and severe respiratory infections. Some children are more prone to seizures when they have a respiratory infection.

Some babies are born with an abnormality of the throat or airways that makes breathing easily more difficult: one baby was born with laryngostenosis, a narrowing of the very top section of the airway that leads from the throat to the lungs; another had an unspecified abnormality of the larynx; and another had abnormal airways leading to the lungs and bronchomalacia, where the structural framework of the bronchial airways is soft and limp. The underlying hypotonia can affect the throat and airways, making breathing efficiently harder. Two babies needed a tube inserted into the windpipe (trach/ tracheostomy) to enable them to breathe, and one still needed intermittent ventilation. One baby had such a large tongue that it blocked the airway and brought on respiratory arrest.

Respiratory problems can be evident from birth and last for months and even years; one baby was in hospital for the whole of his first year because of respiratory and feeding problems. But they can get better with time: one baby had at least 7 emergency hospital admissions for breathing or feeding issues in her first year, but almost none in her second year. Repeated severe respiratory infections are common, and can be caused or made worse by aspiration secondary to reflux (see Feeding). One baby with repeated infections was found to have low levels of the protective IgA antibody. At least 2 babies died of respiratory failure, one at 4 months and one at just over 3 years (Carnevale 1982; Orye 1983; Fujita 1994; Reichenbach 1999; Grosso 2002).

[“Although the doctors were querying aspiration on a couple of occasions, after chest x-rays and further testing, these hypotheses were disproved. She has never had a diagnosis of chest/respiratory infection or pneumonia.” 2 years](#)

■ Club foot, and other foot anomalies including a short first toe

Club foot is common, recorded in 5/8 babies in the medical literature and 3/5 at Unique. One foot, or more commonly both are affected. Most commonly it is of the talipes equinovarus type, where the foot points downwards and inwards. The foot is usually short and broad and the heel points downward while the front half of the foot turns inwards. Treatment is individually tailored and aims to straighten the foot so that it can grow and develop normally. First-line treatment can be non-surgical and may include manipulation, casting, taping, physiotherapy and splinting, followed by bracing to prevent relapse. Surgery and sometimes splinting are considered if non-surgical treatments are not completely successful. The foot position may relapse as the child grows and develops, making further surgery necessary.

One Unique baby with both feet affected was in plaster casts from 7 weeks until 6 months, followed by more than a year in Dennis Browne boots, a type of snug-

fitting, high-ankle, laced boot that can be separated by a bar, worn to keep a child's feet in position after correction of a positional problem. By 18 months the correction procedure had worked well, and her feet were in a good position for standing and walking (Carnevale 1982; Orye 1983; Fujita 1994; Velagaleti 2000; Reddy 2003; Unique).

The most common other foot anomaly is first (big) toes that are shorter than the second toes. One child also had puffy tops of the feet (dorsal pedal oedema) (Orye 1983; Zhao 1995; Velagaleti 2000; Unique).

■ **Unusual facial features including small upslanting eyes, epicanthal folds, low nasal bridge and low set ears**

Your child may look like the rest of your family, but he or she may also have some facial and other features that are common to people with trisomy 5p. The most obvious feature is the large head, but the eyes may also be smaller than normal and slant upwards; there may be a tiny fold of skin across the inner corner of the eye. The bridge of the nose is typically unusually flat, and the ears are placed lower on the sides of the head than normal. Other features noticed in Unique members include a short neck with extra folds of skin; small and oddly formed or crumpled ears; a large or protruding tongue; a long groove between the nose and the upper lip (philtrum); and sparse eyebrows.

Less common features are not so likely to be specifically related to the
5p trisomy

Pregnancy, birth and the newborn baby

Out of 10 babies, we know that 4 were born early, between 28 and 36 weeks of pregnancy, and 6 were born around term. Pregnancy was essentially normal, although in 2 there was excess amniotic fluid, one mother noted that her baby was less active than previous pregnancies, and one mother had pre eclampsia, which may not be related to the 5p trisomy. The 5p trisomy was only detected in one pregnancy, following an amniocentesis after a mid-trimester scan showed some anomalies. Other unusual findings in pregnancy include a large head in 2; slow growth in one baby; and club foot in one (Zhao 1995; Grosso 2002; Unique). Birth weights were essentially normal (see above). Information on the baby's condition in the medical literature is not always complete, but we know something about the condition of 6 babies: in two there were no complications. Among 4 babies, Apgar scores, which score a new baby's wellbeing on a scale of 0-10, varied between 2 and 6 at 1 minute after delivery, 5 and 9 at 5 minutes, and 6 and 9 at 10 minutes. The most serious and common problem was breathing difficulties, and at least 2 babies needed resuscitation after delivery, and 3 needed ventilation to help them breathe. Although heart problems are common (see below), they were only noted in one baby at birth. The most obvious unusual features – a large head, club feet – were noted in some babies but certainly not all (Carnevale 1982; Fujita 1994; Zhao 1995; Reichenbach 1999; Grosso 2002; Unique).

Feeding

We only have detailed information on feeding in 1 baby, and more sparse information on 5 more. Two babies, one with a mosaic form of the 5p trisomy, fed reasonably well, one breastfeeding for 9 months, the other able to drink from a cup and suck from a spoon by 8 months. By contrast, one baby was readmitted to hospital with feeding difficulties; and another was diagnosed with failure to thrive, where the baby cannot take in enough nutrients to support their own needs and growth. Two babies were tube fed, one by gastrostomy direct into the stomach, the other by nasogastric tube, exclusively for a year, and partially by 2 years. Two Unique families noted the effects of hypotonia on feeding, making it harder to swallow and chew efficiently and correctly. The hypotonia raises the risk of aspiration, where some of a feed 'goes down the wrong way' or feeds aren't efficiently processed into the stomach but instead come back up the food pipe and can be inhaled (gastro oesophageal reflux/ GORD/ GERD).

"At 18 months, she could tolerate puréed foods in controlled amounts but was at risk of aspiration, so she has a seating system for positional safety while feeding. In her first year, she was tube fed, but often tried 'tastes' of puréed food and enjoyed it very much. The tastes progressed into full feeds and now, at 2 years 4 months, she tolerates soft lumps in her food. She is trialling thickened fluid as well as having extra fluids via her nasogastric tube to ensure adequate hydration while she slowly increases her fluid volume orally. This is a very slow process as we are acutely aware of the risk of aspiration."



General wellbeing

The tendency to respiratory problems and infections means that babies can have a difficult first year. Some do not survive: out of 13 babies, 5 died, most commonly in their first year. Once past the first year, we have little information, but a Unique baby who had a typically difficult first year was generally well at 2 years 4 months.

Heart

Heart conditions are relatively common, affecting 6/14 babies born with trisomy 5p. Holes between the upper chambers of the heart (the atriums) or the lower chambers (the ventricles) were found in 3 babies, in 2 babies in combination with a further heart problem. Two babies had a persistent ductus arteriosus (PDA), again in combination with another heart problem. The ductus arteriosus, or duct, is a channel between the two blood vessels leading out of either side of the heart that usually closes shortly after birth. When it stays open, the lungs receive more blood than they should and the heart has to work too hard. If necessary, a PDA can be repaired with surgery. 3 babies had coarctation of the aorta, and one an enlarged aortic root, where the start of the aorta as it leaves the heart is enlarged. In coarctation of the aorta, the large blood vessel that carries blood from the heart to the rest of the body is narrowed, usually preventing blood from circulating normally in the lower half of the body; the narrowing can be repaired with surgery. One was suspected to have transposition of the great vessels; in TGA the main blood vessels leading out of the ventricles are switched, so blood without oxygen in it is pumped around the body. One baby had an enlarged left ventricle and right atrium (Carnevale 1982; Orye 1983; Zhao 1995; Reichenbach 1999; Velagaleti 2000; Unique).

Minor genital anomalies

Minor anomalies of the genitals are fairly common among baby boys with a chromosome disorder, and have been seen in 2/8 boys with trisomy 5p. In both, one testicle or both has not come down as normal into the scrotum, the loose sac behind the penis, by birth. In one boy the hole usually at the end of the penis is on the underside instead (hypospadias). If necessary, both cryptorchidism and hypospadias can be corrected by surgery (Velagelati 2000; Unique).

Other birth anomalies

When birth anomalies are only seen in 1 or 2 babies, it is not clear what the cause is: the 5p trisomy, or another factor. Among babies with trisomy 5p, these include: partial eventration of the diaphragm, where the muscle separating the contents of the abdomen from the chest is abnormally high, but there is no hole; if necessary, it can be repaired with surgery; hernias at the umbilicus (navel) or in the groin (inguinal), correctable if necessary with surgery; a small omphalocele, a sac containing part of the bowel that protrudes at birth through a hole in the abdomen near the base of the umbilical cord; and enlarged kidneys (Carnevale 1982; Velagelati 2000; Unique).

Eyesight

Five babies are recorded with different vision anomalies. In one, the optic disc is unusually pale; another was born with Peter's anomaly, where the cornea (the clear covering of the eye) is thinned, hazy and white (a cataract), and is attached to the iris (the coloured part of the eye), causing blurred vision; if necessary, the cataract can be removed. In a third, both eyes had a squint, and showed the

involuntary to and fro movements of nystagmus and one eye had a developmental defect of the coloured iris. Another child had a developmental defect of the right eye, causing low vision. One child had an intermittent squint in both eyes (Carnevale 1982; Velagelati 2000; Grosso 2002; Unique).

Hearing, skin, teeth

From the sparse information we have, these appear not to be affected, although two babies had the build-up of fluid in the middle ear called glue ear that is very common in all young children whether they have a chromosome disorder or not, and causes an on-and-off hearing loss that if necessary can be relieved by surgery (Unique).

Behaviour

We do not have enough information to make statements about behaviour, but the general impression at Unique is that despite some of the typical challenges that all children with a significant learning difficulty face, those with trisomy 5p can be engaging and sociable.



"She continues to be happy and engaging – she loves to be around others, and will often ignore toys to concentrate on socializing with people. It is normal to us, but most people remark on how bubbly and happy she is. When motivated by food, she can become quite demanding. We are assured that this is perfectly 'normal' and she is now learning to calm down and wait a short while for her food. She has no difficult behaviours. She LOVES people and will engage with them easily. She will often smile at a person until they return the smile. Then she will make excited gestures (clapping, tongue thumbing) and vocal sounds to show she is happy to see them. Her favourite toy is a glittery stick with tinsel pompoms on each end, red beads and her teddy bear." 2 years, 4 months

Support and Information



Rare Chromosome Disorder Support Group,

GI, The Stables, Station Road West, Oxted, Surrey RH8 9EE, UK

Tel/Fax: +44(0)1883 723356

info@rarechromo.org | www.rarechromo.org

Unique is a charity without government funding, existing entirely on donations and grants. If you are able to support our work in any way, however small, please make a donation via our website at www.rarechromo.org/html/MakingADonation.asp
Please help us to help you!

This leaflet is not a substitute for personal medical advice. Families should consult a medically qualified clinician in all matters relating to genetic diagnosis, management and health. Information on genetic changes is a very fast-moving field and while the information in this guide is believed to be the best available at the time of publication, some facts may later change. Unique does its best to keep abreast of changing information and to review its published guides as needed. It was compiled by Unique and reviewed by Professor Yanick Crow, Professor in Genetic Medicine, Manchester Centre for Genomic Medicine, Manchester, UK.
2014 Version 1 (PM)

Copyright © Unique 2014