



Understanding Chromosome & Gene Disorders

2p15p16.1 microdeletion syndrome



rarechromo.org

2p15p16.1 microdeletion syndrome

A 2p15p16.1 microdeletion is a very rare genetic condition in which a tiny piece is missing from one of the 46 chromosomes – chromosome 2. The tiny missing bit increases the possibility of developmental and speech delay and learning difficulties.

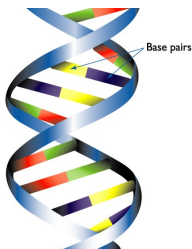
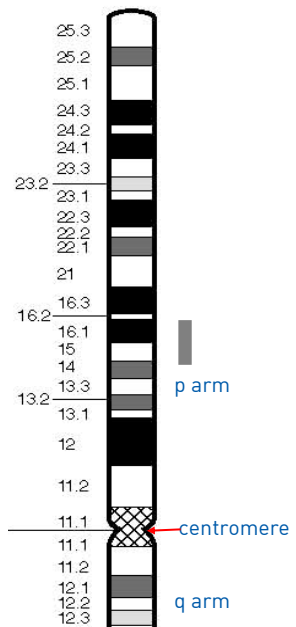
But there is quite a lot of individual variation.

Chromosomes are made up mostly of DNA and are the structures in the nucleus of the body's cells that carry genetic information (known as genes), telling the body how to develop, grow and function. Chromosomes usually come in pairs, one chromosome from each parent. Of these 46 chromosomes, two are a pair of sex chromosomes, XX (a pair of X chromosomes) in females and XY (one X chromosome and one Y chromosome) in males. The remaining 44 chromosomes are grouped in 22 pairs, numbered 1 to 22 approximately from the largest to the smallest. Each chromosome has a short (**p**) arm (shown at the top in the diagram on this page) and a long (**q**) arm (the bottom part of the chromosome). People with a 2p15p16.1 microdeletion have one intact chromosome 2, but the other is missing a tiny piece from the short arm and this can affect their learning and physical development. However, a child's other genes and personality also help to determine future development, needs and achievements.

Looking at chromosome 2p

You can't see chromosomes with a naked eye, but if you stain them and magnify them under a microscope, you can see that each one has a distinctive pattern of light and dark bands. Even if you magnify the chromosomes as much as possible, to about 850 times life size, a chromosome 2 with the microdeletion at p15p16.1 looks normal. People who have missing material on a chromosome are said to have a **deletion** but when the amount is so small that it can't be seen even under a high-powered microscope, it is called a **microdeletion**. The 2p15p16.1 microdeletion can be found using molecular techniques such as multiplex ligation-dependent probe amplification (MLPA) and array comparative genomic hybridisation (array-CGH) or by cytogenetic fluorescent in situ hybridisation (FISH) techniques using fluorescent DNA probes targeted to gene markers within the involved chromosome 2p15p16.1 region. These techniques show whether particular genes are present or not.

It is believed that the effects are caused by the presence of only one copy of these genes instead of two, as expected normally. The 2p15p16.1 region is denoted by the grey bar on the diagram opposite. The size of the microdeletion is variable and reported sizes range from 570 kilobases (kb, one thousand base pairs of DNA) to 5.7 megabases (Mb, one million base pairs of DNA) (Rajcan-Separovic 2007; Chabchoub 2008; de Leeuw 2008; Liang 2009; Felix 2010; Unique).



Two strands of DNA are held together in the shape of a double helix by the bonds between base pairs.

1 base pair = bp
1,000 base pairs = 1kb
1,000,000 base pairs = 1Mb

2p15p16.1 microdeletion syndrome

The first published description of a person with a 2p15p16.1 microdeletion was in 2007. There have since been 12 cases reported in the medical literature worldwide. When a particular set of developmental features occurs in a recognisable and consistent pattern in enough people, as a result of a single cause, the condition is called a syndrome. The features of a 2p15p16.1 microdeletion do occur in this way, so the disorder is often known as **2p15p16.1 microdeletion syndrome**. The deletion seems to occur equally often in males and females.

Sources & references

The information in this guide is drawn from what is known about a very small number of people – just 21, 12 cases to date are included in the literature, aged between two months and 32 years - with a 2p15p16.1 microdeletion. The first-named author and publication date are given to allow you to look for the abstracts or original articles on the internet in PubMed (<http://www.ncbi.nlm.nih.gov/pubmed/>). In addition, this guide draws on information from a survey of members of Unique conducted in 2008, referenced Unique. When this guide was published in April 2013 Unique had nine members with 2p15p16.1 microdeletion syndrome ranging in age from a toddler to two adults.

Chromosome analysis

Your geneticist or genetic counsellor will be able to tell you about the points where the chromosome has broken in your child. With 2p15p16.1 microdeletion syndrome, the results are likely to read something like the following example:

46,XY,arr cgh 2p15p16.1(RP11-479F13-->RP11-260K8)x1 dn

46	The total number of chromosomes in your child's cells
XY	The two sex chromosomes, XY for males; XX for females
.arr cgh	The analysis was by array comparative genomic hybridization (array- CGH)
2	The deletion is from chromosome 2
p15p16.1	The chromosome has one breakpoint in band 2p15 and one breakpoint in band 2p16 and the intervening genetic material is missing
(RP11-479F13-->RP11-260K8)x1	This represents the portion of the chromosome that is only present in one copy (instead of the usual two). The region that is missing is a stretch of DNA between markers RP11-479F13 and RP11-260K8
dn	The deletion occurred de novo (or as a 'new event'). The parents' chromosomes have been checked and no deletion or other chromosome change has been found at 2p15p16.1. The deletion is very unlikely to be inherited and has almost certainly occurred for the first time in this family with this child.

arr[hg19] 2p15p16.1 (59,139,200-62,488,871)x1

arr hg19 The analysis was by array comparative genomic hybridization (array-CGH) Human Genome build 19. This is the reference DNA sequence that the base pair numbers refer to. As more information about the human genome is found, new “builds” of the genome are made and the base pair numbers may be adjusted

2 The deletion is from chromosome 2

p15p16.1 The chromosome has one breakpoint in band 2p15 and one breakpoint in band 2p16 and the intervening genetic material is missing

(59,139,200-62,488,871)x1

The base pairs between 59,139,200 (around 59Mb) and 62,488,871 (around 62Mb) have been shown to be missing (deleted). Take the first long number from the second and you get 3,349,671 (about 3Mb). This is the number of base pairs that are duplicated. x1 means there is one copy of these base pairs, not two as you would normally expect.

One of the cases published in the medical literature has the microdeletion in mosaic form – only a portion of his cells has the microdeletion, the remainder of the cells are normal. However, the boy has features that are extremely similar to the other known cases of 2p15p16.1 deletions and therefore the presence of the normal cells in this case does not seem to have a tempering effect on the features (de Leeuw 2008).

Emerging phenotype: what to expect

When only very small numbers of people have been identified, we can't yet be certain what the full range of possible effects of the deletion are. In the children who are affected, the features that are most striking and most common are:

- Microcephaly (a small head) and specific facial features
- Vision problems - most commonly optic nerve hypoplasia (information is not properly transferred from the eye to the brain) and ptosis (hooded or drooping eyelids)
- Kidney abnormalities
- Minor genital anomalies
- Feeding difficulties
- Growth delay in the womb and/or afterwards
- Children are likely to need significant support with learning. The amount of support needed by each child will vary, although most benefit from supportive services for special needs
- Speech and language delay
- In some, features of autistic spectrum disorder and/or attention deficit disorder

Pregnancy

Most pregnancies were uncomplicated but some babies were small

There is information available on 11 pregnancies of mothers carrying a baby with a 2p15p16.1 microdeletion. Seven had no pregnancy problems and no unusual findings on ultrasound scans. One had polyhydramnios (an unusually high volume of amniotic fluid) and hydronephrosis (enlargement) of the fetal left kidney was seen on an ultrasound scan. Six babies had intrauterine growth retardation (IUGR). This is a term used to

describe babies whose growth in the womb has slowed resulting in babies that are smaller than expected for the number of weeks of pregnancy. Concern about IUGR resulted in four being delivered by caesarean section between 34 and 37 weeks. The mother of one of these babies had an amniocentesis test during pregnancy which failed to detect the 2p15p16.1 microdeletion. Another mother also had an amniocentesis, which revealed a normal karyotype, due to IUGR and hydronephrosis and an abdominal cyst being detected on an ultrasound scan (Rajcan-Separovic 2007; Liang 2009; Felix 2010; Huchtagowder 2012; Piccione 2012; Florisson 2013; Unique).

Feeding and growth

Feeding and growth can be affected in children with 2p15p16.1 microdeletion syndrome

Many babies are born small and light for dates. Of those babies born at term (8/12) for whom birth weights are known the average was 2.87 kilos (6lb 5oz) (Chabchoub 2008, De Leeuw 2008; Liang 2009; Huchtagowder 2012; Piccione 2012; Florisson 2013; Unique).

Range of birth weights (at or near term):

2.02 kilos (4lb 7oz) to 4.1 kilos (9lb 1oz)

Feeding difficulties appear to be common in those with a 2p15p16.1 microdeletion and a number of babies (3/21) are described as “failure to thrive” and eight out of 21 as having feeding difficulties. Some babies had difficulties with sucking and swallowing, and/or latching onto the breast. A number of babies (7/21) are reported to have a high palate which can mean the action of sucking and swallowing is difficult. Two of the babies surveyed by Unique benefited from having a temporary nasogastric tube (NG-tube, passed up the nose and down the throat) and both subsequently had a gastrostomy tube placed (a G-tube, feeding direct into the stomach) which was removed at four years of age. For one of these children had the G-tube was removed at four years of age, the other had a jejunostomy (a J-tube, which is surgically implanted in the upper section of the small intestine called the jejunum which is just below the stomach. The tube is located lower and more towards the centre of the abdomen than a G-Tube) fitted at the age of six and a half. One child had gastro-oesophageal reflux (in which feeds return readily up the food passage). One boy suffered from dysphagia, pain or discomfort when swallowing (Rajcan-Separovic 2007; Chabchoub 2008; de Leeuw 2008; Liang 2009; Felix 2010; Huchtagowder 2012; Florisson 2013; Unique).

In the early days, when feeding is difficult, growth rate may falter but it usually normalises. In time, growth may catch up, but children tend to be short compared with other family members and some are extremely short. By contrast, three children were tall and thin (Rajcan-Separovic 2007; Chabchoub 2008; de Leeuw 2008; Unique). Four out of six children described in the medical literature had postnatal growth retardation (Rajcan-Separovic 2007; Chabchoub 2008; de Leeuw 2008; Liang 2009; Felix 2010).

“No feeding problems at all. He has always been a good/healthy eater. He eats like a horse!” – 4 years

“Eating is one of the biggest problems but is improving, although at 6-years-old she still doesn’t eat any food with texture” – 6 years

Facial features

People with 2p15p16.1 microdeletion syndrome sometimes have facial features in common. They may have a high forehead and a broad, prominent nasal bridge. Their eye openings may be short, widely separated and slant downwards, and they may have hooded or drooping eyelids (ptosis). An everted (protruding) lower lip is also common (Rajcan-Separovic 2007; Chabchoub 2008; de Leeuw 2008; Huchtagowder 2012; Piccione 2012; Florisson 2013; Unique).

Learning

Many children with 2p15p16.1 microdeletion syndrome have a learning disability

Fifteen of those described so far have needed a significant amount of learning support. The boy with the smallest deletion (570kb) is more mildly affected with a mild to moderate learning (intellectual) disability (with an IQ of 50), whereas twelve others are described as having moderate to severe learning problems (IQs below 50). Five of the children known to Unique attend a special educational school. Four are described as having good memories. The attention deficit hyperactivity disorder (ADHD) which seems to be common in those with 2p15p16.1 microdeletion syndrome may mean that children have a short attention span which is likely to add to the challenges of learning (see section on Behaviour page X) (Rajcan-Separovic 2007; Chabchoub 2008; de Leeuw 2008; Liang 2009; Felix 2010; Huchtagowder 2012; Piccione 2012; Florisson 2013; Unique).

“She doesn’t read or write but tries to draw” – 6½ years

“She is very interested in letters and numbers but not reading on her own. She loves books and follows storylines when she is read to. She has no interest in writing or art despite significant and continued exposure. Her strength is music. Music has been integrated into school routines and therapies” – 7 years

“He cannot read or write but is learning to make marks on a page” – 10 years

Speech

Speech and language delay is common in children with 2p15p16.1 microdeletion syndrome

All those with 2p15p16.1 microdeletions described so far have a severe delay in language skills. Five of the individuals described have acquired speech: a 4-year-old has few words; a 6½-year-old girl has some words and uses two or three word sentences together with some signing; a 13-year-old has single words and signs; a 32-year-old man has a few words but his speech is poor and the 16-year-old boy who has the smallest deletion (570 kb) has speech but it is described as being nasal. A 2-year-old smiles and coos but has no language skill; a 3-year-old and a 4-year-old both have no speech. In this situation, a picture exchange communication system (PECS) and/or sign language can help children communicate their needs and speech therapy can be enormously beneficial. Three Unique children all have enough receptive language to follow instructions, but cannot make the sounds of speech. Two use PECS; two use signing to communicate (Rajcan-Separovic 2007; Chabchoub 2008; de Leeuw 2008; Liang 2009; Felix 2010; Huchtagowder 2012; Piccione 2012; Florisson 2013; Unique).

There are many reasons for the speech delay, including the link between the ability to learn and the ability to speak. Those with hearing loss or a high palate may also have specific difficulty with perceiving and producing certain sounds.

“He knows a few signs but not many. He understands everything I say but cannot verbalise back to me” – 4 years

“She has no verbal communication but has been very vocal in the last few years. She can combine three signs at a time” – 7 years

“He communicates by pushing and pulling and using PECS” – 10 years

Motor skills

Children with 2p15p16.1 microdeletion syndrome are often delayed in learning to sit and walk.

Often gross motor skills are affected in those with 2p15p16.1 microdeletion syndrome and this means that it may take a little longer for children to roll over, sit, crawl and walk. From the limited information available, children sat unaided between the ages of 11 months and three and a half years (average 17½ months). Crawling was mastered between 1 year and 4 years.

Walking was mastered by most between two years and six months and five years. Children are often described as having a wide and unsteady gait. One girl has not mastered independent walking at four and a half years but is able to crawl. A 13-year-old has motor delay and is restricted



to several hours of walking but can climb stairs with support. Two of those with a 2p15p16.1 deletion have spasticity (muscular hypertonicity or increased muscle tone) in their lower limbs. This can result in muscles that are continuously contracted causing stiffness or tightness of the muscles and may interfere with gait and movement. One child has low muscle tone (hypotonia). Children may need considerable support while learning to walk (Rajcan-Separovic 2007, de Leeuw 2008, Liang 2009; Felix 2010; Huchtagowder 2012; Piccione 2012; Florisson 2013; Unique).



“Her walking is somewhat slow but good” – 6½ years

“She started to walk on her own at two and a half years but still has issues with stability and tires easily. She needs an adult for safety on stairs. She is a very good swimmer and does not need any flotation aids” – 7 years

“He is unsteady on uneven ground and needs to hold on to railings when going up or down stairs” – 10 years

Fine motor skills and self care

Fine motor skills in children with 2p15p16.1 microdeletions may also be affected and they may take longer to reach for and grab toys and hold a bottle or cup. This can lead to delays in children being able to self-feed and hold a pen to write or draw. Special chunky cutlery, cups with handles and having their food cut up may be necessary.

As a result of these difficulties, children may continue to need help with dressing and undressing. They may also require assistance in tasks such as brushing teeth and washing. Data from Unique suggest that toilet training may also be delayed. A 10-year-old has not yet achieved bladder and bowel control and he needs help with dressing but will lift his arms and legs to help the process. A 4-year-old is still in nappies but is in the process of toilet training; he needs help brushing his teeth and washing but will help his mother in getting himself dressed. A 7-year-old is out of nappies at home and at school, although still need them at night-time and also outside of a structured setting (Unique).

“He does not have a very well developed pincer grip” – 10 years

Medical concerns

■ Head

Microcephaly (a small head) seems to be common affecting at least twelve of the 21 people described so far, and in one child the microcephaly was progressive (a small head that also grows slower than is usual) (Rajcan-Separovic 2007; Chabchoub 2008; de Leeuw 2008; Liang 2009; Felix 2010; Huchtagowder 2012; Piccione 2012; Florisson 2013; Unique).

■ Kidneys

Kidney problems seem to be a common feature in those with 2p15p16.1 microdeletion syndrome. Six of the people described so far had kidney problems. Four had multiple cysts on their kidneys: one had a non-functioning multicystic left kidney; one had cysts on both kidneys and one had cysts only on the right kidney. One boy had hydronephrosis, a condition in which one or both of the kidneys become stretched, or swollen, due to a build-up of pressure when urine fails to drain out of the kidney. Another boy has a partial duplex kidney – part of one kidney is duplicated. Duplex kidneys generally function as normal and no treatment is usually necessary (Rajcan-Separovic 2007; Huchtagowder 2012; Unique).

■ Eyelids and vision

Vision problems are common in those with a 2p15p16.1 microdeletion with five out of ten children affected in some way. The most common problem was optic nerve hypoplasia which is present in five individuals. Optic nerve hypoplasia is a condition present from birth in which the eye does not have all the usual wiring between the eye and brain to transfer information about the visual world. The loss of wiring can sometimes be only very small, but can sometimes be complete with no information being transferred from the eye to the brain at all. One or both eyes can be affected and this can affect vision in different ways. If only a small number of wires in only one eye have failed to grow and the optic nerve is almost normal then the child may also have normal vision. If both optic nerves have almost completely failed to grow properly then the child will have reduced sharpness of vision and may only see bright lights and large shapes. If only a part of the

optic nerve does not grow correctly then only a part of the visual world will be missing with the rest almost normal (Rajcan-Separovic 2007; de Leeuw 2008; Liang 2009; Unique).

A squint (strabismus) is also common, affecting at least eight out of 21 (de Leeuw 2008; Huchtagowder 2012; Piccione 2012; Florisson 2013; Unique).

A number of children have an inability to fully lift the upper eyelid (ptosis). Both eyes are often affected and this is evident at birth and does not develop later. This can cause problems with vision with the eyelid covering the eye and reducing the vision. If necessary the ptosis can be corrected by a surgical procedure (Rajcan-Separovic 2007; de Leeuw 2008; Liang 2009; Felix 2010; Unique).

■ Ears and hearing

Babies and children with a 2p15p16.1 deletion may also have more frequent ear infections than other children. These can sometimes lead to a build-up of fluid in the middle ear, called glue ear. Glue ear usually resolves as children get older and the ear tubes widen and become more vertical resulting in improved drainage of the middle ear. Therefore, any hearing loss caused by glue ear is usually temporary. However, persistent fluid in the middle ear and glue ear can reduce a child's hearing at a time that is critical for speech and language development. Therefore, while glue ear persists, many children will need a grommet (a small ventilation tube) inserted into the eardrum. Two of the children who participated in the Unique survey had temporary grommets. Two boys reported in the medical literature had bilateral (in both ears) sensorineural hearing loss. Sensorineural hearing loss is permanent and is usually treated with hearing aids, or where suitable, cochlear implants (Rajcan-Separovic 2007; Huchtagowder 2012; Piccione 2012; Florisson 2013; Unique).

■ Genital area

Minor anomalies of the genitals are common in babies with chromosome disorders, most often affecting boys. For those with 2p15p16.1 microdeletion syndrome, one boy had cryptorchidism (undescended testes); another had hypoplastic (underdeveloped) genitalia; another boy had one testicle that atrophied and was removed and one boy's penis was attached to his testicles at birth, but detached after circumcision at 16 months. One girl's genitals were hypoplastic (underdeveloped) (Rajcan-Separovic 2007; de Leeuw 2008; Piccione 2012; Unique).

■ Breathing

Two children had a floppy/soft larynx at birth. One case resulted in breathing difficulties and stridor (a high-pitched sound resulting from turbulent air flow in the upper airway) and needed surgery at the age of three weeks. One baby has respiratory issues at birth and continued to have precautionary respiratory medication until the age of three years. Three children suffered from frequent upper respiratory tract infections. One child had severe pneumonia which required intubation at 21 months and an eventual tracheostomy (a surgical procedure where the surgeon creates an opening in the neck at the front of the windpipe (trachea)) (Rajcan-Separovic 2007; de Leeuw 2008; Huchtagowder 2012; Unique).

■ Feet

The feet of babies with 2p15p16.1 microdeletions are often not perfectly formed. Two of those described in the medical literature have metatarsus adductus – the front half of the foot turns inwards. Other problems described are flat feet (in three out of ten cases); the fourth toe joints of two children's feet are bent and one boy has syndactyly of the fourth and fifth toe (the fourth and fifth toes are fused together). Two suffered from tight Achilles tendons. Many children need special, supportive special footwear or surgery and the difficulties often delay the age at which children learn to walk (Rajcan-Separovic 2007; de Leeuw 2008; Florisson 2013; Unique).



■ Hands

Hands can also be affected in children with a 2p15p16.1 microdeletion. Fingers are often long and tapering, sometimes with camptodactyly – one of more fingers that are bent and cannot completely extend or straighten. These hand anomalies can affect the function of the hands and lead to problems with fine motor skills (Rajcan-Separovic 2007; de Leeuw 2008; Felix 2010; Florisson 2013; Unique).

■ Spine

Three out of the ten individuals described suffered from kyphosis (forward curvature of the upper spine). One individual suffered as a child from luxations of the patellae, where the kneecap dislocates or moves out of its normal location, which required surgery (Chabchoub 2008; de Leeuw 2008; Felix 2010; Unique).

■ Palate

A high arched palate was seen in seven of the ten individuals. High palates can contribute to the early feeding difficulties seen in children. A high palate can make latching on and sucking more difficult and a nipple shield or, if bottle-fed, a variable-flow teat can help. Palate anomalies may also make speech and making the sounds of speech more difficult (Chabchoub 2008; de Leeuw 2008; Felix 2010; Unique).

■ Heart

Heart conditions affected only three of those with 2p15p16.1 microdeletions. One boy had a bicuspid aortic valve, a congenital defect in the aortic valve where the valve has only two cusps (flaps) rather than the usual three. The aortic valve ensures that the blood flows only in one direction. When the valve is bicuspid there can be a tendency for the valve to leak. This boy also had a prolapsed mitral valve, a defect in the valve that links the top left chamber of the heart (atrium) to the bottom (ventricle). These anomalies were surgically corrected with good results. Another had pulmonary stenosis, a narrowing of the pulmonary valve, meaning that the heart has to work harder to pump blood which results in breathlessness. Another had a ventricular septal defect (VSD) which is a hole in the wall between the two pumping chambers of the heart, the ventricles (Chabchoub 2008, Piccione 2012Unique).

■ Other concerns

The 32-year-old male has slight gynaecomastia (enlargement of the male breast tissue) (Chabchoub 2008).

Two children have cortical dysplasia (a brain disorder resulting in abnormal early development of neurons in the brain. The abnormal neurons can result in a number of neurological symptoms such as epilepsy. One boy has had a number of recent seizures for which he is now taking medication in order to bring them under control. A second boy had epilepsy which developed at 12 weeks old which was only slightly improved with medication and a ketogenic diet (a high-fat, adequate-protein, low-carbohydrate diet that in medicine is used to treat difficult-to-control epilepsy in children). Another boy had an abnormal electroencephalogram (EEG) indicating risk for seizures, despite the absence of symptoms. Two individuals had abnormal results on brain imaging (MRI) suggestive of abnormal brain maturation (Rajcan-Separovic 2007; Piccione 2012; Florisson 2013; Unique).

Behaviour

Children generally have a pleasant temperament and are often described as happy, loving and affectionate. However, five out of 21 have a diagnosis of an autistic spectrum disorder (ASD) together with attention deficit hyperactivity disorder (ADHD) or attention deficit disorder (ADD). Diagnosis of an ASD consists of a range of problems affecting normal verbal and nonverbal communication skills, poor reciprocal social interaction skills and presence of restricted or unusual interests and stereotypical behaviours, for which specific psychometric testing is warranted for confirmation. ADHD and ADD refer to a range of problem behaviours associated with poor attention span. These may include impulsiveness, restlessness and hyperactivity, as well as inattentiveness, and often prevent children from learning and socialising well. A 4-year-old girl in the medical literature has no autistic traits but has ADD and is described by her parents as being unco-operative. Two of those with ASD and ADHD find interaction with other children difficult and one prefers the company of adults. Children enjoy listening to and playing music, outdoor playgrounds and swimming (Rajcan-Separovic 2007; Chabchoub 2008; de Leeuw 2008; Florisson 2013; Unique).



“He gets bored easily so needs to be stimulated” – 4 years

“She loves playing with books and colouring. She loves everyone and her behaviour is very good” – 6½ years

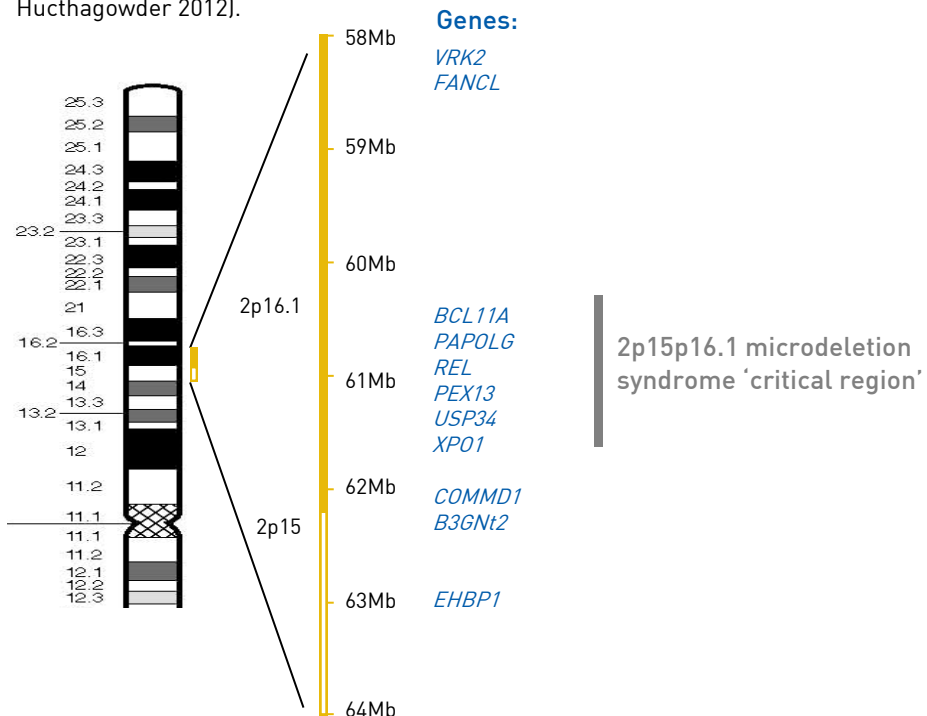
“She is very happy and sociable with adults and even-tempered but has some delays with social interactions with her peers. She displays autistic tendencies but is not considered to have ASD. She does not have ADHD although has attention problems if she is not motivated. She loves school and has a strong personality and likes her independence” – 7 years

“He is hyperactive and has a poor concentration span” – 10 years

Potential genes involved in 2p15p16.1 microdeletion syndrome

A 2p15p16.1 deletion is tiny, so it can only be found using molecular techniques such as MLPA or microarrays (array-CGH) or targeted cytogenetic testing using FISH. These techniques show whether particular genes are present or not. The six people described in the medical literature so far have deletions ranging from 570 kb to 6.9 Mb. Therefore the missing piece is more than 1000 times larger in some people than in others. The common missing piece in the majority of people with 2p15p16.1 microdeletions includes 12 known genes. The boy with the smallest deletion has only five of these known genes missing. It is believed that the effects of 2p15p16.1 microdeletions are caused by the presence of only one copy of these genes instead of two, as expected normally (Chabchoub 2008; de Leeuw 2008; Rajcan-Separovic 2007; Liang 2009; Felix 2010; Huchtagowder 2012; Piccione 2012; Florisson 2013).

Determining the exact size of the deletion is necessary for identifying critical regions and genes that may contribute to the features of 2p15p16.1 microdeletions. Indeed with the breakpoints for the published cases known it is possible to attempt to correlate the clinical features in people with 2p15p16.1 microdeletions with the part of the chromosome they have missing in order to have to narrow down the genes responsible. Indeed, a recent paper has narrowed down the region responsible ('critical region') for the features of 2p15p16.1 microdeletion syndrome (see diagram below) (Liang 2009; Huchtagowder 2012).



The numbers in this diagram refer to the human genome build 19 (hg19; see page 4 for more details). Your child's report may refer to a different human genome build. Please contact Unique or your genetic specialist for any help with understanding the report.

As all published cases share the facial features and learning difficulties, it is likely that the genes that are responsible for these features are located in a region which is deleted in all four cases (see diagram on page 12). However, the boy with the smallest deletion lacks microcephaly, the optic nerve hypoplasia and ASD, so these features are likely to be due to the loss of genes outside of his deletion. The *VRK2* gene located here has been proposed as a candidate for this group of neurological features (Chabchoub 2008; Felix 2010).

It is important to remember that while identifying the gene(s) responsible for certain features of 2p15p16.1 microdeletion syndrome is interesting and may help guide future studies, it does not lead directly to immediate improved treatment. Additionally, even if the supposedly responsible gene is deleted it does not always mean that the associated feature(s) will be present. Other genetic and environmental factors often have a role in determining the presence or absence of a particular feature.

How did this happen?

2p15p16.1 microdeletions usually occur out of the blue for no obvious reason.

The genetic term for this is *de novo* (dn) and at first sight, both parents have normal chromosomes. All the same, it is important to check the parents' chromosomes to rule out any predisposing rearrangement within one of their chromosome 2s using either MLPA, array-CGH or targeted FISH testing methods.

What is certain is that as a parent there is nothing you could have done to prevent this from happening. No environmental, dietary or lifestyle factors are known to cause 2p15p16.1 microdeletions. There is nothing that either parent did before or during pregnancy that caused the microdeletion.

Can it happen again?

Where both parents have normal chromosomes, it is unlikely that another child will be born with a 2p15p16.1 microdeletion or any other chromosome disorder. Very rarely (less than 1%), both parents have normal chromosomes by a blood test, but a few of their egg or sperm cells carry the 2p15p16.1 microdeletion. This is called [germline mosaicism](#) and it means that parents whose chromosomes appear normal when their blood is tested can have more than one child with the deletion.

In families where the 2p15p16.1 microdeletion has been inherited from a parent, the possibility of having another child - either a girl or a boy - with the 2p15p16.1 microdeletion rises to 50% in each pregnancy. However, the effect of the microdeletion on the child's development, health and behaviour cannot be reliably predicted.

Your genetics centre should be able to offer counselling before you have another pregnancy.

References

Chabchoub E, Vermeesch JR, de Ravel T, de Cock P, Fryns JP.

The facial dysmorphism in the newly recognised microdeletion 2p15-p16.1 refined to a 570 kb region in 2p15.

J Med Genet. 2008 Mar;45(3):189-92. PMID: 18310269

de Leeuw N, Pfundt R, Koolen DA, Neefs I, Scheltinga I, Mieloo H, Sistermans EA, Nillesen W, Smeets DF, de Vries BB, Knoers NV.

A newly recognised microdeletion syndrome involving 2p15p16.1: narrowing down the critical region by adding another patient detected by genome wide tiling path array comparative genomic hybridisation analysis.

J Med Genet. 2008 Feb;45(2):121-4. PMID: 18245392

Félix TM, Petrin AL, Sanseverino MT, Murray JC.

Further characterization of microdeletion syndrome involving 2p15-p16.1.

Am J Med Genet A. 2010 Oct;152A(10):2604-8. PMID: 20799320

Florisson JM, Mathijssen IM, Dumeé B, Hoogeboom JA, Poddighe PJ, Oostra BA, Frijns JP, Koster L, de Klein A, Eussen B, de Vries BB, Swagemakers S, van der Spek PJ, Verkerk AJ.

Complex craniosynostosis is associated with the 2p15p16.1 microdeletion syndrome.

Am J Med Genet A. 2013 Feb;161A(2):244-53. doi: 10.1002/ajmg.a.35632. Epub 2013 Jan 9. PMID:23303641

Huchtagowder V, Liu TC, Paciorkowski AR, Thio LL, Keller MS, Anderson CD, Herman T, Dehner LP, Grange DK, Kulkarni S.

Chromosome 2p15p16.1 microdeletion syndrome: 2.5 Mb deletion in a patient with renal anomalies, intractable seizures and a choledochal cyst.

Eur J Med Genet. 2012 Aug-Sep;55(8-9):485-9. doi: 10.1016/j.ejmg.2012.04.003. Epub 2012 Apr 21. PMID: 21579565

Liang JS, Shimojima K, Ohno K, Sugiura C, Une Y, Ohno K, Yamamoto T.

A newly recognised microdeletion syndrome of 2p15-16.1 manifesting moderate developmental delay, autistic behaviour, short stature, microcephaly, and dysmorphic features: a new patient with 3.2 Mb deletion.

J Med Genet. 2009 Sep;46(9):645-7. No abstract available. PMID: 19724011

Piccione M, Piro E, Serraino F, Cavani S, Ciccone R, Malacarne M, Pierluigi M, Vitaloni M, Zuffardi O, Corsello G.

Interstitial deletion of chromosome 2p15-16.1: report of two patients and critical review of current genotype-phenotype correlation.

Eur J Med Genet. 2012 Apr;55(4):238-44. doi: 10.1016/j.ejmg.2012.01.014. Epub 2012 Feb 18. PMID: 2140640

Rajcan-Separovic E, Harvard C, Liu X, McGillivray B, Hall JG, Qiao Y, Hurlburt J, Hildebrand J, Mickelson EC, Holden JJ, Lewis ME.

Clinical and molecular cytogenetic characterisation of a newly recognised microdeletion syndrome involving 2p15-16.1.

J Med Genet. 2007 Apr;44(4):269-76. PMID: 16963482

Notes

Support and Information



Understanding Chromosome & Gene Disorders

Rare Chromosome Disorder Support Group,

The Stables, Station Rd West, Oxted, Surrey. RH8 9EE. England.

Tel: +44(0)1883 723356

info@rarechromo.org | www.rarechromo.org

Join Unique for family links, information and support.

Unique is a charity without government funding, existing entirely on donations and grants. If you can please make a donation via our website at www.rarechromo.org/donate

Please help us to help you!

This leaflet is not a substitute for personal medical advice. Families should consult a medically qualified clinician in all matters relating to genetic diagnosis, management and health. The information is believed to be the best available at the time of publication. It was compiled by *Unique* and reviewed by Dr Suzanne Lewis, University of British Columbia, Vancouver, Canada and by Professor Maj Hulten University of Warwick, UK

2008 Version 1 (SW)

2011 Version 2 .0 (SW)

2013 Version 2.1 (SW)

Copyright © Unique 2018