
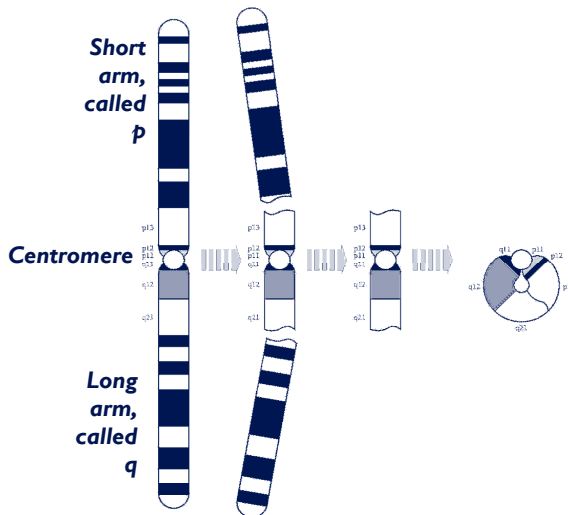


Supernumerary ring chromosome 1



Supernumerary ring chromosome I

A supernumerary ring chromosome I (SRCI) means that there is a tiny extra part of a chromosome in all or some of the cells of the body. In addition to the 46 chromosomes that everyone has, people with supernumerary ring chromosome I have a small extra chromosome made from chromosome I material.



The extra chromosome usually consists of a small piece that has broken off near the middle of the chromosome and the 'sticky' ends have curled up to join and form a ring.

No-one knows yet just how rings form, but the picture on the left shows one possibility.

Genes and chromosomes

Our bodies are made up of billions of cells. Most of the cells contain a complete set of tens of thousands of genes which act like a set of instructions, controlling our growth and development and how our bodies work.

Genes are carried on microscopically small, thread-like structures called chromosomes. There are usually 46 chromosomes, 23 inherited from our mother and 23 inherited from our father, so we have two sets of 23 chromosomes in 'pairs'. Apart from two sex chromosomes (two Xs for a girl and an X and a Y for a boy) the chromosomes are numbered 1 to 22, generally from largest to smallest.

Chromosome I

Chromosome I is one the largest chromosomes in man and contains more than 2100 genes out of the total of 20,000 to 25,000 genes in the human genome. That is about twice as many as an average-sized chromosome. But the ring chromosome usually only contains a few of these genes.

People with ring chromosome I usually have some cells with 46 chromosomes and others with 47 chromosomes (46 plus the ring). When cells with a different chromosome make-up exist alongside each other, the condition is known as **mosaic**. Different proportions of normal cells and cells with the ring chromosome are usually found in different body tissues, such as blood, skin, scrapings from inside the cheek or, prenatally, in amniotic fluid or cells from the developing placenta (chorionic villus sample). The number of cells with the ring chromosome usually falls over time, especially in blood.

You can't see chromosomes with the naked eye, but if you stain them and magnify them under a microscope, you can see that each one has a distinctive pattern of light and dark bands. The diagram on page 2 shows the bands of a normal chromosome 1. These bands are numbered outwards starting from the point where the short and long arms meet (the **centromere**). A number starting with a 'p' is in the short arm (at the top in the diagram) and a number starting with 'q' is in the long arm (at the bottom).

Some bands contain no important genes and only inactive genetic material (called **heterochromatin**). There is a band of heterochromatin close to the centromere in the long arm of chromosome 1 (1q12) and having extra material from this band should not affect development. All the other bands contain more or less active genetic material (called **euchromatin**). So the bands on both sides of inactive material at 1q12 contain euchromatin. Having extra euchromatin is more likely to affect development.

Your geneticist or genetic counsellor will tell you more about what chromosome material your child's ring consists of. You will almost certainly be given a **karyotype**, a shorthand code for the image of your child's chromosomes that will usually state in square brackets the numbers of normal cells and ring cells. It may also show the points where the chromosome has broken and rejoined. A karyotype for a boy with supernumerary ring 1 might look like this:

mos47,XY,+r(1)(p13q21.3)[28]/46,XY[22]

This means that of 50 cells tested, 22 had the usual number of 46 chromosomes, while 28 had an additional ring chromosome 1 consisting of material between p13 in the short arm, the centromere and q21.3 in the long arm.

Comparing your child's karyotype with others, both from the medical literature and within *Unique*, can help to build up a general picture of what to expect. But there will still be differences, sometimes quite marked, between your child and others with apparently similar ring chromosomes. It is very important to see your child as an individual and not to make direct comparisons with others with the same karyotype. After all, each of us is unique.

Sources & references

The information in this leaflet is drawn partly from published medical research, with reports on more than 30 cases. The first-named author and publication date are given to allow you to look for the abstracts or original articles on the internet in PubMed. If you wish, you can obtain abstracts and articles from *Unique*.

The leaflet also draws on *Unique's* database. When this leaflet was written, *Unique* had eight members with a supernumerary ring chromosome 1.

(Bernardini 2007; Barbi 2005; Rodriguez 2005; Tönnies 2003a and b; Anderlid 2001; Dawson 2001; Finelli 2001; Röthlisberger 2001; Callen 1999; Giardino 1999; Shanske 1999; Crolla 1998; Levy 1998, 5; Xu 1998; Chen 1995; Lanphear 1995; Michalski 1993; Plattner 1993; Ramirez-Duenas 1992; Callen 1991; *Unique*)

In addition, up-to-date information on SRCIs is to be found on the following website: <http://www.med.uni-jena.de/fish/sSMC/01.htm>. It is a little technical, and if you have difficulty with any of the information there, please contact us at info@rarechromo.org.

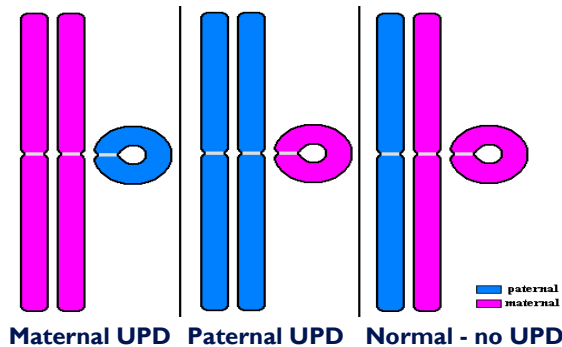
Diagnosis

The ring is usually so tiny that it cannot be identified accurately under a microscope. It may be so tiny that it is even hard to know which chromosome it came from. The origin and amount of extra material can usually only be identified using a combination of different techniques, including FISH (using specific DNA probes or the microdissected chromosome itself that show up in fluorescent colour) or microarrays (a tool for analysing thousands of different DNA sequences at the same time) (Bernardini 2007).

Uniparental disomy

There is one further consideration, called uniparental disomy (UPD). Usually one chromosome 1 in each pair comes from the mother and one from the father.

UPD means that both the complete chromosomes have come from the same parent and the supernumerary ring chromosome 1 has come from the other parent. UPD is found in 5-10 per cent of people with a small marker chromosome such as a supernumerary ring 1 and recently two cases out of eight with a supernumerary ring chromosome 1 tested positive for UPD 1. It is important because it may cause additional effects.



Uniparental disomy in connection with supernumerary ring chromosome 1

Features

The effects of the ring chromosome depend mostly on:

- Whether the ring contains active or inactive material
- How much material the ring contains
- The percentage of ring cells in different body tissues. Generally, tissues with more normal cells develop more normally. But the percentage of ring cells in blood is not necessarily representative of the rest of the body
- Effects may also depend partly on an interaction between material in the short and the long arms

(Bernardini 2007; Rodriguez 2005; Tönnies 2003a; Röthlisberger 2001; Crolla 1998).

Rings containing only inactive material from the long arm or only material from around the centromere

These rings are probably harmless and do not affect development. As it is important to be as precise as possible about the breakpoint in each arm of the chromosome, some of the tests described in the section on [Diagnosis](#) will probably be carried out if there is any doubt about the size of the ring. The chief effect of these otherwise harmless rings is that they may affect fertility (Bernardini 2007; Crolla 1998; Michalski 1993; Plattner 1993).

Other rings

To discover about the possible effects of other rings, the best way is to contact info@rarechromo.org and ask for help in selecting relevant cases from the website at <http://www.med.uni-jena.de/fish/sSMC/01.htm>. You can then take a list of these cases to your genetic specialist.

Another way is to read the relevant section below. The information that follows was correct when this leaflet was written in early 2007, but the picture can change quickly as new babies and children are diagnosed and reported in the medical literature.

Rings containing active material from the long arm

Of the five cases reported in the medical literature, each has a different breakpoint in the long arm or has an unusual ring formation, such as a double ring. This means that we cannot be certain what the effects are (Barbi 2005: q10q21.3; Tönnies 2003b: q10q21.1; Finelli 2001: q10q22; Giardino 1999: p11q21; Ramirez-Duenas 1992: p11q22).

The **development** of all the children was affected: one baby was a month behind in reaching her milestones at nine months and by the age of five years was performing at the level of a four-year-old in terms of mobility and using her hands (Barbi 2005). Another child was sitting by 12 months (Tönnies 2003b) and another walking by 30 months (Ramirez-Duenas 1992). Two of these children were diagnosed with muscular hypotonia. This is a low muscle tone, making a baby or child feel floppy to hold. Early intervention with physiotherapy can improve eventual mobility considerably (Tönnies 2003).

In terms of **communication** and **learning ability**, two children were not speaking at the ages of 3 and 15 (Tönnies 2003b; Finelli 2001), while another was talking in full sentences by the age of five (Barbi 2005). One child had difficulties with concentration and another had problems interacting socially with others at the age of three but was problem-free by seven (Barbi 2005; Tönnies 2003b).

As for **growth**, babies were born a normal weight and length and while in most cases, growth after birth was slow and height rather short, one child was tall for her age at 3 years (Ramirez-Duenas 1992).

Unusual features that might be noticed at birth included a single palm crease across the hand in one child and short hands and feet, with incurving fifth fingers in another (Barbi 2005; Ramirez-Duenas 1992). A dimple at the base of the spine was found in two babies. A **sacral dimple** (dimple or hole in the skin just above the crease between the buttocks) may be shallow so you can see the base, but stools can collect there before your child is toilet trained, so keeping it clean and protected is important (Barbi 2005; Finelli 2001).

One boy was also born with **hypospadias** and **undescended testicles**. In hypospadias, the opening usually at the end of the penis is situated on the underside. If necessary, it can be

corrected in a one- or two-stage surgical operation in early childhood. Treatment for undescended testicles depends on the suspected cause but whatever the cause, treatment is usually needed if the testicles do not descend naturally in time. If a hormone problem is suspected, a short course of hormone treatment may be suggested. Otherwise, or if hormone treatment does not work, the testicles can be brought down in a short operation under general anaesthetic called an orchidopexy (Giardino 1999). This child also had club feet (**talipes**). This can usually be corrected by stretching, splinting, casting and/ or surgery.

Three of the children appear to have enjoyed generally good health. The other two had significant illness.

One boy had repeated respiratory infections in his first year of life and quite severe breathing difficulties and a marked forward spinal curvature (kyphoscoliosis) by 13 years. He was also born with a heart condition, an enlarged heart and a **ventricular septal defect**, a hole in the wall between the two pumping chambers of the heart (ventricles). This allows blood to flow from the left to the right chamber, increasing the blood flow to the lungs, but in his case the hole closed spontaneously. On imaging, the ventricles of his brain were enlarged. He was also found to have early **cataracts**, which have been seen in another child with a ring chromosome 1 involving duplication of the *GJA8* gene that is found in band 1q21.1. This gene encodes Cx50, a protein that is important for the formation of the lens in the eye. Although so far there are only two children reported with a duplication of this region and cataract formation, children with a ring chromosome 1 that includes this region can usually expect to have detailed ophthalmological follow-up (Rodriguez 2005; Finelli 2001; Chen 1995).

The other child with significant health problems developed an intestinal blockage due to **volvulus**. This can occur as a result of intestinal malrotation, a developmental anomaly of the digestive tract that can lead to intestinal blockage. The intestine becomes twisted and the twisting can cut off blood flow to the intestine and damage it. Treatment is determined on an individual basis but a volvulus is usually repaired as soon as possible by surgery. This child died shortly before his second birthday after developing an overwhelming inflammation of the pancreas (Giardino 1999).

The 1q21.1 band contains a gene known as *BCL9* which may be related to a form of leukaemia. Although no cases of leukaemia has been seen in people with a 1q21.1 duplication, it has been recommended that they are monitored (Rodriguez 2005).

Rings containing genetically active material from the short arm

Of the ten cases reported in the medical literature, each has a different breakpoint in the short arm or the breakpoint has not been precisely characterised. This means that we are less certain what the effects are (Bernardini 2007; Tönnies 2003: q10p13.3; Anderlid 2001: p10p13; Röthlisberger 2001: p21.1q12; Callen 1999, A, B, C; Giardino 1999/2: p11~12q21.1~21.3; Plattner 1993a).

Apart from a report of a mother discovered by chance during prenatal testing, who had inherited the ring from her mother and who developed normally (Bernardini 2007), the **development** of all the children was affected, suggesting that all children will need support with their learning and development. The developmental areas and extent of the delay varied considerably, however, and there was no clear link between the size of the ring 1 and the extent of the developmental delay. One boy, last described at 16

years, had the cognitive abilities of a five-year-old at the age of four but had a specific language delay. A specific language delay was described in a 2-year-old boy (Callen 1999, C; Giardino 1999, 2) and a 13-year-old girl was not yet speaking (Anderlid 2001). A boy with a ring I including a similar amount of material to the boy with no apparent learning difficulty had a moderate learning disability at 12 years and an IQ estimated at 46-50 (Callen, 1999, A). A boy with a larger ring I, described at 15 years, had a mild learning disability, with an IQ estimated at 67-77 (Callen, 1999, B). Other children were reported to have a more marked learning disability (Tönnies 2003; Anderlid 2001).

Children's **behaviour** is rarely described, but two children had a high level of activity and difficulties with concentration and one had symptoms of autism while another had diminished social interactions (Tönnies 2003; Anderlid 2001; Giardino 1999, 2).

In terms of **mobility**, the reports in the medical literature are incomplete but one boy was walking at the age of three years. He was reported to have muscular hypotonia and extremely flexible joints. As for **growth**, babies were generally born a normal weight and length at birth after a normal, term pregnancy and delivery. Growth rates were normal although one 15-year-old boy was considerably taller than the rest of his family and both he and a 16-year-old boy were described as having a lean build and in one case a gaunt appearance. In most children the head was small relative to body size but still within normal limits, although two children had a very small head (microcephaly) (Tönnies 2003; Röthlisberger 2001; Callen 1999, B & C).

Unusual features that might be noticed at birth were generally trivial, including features such as wide set or inverted nipples and incurving or bent fingers, particularly the fifth finger. One boy was born with a club foot (**talipes equinovarus**), in which the foot is usually short and broad and the heel points downward while the front half of the foot turns inwards. Treatment is individually tailored and aims to straighten the foot so that it can grow and develop normally. First-line treatment is non-surgical and may include manipulation, casting, taping, physiotherapy and splinting, followed by bracing to prevent relapse. Surgery and sometimes splinting are considered if non-surgical treatments are not completely successful. The foot position may relapse as the child grows and develops, making further surgery necessary.

A girl had developmental **hip dysplasia**. Treatment is tailored to the individual child but can include wearing a harness, stretching, surgery and casting (Röthlisberger 2001).

In a number of children, slightly unusual facial features were noted, such as unusually shaped ears, skin folds across the inner corners of the eyes and an unusual slant to the eyes. However, there was no specific pattern to these unusual features, although they may mean that a child will look somewhat different to the rest of their family.

All the children appear to have enjoyed generally **good health**. Two children had repeated ear, nose and throat infections, common in young children, and had grommets (tubes) inserted to improve the action of the ear drum but there was no evidence of lasting hearing impairment.

The only significant ill health reported was chronic diarrhoea with fatty stools in one child and the development of a forward spinal curvature in the upper back area leading to a humped appearance (**kyphosis**, kyphoscoliosis) in two teenagers. Treatment for kyphosis is tailored to the individual child and may include observation, bracing and possibly surgery (Callen 1999, B & C).

Rings containing genetically active material from both arms

Of the fourteen cases reported, 10 in the medical literature and four from *Unique*, including an adult of 23 years, breakpoints in both arms are often different or in some cases not precisely defined. The breakpoints in the *Unique* group were generally at p13 and q21 (Rodriguez 2005/1, 2, 3: p11.1q21.1; Dawson 2001; Callen 1999/D; Shanske 1999, 1 & 2; Xu 1998: p13q21.3; Chen 1995: p13q23; Lanphear 1995; *Unique*).

There was a very broad range of outcomes in **development**, suggesting that while some children will need support with their learning and development, others might develop normally. Two young children were developing normally at eight months and two years, while two other children were showing only a mild degree of delay at 15 months and 10 years. Among *Unique* members, a mild to moderate degree of developmental delay was observed, with walking between 17 and 19 months, although in one case this was not achieved until 6 years. No abnormalities of muscle tone were noted and after early childhood, mobility was normal (Rodriguez 2005/3; Dawson 2001; Callen 1999/D; Lanphear 1995; *Unique*). Among other children, more support and intervention could be needed as they showed a more marked degree of delay in reaching their early developmental milestones.

In terms of **learning**, the degree of delay was between slight and severe. One child from *Unique* was supported in school with a statement of educational need and was able to write and read by the age of five. By the late teen years, he was able to read and write perfectly and was taught separately in a mainstream school. The area where he showed greatest ability was in music. A younger child was not yet reading or writing at 6 years and was progressing in the preparatory stages of access to the national learning curriculum. She showed difficulties with attention and was judged to be a more able visual than aural learner, although she enjoyed music and learned songs in different languages with ease.



Six years old

As for **speech and language**, a range of outcomes is possible: first words and linked phrases may be late to emerge but at least one *Unique* member has normal speech development. When this is not so, with speech therapy communication is possible through signing, gestures, vocal tone, single words and in some cases phrases and limited conversation (Chen 1995; Lanphear 1995; *Unique*).

Some effect on **behaviour** can be expected but there is no typical pattern, with single reports of concentration difficulties, obsessive

compulsive behaviours, anxiety and lack of social interaction balanced by a report of a placid, happy, 'very loving and cute' child (Chen 1995; Lanphear 1995; *Unique*).

There is a wide range of outcomes in terms of **mobility**, with evidence of some babies sitting by six months and walking, at first with support, from as early as 17 months. In one case the crawling stage emerged late. While *Unique*'s experience is that mobility can eventually be normal, walking is not possible for all and one 15-year-old used a wheelchair indoors and out.

Underlying the difficulties with mobility in some children is abnormal muscle tone, making the muscles either unusually floppy (hypotonia) or tense (hypertonia). Children will benefit from early intervention with physiotherapy.

As for **growth**, there is great variability, with some babies showing slow growth before birth and being born small-for-dates while others are born a normal weight and length. Postnatal growth also varies; height in childhood may be normal or short. However, there are no reports of children being unusually tall. Body build also varies from wiry to chubby (Rodriguez 2005/1; Dawson 2001; Chen 1995; *Unique*).

Unusual features that might be noticed at birth in some babies include a disproportionately small head or an unusually shaped head. Slightly unusual **facial features** may also be noticed, such as widely spaced eyes, skin folds across the inner eye corner, unusually large or small ears, thin lips and an unusually large or small tongue. In at least one child the facial features were so subtle that they were not noticed in babyhood but became slightly more obvious by middle childhood. There does not appear to be a recognisable pattern to these features, but they may mean that a baby or child with supernumerary ring 1 looks different to other family members. Occasionally the hands or feet may have unusual features, such as an incurving finger or toe, small, underdeveloped nails or, in one case a bifid thumb, where the tip of the thumb is duplicated (Shanske 1999). One boy was born with an unusually small penis (micropenis). Any treatment for micropenis is decided for your son as an individual and hormone therapy may be discussed to stimulate growth as appropriate. Another boy had surgery for an undescended testicle (Rodriguez 2005/2; *Unique*).

Some babies have had **feeding** problems and in a few cases these can be lasting. *Unique's* experience has been that breastfeeding has not been successful but that babies have fed more successfully on formula. Some babies have difficulties swallowing or coordinating the actions of breathing and swallowing at birth. One *Unique* baby had a gastrostomy tube inserted direct to the stomach to help with feeding but was able to take some food by mouth.

In terms of **general health**, respiratory and ear infections are common in all young children, including those with a chromosome disorder who may well be more severely affected and take longer to recover their good health after the illness. More serious ill health has only affected individual children, and there is no suggestion of a recognisable pattern of ill health associated with the ring 1 chromosome. In *Unique's* experience, children generally enjoy good health and have not experienced long term problems with hearing or eyesight.

One baby was born with a **diaphragmatic hernia**, a hole in the muscular wall separating the heart and lungs from the contents of the abdomen. Part of the bowel, stomach or liver take up space in the chest, potentially depriving the lungs and heart of room to develop properly. The diaphragm develops from four separate structures that normally fuse by the 8th week of fetal life; the hernia results from a failure of one of these to fuse. Once a baby's condition has been stabilised, the hernia will be repaired and support given for breathing for as long as the baby needs it.

Two babies were born with a hole between the lower **heart** chambers, known as a ventricular septal defect (VSD). While small holes of this type may close naturally as a child grows, a larger VSD usually needs surgical repair.

Three children have experienced **seizures**, in one instance an isolated case, but in the others as far as is known they are reasonably controlled with medication. One child had an **inguinal hernia**, where part of the bowel loops through an opening in the inguinal canal. The hernia typically appears as a swelling in the groin and usually needs repair.

Among other concerns, one baby was born with an angioma (a benign tumour in the skin made up of blood or lymph vessels) in the back; another had two fused ribs; one had hemivertebrae, incomplete development of one side of the vertebra, resulting in a wedge shape, which can cause scoliosis, a spinal curvature.

One boy was born with glaucoma, raised pressure within the fluid part of the eye, which was surgically corrected. He developed a **cataract** in the right eye at the age of three (Chen 1995).

Rings of unknown extent



Four years old

Three *Unique* children have a ring chromosome made up of material from chromosome 1 but with no specification of breakpoints, leaving it uncertain what material they contain.

In terms of **development**, all have shown some degree of delay. One child was reading and writing by the age of 5 years, one had a severe learning disability, one was still too young for certainty but showed enjoyment in music, a fair memory and an ability to work hard and attended an inclusive pre-school. In terms of **speech and language**, first words emerged in two children around the first birthday but in one case speech was not clear and progress to linked words and phrases followed slowly, so that by the age of four, most utterances were in 2-3-word phrases.

In terms of **behaviour**, one child was reported to have autistic traits and obsessive behaviours with

aggressive behaviours emerging by pre-adolescence; one child was reported to be hyperactive but happy; and one was reported at the age of four as 'very loving and affectionate'. He showed some behaviours more typical of a younger child, such as mouthing non-food objects and was easily frustrated.

In terms of **mobility**, these children first sat up between eight and 20 months and took their first steps between 11 and 20 months. One child had very flat feet and wore ankle-foot orthoses (supports); another had tendencies typical of cerebral palsy. In terms of **growth**, information was available on only one child, whose height at 4 years was average while he was underweight for his age.

Facial features have only been described in one child who had a prominent somewhat bulbous nose and a small chin and low set ears with an overfold at the top. His head shape was unusual and the back of the head was flat.

There is information on **feeding** in one child only. He was not able to latch on to breast feed and had difficulties sucking from a bottle. As a young child he had a tendency to overfill his mouth and not to chew properly.

In terms of **general health**, two children had **seizures**, but in one they resolved by age 2. One baby was born with a narrow aorta (the main blood vessel leading from the heart to supply the body) but this resolved naturally. Other health concerns reported in this child include asthma; frequent fractures (bones of the forearm twice after falling; collar bone at birth); and wedging of the bones of the spinal column, requiring monitoring. Overall, his health was reported to be good.

How did the ring chromosome happen?

Most ring chromosomes occur when both parents have normal chromosomes. Geneticists call this **de novo (dn)**. These rings are caused by a change that occurred when the parents' sperm or egg cells were formed. We know that chromosomes must break and rejoin when egg and sperm cells are formed but this only occasionally leads to problems. The breaking and rejoining that caused the ring to form during egg or sperm production is part of a natural process and as a parent you cannot change or control it.

Some supernumerary ring chromosomes are inherited. The mother or the father has the same ring chromosome.

A blood test to check the parents' chromosomes will show if the ring is inherited or not.

Children from all parts of the world and from all types of background have supernumerary rings. No environmental, dietary or lifestyle factors are known to cause them. There is nothing that either parent did before or during pregnancy that can be shown to have caused the ring to occur and equally nothing could have been done to prevent it.

Most people with a ring chromosome 1 have **mosaicism**. Some cells have the normal make-up of 46 chromosomes and others have the extra ring chromosome. When cells divide during development, there is a tendency for the cells with the ring chromosome to be dropped and this leads to mosaicism.

Can it happen again?

When the parents' chromosomes are examined they are usually found to be normal. Where both parents have normal chromosomes, it is very unlikely that another child will be born with a supernumerary ring 1 and this is never known to have occurred. Where one parent themselves has supernumerary ring chromosome 1, the chance of passing it on is less than 50:50 in each pregnancy, although women are twice as likely to pass it on as men. When the ring is passed on, the proportion of normal to ring chromosome cells will be different in the baby and this can change the effects on the baby (Bernardini 2007).

Can my child with a supernumerary ring chromosome 1 have similarly affected children?

Adults with a supernumerary ring chromosome 1 may form close relationships and want to have children. Fertility is often affected but some people will have children. In each pregnancy, someone with the extra ring chromosome can pass it on and women are twice as likely to do so as men. How well they can look after a child is likely to be closely related to their own degree of learning difficulty, if any.

Support and Information



Rare Chromosome Disorder Support Group,

G1, The Stables, Station Road West, Oxted, Surrey RH8 9EE, United Kingdom

Tel/Fax: +44(0)1883 723356

info@rarechromo.org | www.rarechromo.org

Join Unique for family links, information and support.

Unique is a charity without government funding, existing entirely on donations and grants. If you can, please make a donation via our website at www.rarechromo.org Please help us to help you!

This information guide is not a substitute for personal medical advice. Families should consult a medically qualified clinician in all matters relating to genetic diagnosis, management and health. Information on genetic changes is a very fast-moving field and while the information in this guide is believed to be the best available at the time of publication, some facts may later change. Unique does its best to keep abreast of changing information and to review its published guides as needed. It was compiled by Unique and reviewed by Privatdozent Dr Thomas Liehr, Institut für Humangenetik und Anthropologie, University of Jena, Germany; Dr Holger Tönnies, Institute of Human Genetics, Charité, Berlin, Germany; Dr Laura Rodriguez, Centro de Investigacion sobre Anomalías Congénitas (CIAC), Madrid, Spain and by Professor Maj Hulten BSc, PhD, MD, FRCPath, Professor of Medical Genetics, University of Warwick, UK. 2007. (PM)

Copyright © Unique 2007

Rare Chromosome Disorder Support Group Charity Number 1110661

Registered in England and Wales Company Number 5460413